

RARE NON-SURGICAL RELATED MASSIVE SPONTANEOUS SUPRACHOROIDAL HEMORRHAGE. A CASE REPORT

Hasan NA.^{1,2}, Musa M.¹, Ali HM.¹, Mustapha M.², Halim WH.²

¹Department of Ophthalmology, Hospital Sultanah Bahiyah, Malaysia

²Department of Ophthalmology, Faculty of Medicine, University Kebangsaan Malaysia Medical Center, Malaysia

The authors declare no conflict of interest. The authors are responsible for the content and writing of the paper.

Received: May 17, 2023

Accepted: June 6, 2023



Dr. Nur Atiqah Hasan
Department of Ophthalmology,
University Kebangsaan Malaysia
Medical Centre Cheras
56000 Kuala Lumpur
Malaysia
E-mail: syikk_1201@yahoo.com

SUMMARY

Aims: We present two rare cases of non-surgical-related massive spontaneous suprachoroidal hemorrhage.

Case report: The first case was a 73-year-old male with uncontrolled hypertension, who presented with left vision loss, only able to perceive light, with very high intraocular pressure (IOP) and blood pressure (BP), 68 mmHg and 196/106 mmHg, respectively. Ocular examination showed a limited fundus view, and the B-scan revealed near kissing suprachoroidal hemorrhage.

The second case was a 59-year-old male, post valve replacement surgery on life-long warfarin, who presented with hand movement vision and IOP of 47 mmHg. The B-scan showed massive submacular and suprachoroidal hemorrhage with therapeutic range International Normalized Ratio (INR).

Conclusion: Suprachoroidal hemorrhage is one of the rare complications that can be seen in any ocular surgery. However, spontaneous suprachoroidal hemorrhage is a rarer disease. Most of the reported cases are associated with underlying medical conditions. Thus prevention is crucial. This involves ophthalmologists, physicians and general practitioners in managing this group of patients with associated risk factors, for better recognition of this devastating ocular complication in which early detection may reduce ocular morbidity.

Key words: spontaneous suprachoroidal hemorrhage, INR, hypertension, intraocular pressure

Čes. a slov. Oftal., 79, 2023, No. 4, p. 202–204

INTRODUCTION

Suprachoroidal hemorrhage (SCH) is rare and most commonly associated with intraocular surgery, which has an extremely poor visual prognosis. It is even rare to occur spontaneously. Most cases of spontaneous suprachoroidal hemorrhage were related to underlying medical illness and drug-related [1–3]. Systemic risk factors, including old age, hypertension, and atherosclerosis, are identifiable [2]. Age-related macular degeneration (AMD) [3], glaucoma [4], and high myopia [5] are associated ocular risk factors in this condition. Here we present two patients who developed non-surgical-related spontaneous suprachoroidal hemorrhage, without ocular risk factors or trauma.

CASE REPORT

We report two rare cases of non-surgical-related massive spontaneous suprachoroidal hemorrhage. Both patients presented with sudden profound painful vision loss.

The first case is a 73-year-old male with no ocular comorbid, ocular trauma or surgery, who presented with sudden onset painful blurring of vision of the left eye. His medical history included diabetes mellitus and uncontrolled hypertension. On examination, his vision was a perception of light in the left eye and 6/9 over the right eye, with positive relative afferent pupillary defect (RAPD) over the left eye. He had markedly injected left eye with cornea edema, shallow anterior chamber and closed angle. The anterior chamber over



Figure 1. B-scan demonstrated a near-kissing suprachoroidal hemorrhage

the right eye was deep with an open angle. His intraocular pressure (IOP) was 68 mmHg over the left eye and 19 mmHg over the right eye. Fundus examination revealed suprachoroidal hemorrhage and was confirmed with an ultrasound scan (B scan) of the left eye, which demonstrated a near-kissing suprachoroidal hemorrhage (Figure 1). His blood pressure (BP) was 196/106 mmHg. His complete blood count and coagulation test were normal. He was admitted; thus, oral Acetazolamide 250 mg four times daily and syrup glycerol (1 g/kg body weight) thrice daily was commenced. Locally Gutt Timolol twice daily, Gutt Latanoprost at night, Gutt Dorzolamide thrice daily, and Gutt Brimonidine thrice daily were given to control his eye pressure. Two antihypertension medications were also started to control his blood pressure. Despite maximum medical therapy, his intraocular pressure was persistently high. He underwent left eye suprachoroidal drainage surgery, which subsequently managed to maintain his intraocular pressure. Unfortunately, his vision remained poor postoperatively, despite surgery, good IOP and BP control.

The second case is a 59-year-old male with a history of left eye resolved extrafoveal idiopathic polypoidal choroidal vasculopathy (IPCV), who presented with a right eye sudden onset profound painful loss of vision. He is a known case of post valve replacement surgery on lifelong warfarin. On examination, his right vision was hand movement (HM), while 6/12 was over his left eye. The right eye's IOP was 47 mmHg, and the left was 12 mmHg. On slit lamp examination, epithelial cornea edema was noted with a shallow anterior chamber over the right eye. Fundus could not be evaluated due to media haze. An ultrasound scan (B-scan) showed massive submacular and suprachoroidal hemorrhage (Figure 2). The patient was admitted and started on oral medications; syrup glycerol thrice daily and tablet acetazolamide 250 mg thrice

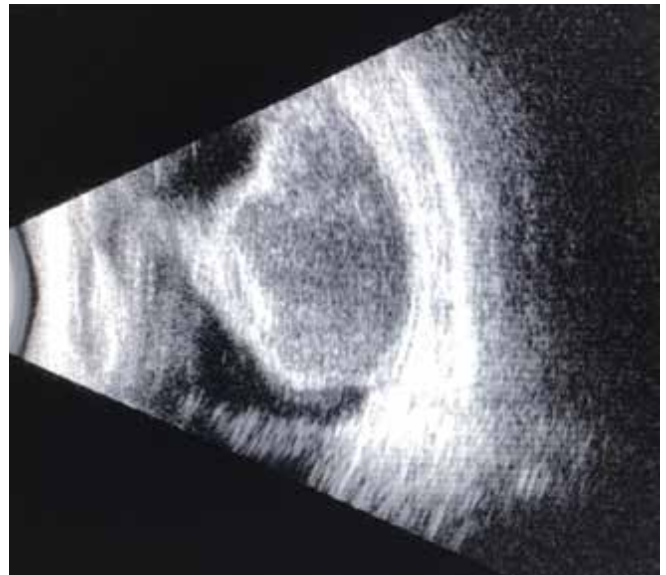


Figure 2. B-scan revealed massive suprachoroidal hemorrhage

daily. Locally Gutt Timolol twice daily, Gutt Latanoprost at night, Gutt Dorzolamide thrice daily, and Gutt Brimonidine thrice daily were given to control his eye pressure. The complete blood count, liver function test and coagulation test revealed no abnormalities with INR 2.2 (within therapeutic range). His intraocular pressure was controlled, and systemic medication and topical anti-glaucoma were withdrawn stepwise in the next two days. Given a poor visual prognosis, he opted for conservative medical treatment and discharge home.

DISCUSSION

Intraocular surgery may be associated with suprachoroidal hemorrhage with a poor visual prognosis. Non-surgical-related spontaneous suprachoroidal hemorrhage is even rare. Few patients are at risk of developing spontaneous suprachoroidal hemorrhage. Ophthalmic risk factors include glaucoma, aphakia, elevated IOP, axial myopia [5], ocular inflammation and AMD [4, 5]. Systemic risk factors include old age, hypertension and atherosclerosis [2, 6, 7].

Fragile choroidal and posterior ciliary vasculature may have an etiological role in patients with high myopia [5], aphakia, intraocular hypertension, inflammation, systemic hypertension and arteriosclerosis [2]. Some suggested that choroidal vascular abnormalities secondary to AMD and axial myopia may also predispose to spontaneous hemorrhage [4]. Although not assessed, we hypothesize that one of our patients may have underlying choroidal abnormalities secondary to AMD, as the fellow eye had resolved IPCV before. Impaired hemostasis can precipitate bleeding, which erupts through all layers of the retina and flows into the vitreous cavity in those groups of patients who use anticoagulants with deranged INR [9].

There will be forward displacement of the lens-iris diaphragm, resulting in angle closure [4] seen in this group of patients. The initial treatment is directed toward angle closure in which IOP-lowering drugs are used to control IOP. Treatment is then directed towards suprachoroidal hemorrhage once IOP is medically controlled. A few factors include lens cornea touch, progressive IOP elevation, progressive angle-closure glaucoma, appositional choroidal detachment [4], and intolerable pain in which surgical treatment is indicated. Still, it is best deferred for 1–2 weeks [2,8] until the clot lysis is completed, although the timing is still controversial [9]. One of our patients needed surgical intervention due to progressive IOP elevation with intolerable pain. In contrast, IOP was controlled with medication for the other patient, and no surgical intervention was performed.

CONCLUSION

Cardiovascular disease, including hypertension, may increase the risk of complications. Those patients are usually older and more likely at risk of developing AMD. Even though rare, suprachoroidal hemorrhage should be considered if suspicious signs are present in these people.

Thus, prevention is crucial, and it involves ophthalmologists, physicians and general practitioners in managing this group of patients with associated risk factors, for better recognition of this devastating ocular complication in which early detection may reduce ocular morbidity.

Acknowledgements

Ophthalmologist and Staff of the Ophthalmology Department, Hospital Sultanah Bahiyah, Alor Setar, Kedah, Malaysia.

REFERENCES

1. Aman C, Allon B, Charles H. A spontaneous suprachoroidal haemorrhage: a case report. *Cases Journal*. 2009 Nov;2:185.
2. Ophir A, Pikkil J, Groisman G. Spontaneous expulsive suprachoroidal haemorrhage. *Cornea*. 2001 Nov; 20(8):893-896.
3. Thomas GC, Ronald LG. Suprachoroidal haemorrhage, *Survey of Ophthalmology*. 1999 May;43:471-486.
4. Alexandrakis G, Chaudhry NA, Liggett PE, Weitzman M. Spontaneous suprachoroidal haemorrhage in age-related macular degeneration presenting as angle closure glaucoma. *Retina*. 1998;18(5):485-486.
5. Chak M and Williamson TH. Spontaneous suprachoroidal haemorrhage associated with high myopia and aspirin. *Eye*. 2003;17:525-527.
6. Fadi EB, William HJ, Thomas SH et al. Massive spontaneous complicating age related macular degeneration: Clinicopathologic correlation and role of anticoagulant. *Ophthalmology*. 1986 Dec;93(12):1581-1592.
7. Sam SY, Arthur DF, McDonald HR, Robert NJ, Everett A, Michael JJ. Massive spontaneous choroidal haemorrhage. *Retina*. 2003 Apr;23(2):139-144.
8. Manuchehri K, Loo A, Ramchandani M, Kirkby GR. Acute suprachoroidal haemorrhage in a patient treated with streptokinase for myocardial infarction. *Eye*. 1999;13:685-686.
9. Ingrid U, Scott MD, Harry W et al. Visual acuity outcomes among patient with appositional suprachoroidal haemorrhage. *Ophthalmology*. 1997 Nov;104(12):2039-2046.