

ABNORMAL CORNEAL LESION FOLLOWING CATARACT SURGERY; A CORNEAL PYOGENIC GRANULOMA? A CASE REPORT

Ghafarian S.¹, Sheikhghomi S.², Asadi-Amoli F.³

¹Department of Ophthalmology, Farabi Eye Hospital, School of Medicine, Tehran, Tehran University of Medical Sciences, Tehran, Iran

²Department of Ophthalmology, Madani Hospital, School of Medicine, Alborz University of Medical Sciences, Karaj, Iran

³Department of Ophthalmology, Farabi Eye Hospital, School of Medicine, Tehran, Tehran University of Medical Sciences, Tehran, Iran

The authors declare that they have NO affiliations with or involvement in any organization or entity with any financial interest in the subject matter or materials discussed in this manuscript. The authors of the study declare that no conflict of interest exists in the compilation, theme and subsequent publication of this professional communication, and that it is not supported by any pharmaceutical company. The study has not been submitted to another journal and is not printed elsewhere, with the exception of congress summaries and recommended procedures.

Received: 25 September 2022

Accepted: 15 November 2022



First author:
Sadeq Ghafarian, MD

Corresponding author:
Sima Sheikhghomi, MD
Madani Hospital, Jahanshahr, Karaj
Alborz province
Iran. 3149779453
E-mail: sshaiikhghomi@yahoo.com

SUMMARY

Background: Description of an abnormal corneal lesion as a complication of a clear corneal incision in cataract surgery.

Case presentation: A 55-year-old woman presented, complaining of right eye pain and redness for 6 months, which started 1 month after her uncomplicated cataract surgery. On gross examination, the bulbar conjunctiva was hyperemic and a vascularized salmon-pink nodule with a smooth surface was noted over the supratemporal region of the cornea, just anterior to the previous superior corneal incision, with superficial feeder vessels originating from the adjacent conjunctiva toward the lesion. The lesion was removed and histopathological examination revealed an inflammatory tissue containing inflammatory cells and capillaries within a background of fibrotic tissue throughout the lesion.

Conclusions: Reactive fibrovascular nodules are rare corneal lesions following corneal trauma and vascularization, including a clear corneal cataract surgery incision. Ophthalmologists may encounter these lesions during postoperative visits and should be familiar with their appearance and management.

Keywords: cornea, incision, pyogenic granuloma

Čes. a slov. Oftal., 79, 2023, No. 1, p. 50–53

INTRODUCTION

A clear corneal incision in cataract extraction surgeries may be accompanied by both early and late corneal complications, including wound leakage, corneal astigmatism, epithelial ingrowth, Descemet membrane detachment, and wound burn [1-4]. Most surgeons are familiar with these complications and their management. In this case report, we describe a very uncommon complication of cataract surgery incision and its treatment.

Case description

A 55-year-old woman living in an urban area presented to our Clinic with the complaint of right eye pain and redness for 6 months, which started 1 month after

the uncomplicated cataract surgery that she had undergone at another eye surgery center. During this time, she showed no improvement in her symptoms, regardless of the use of a wide array of topical drugs, including antibiotics, steroids, and non-steroid anti-inflammatory eye drops. The patient denied any history of ocular surface disorder including infectious or autoimmune causes or any recent eye trauma. On gross examination, the bulbar conjunctiva was hyperemic, mainly on the temporal side of the right eye, and her uncorrected visual acuity was 10/10 (Snellen chart) in both eyes. A more detailed examination using a slit lamp showed no marked blepharitis, but a vascularized salmon-pink nodule with a smooth surface was noted over the supratemporal region of the cornea just anterior to the previous superior corneal inci-

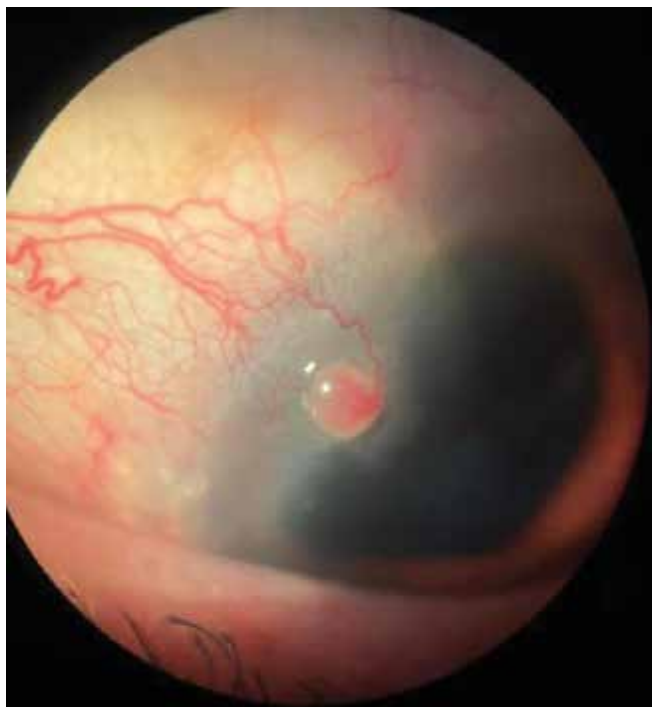

Figure 1. Salmon pink nodule with smooth surface and feeder vessels from the nearby conjunctiva on the supratemporal region of the cornea after cataract surgery

sion, with superficial feeder vessels originating from the adjacent conjunctiva toward the lesion. In addition, the underlying cornea was slightly edematous without any obvious epithelial defects on fluorescein staining (Figure 1). The remaining examinations of the same eye including the palpebral conjunctiva and fornices revealed no further pathologies and the examination of the other eye was normal.

According to the patient's medical and surgical history and the location and characteristics of the lesion, she was diagnosed with an acquired corneal pyogenic granuloma. Considering the non-improving and prolonged course of the lesion, we planned to excise the lesion. In the operating room and under topical anesthesia, the lesion was first grasped with Colibri forceps and then removed using Vannas scissors. Subsequent bleeding of the cut vascular pedicles was first controlled by mild pressure with a cotton-tip applicator. Thereafter, a 10–0 needle was inserted directly into the lumens of the main feeder vessels at the limbus, and low-power monopolar cauterization (1–2 mJ) was applied to the other end of the needle. Finally, subtenon steroid was injected.

Histopathological examination of the lesion revealed an inflammatory tissue, containing numerous endothelial cell-lined capillaries with perivascular inflammatory

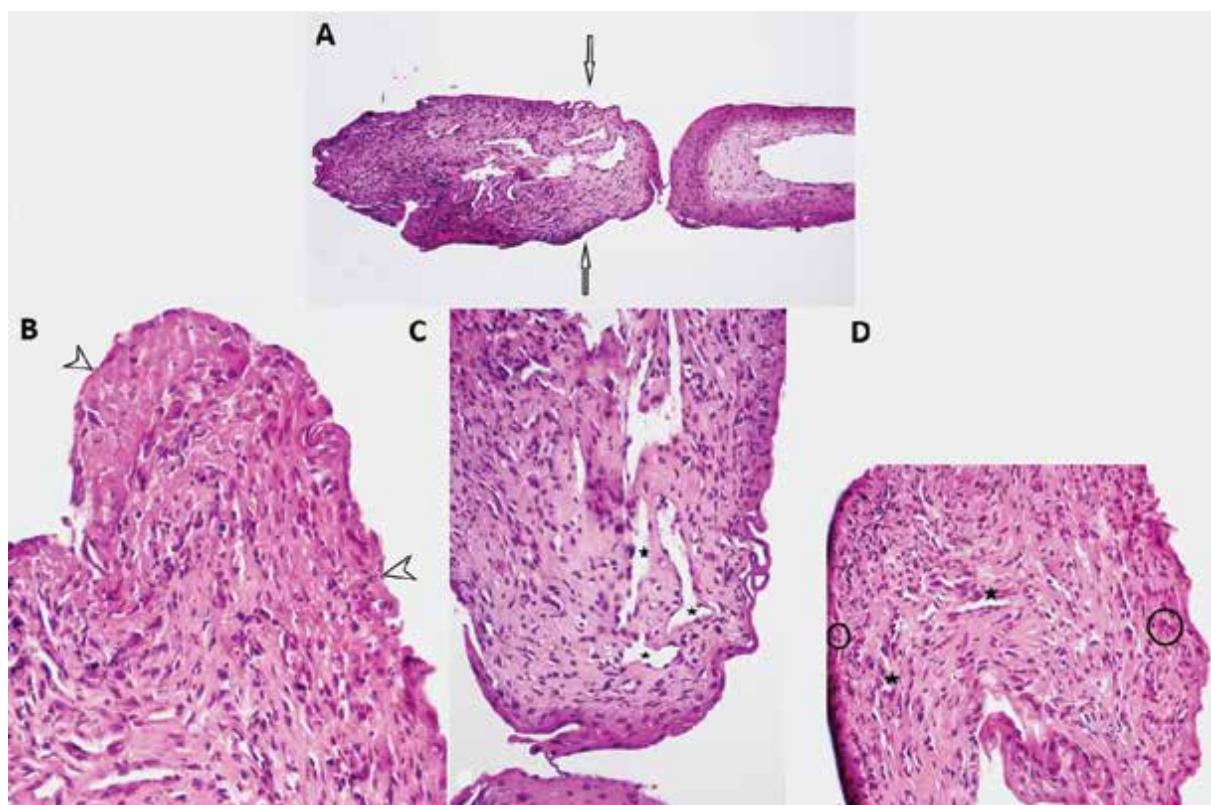


Figure 2. Microscopic examination of the excised lesion with Hematoxylin and Eosin staining shows superficial corneal tissue attached to an elevated lesion (A) [arrows], with loss of superficial epithelium which was replaced by fibrino-leukocytic exudate (B) [arrowheads]. underlying connective tissue stroma was fibrous and revealed numerous endothelial cell lined capillaries (stars) with perivascular inflammatory infiltration (circles) and thick bundles of collagen fibers throughout the stroma (C, D)

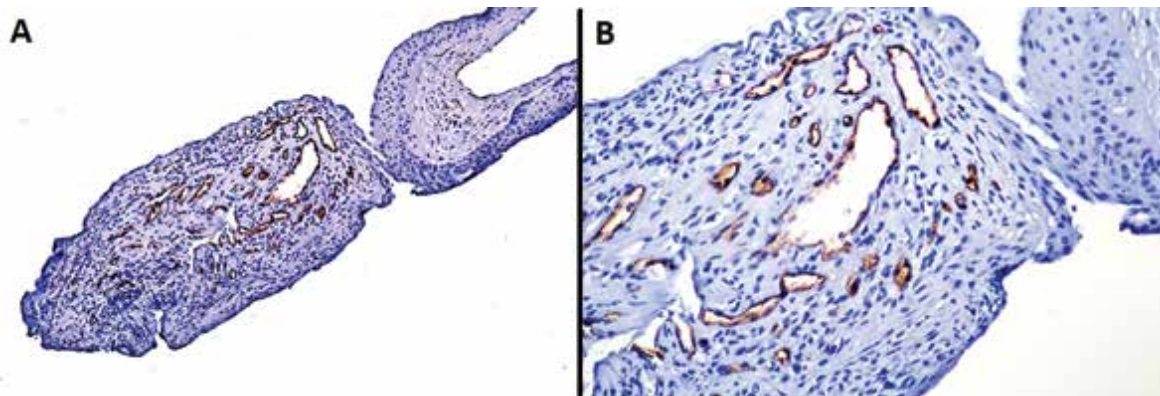


Figure 3. Immunohistochemistry staining shows positive reaction for CD34 in blood vessels (A), higher magnification (B)

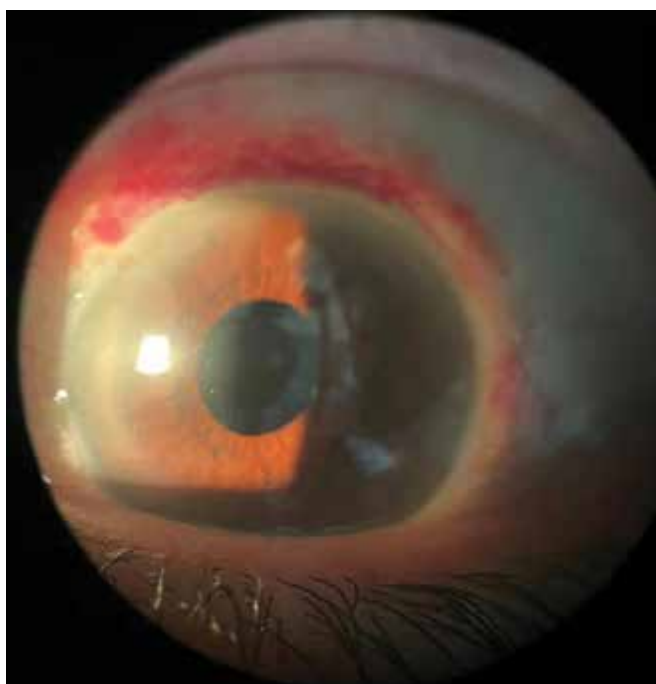


Figure 4. Post-operative view of the corneal surface after excisional biopsy

infiltration and thick bundles of collagen fibers throughout the stroma. Furthermore, the top of the lesion was not covered with the epithelium and was replaced by a fibrino-leukocytic exudate and, on investigation of the base of the lesion, no corneal intraepithelial neoplastic cells in favor of CIN could be detected (Figure 2). These histopathological findings along with the macroscopic appearance of the lesion were more in favor of chronic or late-stage of a non-lobular type of pyogenic granuloma or granulation tissue. Therefore, we also performed anti-CD34 immunohistochemical staining to determine the vascularity of the lesion (Figure 3).

Following the surgery (Figure 4), topical betamethasone every 2 hours and topical chloramphenicol every

6 hours were prescribed. The 2-month follow-up of the patient was associated with tapering of the topical steroid. No recurrence or obvious scar was detected and the patient experienced no more ocular symptoms.

DISCUSSION AND CONCLUSION

Pyogenic granuloma is a reactive inflammatory and highly vascular lesion, secondary to surgery or chronic trauma to the skin, mucous membranes, and rarely the cornea. In the earlier phase of the formation, pyogenic granulomas are more cellular, which is called the "cellular phase". In time, the vascularity of the lesion increases, so it is named the "vascular phase"; and, finally, the fibrotic tissue may predominate and the lesion involutes to what is called the "involutionary phase". However, naturally, the cornea is an avascular tissue; hence corneal vascularization is a prerequisite for the development of corneal pyogenic granulomas [5-7]. Nevertheless, corneal pyogenic granulomas differ from those of other sites in that they are more sessile rather than pedunculated and lack the typical corkscrew pattern of vascular proliferation seen in pyogenic granulomas of the skin and mucous membranes [8]. Similarly, our patient developed a corneal fibrovascular lesion subsequent to the cataract surgery incision, which appeared as a sessile vascular granuloma without the typical lobular appearance.

There are only a few reports of corneal pyogenic granulomas in the literature; although corneal pyogenic granuloma is considered a rare lesion, it can be diagnosed by relevant history taking and meticulous examination. Due to their rarity, most of the reported corneal pyogenic granulomas have been excisionally biopsied to distinguish them from other suspected lesions, including malignant corneal lesions [9-11]. However, there is one report of a pyogenic granuloma being dislodged by itself [12]. Histopathological investigations of corneal pyogenic granulomas show inflammatory cells, composed mostly of plasma cells and lymphocytes in a highly vas-

cularized and inflamed stroma with intact or ulcerated epithelium [9]. Differential diagnoses of pyogenic granulomas vary, depending on the phase of the lesion which affects the vascularity and color of the lesion. In the earlier phases with high cellular reaction, it may masquerade as infectious keratitis and inflammatory nodules such as phlyctenules. In the vascular and involutionary phases, these lesions may mimic the appearance of neoplastic, vascular tumors or chronic lesions [5].

In our patient, we chose the surgical option, not only to confirm the diagnosis, but also to relieve the ocular symptoms that were resistant to topical therapies. Although histopathological examination of the lesion showed a fibrovascular reaction, it was not representative of a typical pyogenic granuloma, which has a lobular appearance and consists of a high density of radial branching vessels and a high cellular mitosis rate. Therefore, we decided to stain the lesion with anti-CD34 antibodies to ensure the confirmation of its high vascularity. On the other hand, it is well known in the literature that the appearances and microscopic features of

pyogenic granulomas differ according to the stage, but all fall into one spectrum.

Unless the surgical cases in which overhealing of the wound closure is the reason for the lesion development, the underlying irritating causes, including trichiasis, punctal plugs, consuming contact lenses, or some topical drugs, should be detected and treated [13-16]. Therefore, the recurrence rate following pyogenic granuloma treatment depends on the underlying cause and management. With attention to the literature and our patient, it seems that the best management for reactive corneal nodules would be surgical excision, due to the high corneal irritation and the undetermined response of these lesions to anti-inflammatory therapies.

In conclusion, fibrovascular nodules, including pyogenic granulomas, are rare corneal lesions following corneal trauma and vascularization, including a clear corneal cataract surgery incision. Ophthalmologists may encounter these lesions during postoperative visits and should be familiar with their appearance and management.

REFERENCES

1. Gogate, Parikshit M. Small incision cataract surgery: Complications and mini-review. *Indian J. Ophthalmol.* 2009;57(1):45-49.
2. Xia Y, Liu X, Luo L, et al. Early changes in clear cornea incision after phacoemulsification: an anterior segment optical coherence tomography study. *Acta Ophthalmol.* 2009;87(7):764-768.
3. Dugan Jr JD, Bailey Jr RS. Complications of cataract surgery. *Ophthalmology Secrets E-Book.* 2022 Feb 25:211.
4. Al Mahmood AM, Al-Swailem SA, Behrens A. Clear corneal incision in cataract surgery. *Middle East African J Ophthalmol.* 2014 Jan;21(1):25.
5. Marla V, Shrestha A, Goel K, et al. The histopathological spectrum of pyogenic granuloma: a case series. *Case Rep Den.* 2016 Jun 12;2016.
6. Frydkjær AG, Krogerus C, Løvenwald JB. [Pyogenic granuloma]. *Ugeskr Laeger.* 2021 Jul 19;183(29):V12200898.
7. Shields CL, Shields JA. Tumors of the conjunctiva and cornea. *Surv Ophthalmol.* 2004 Jan;49(1):3-24.
8. Mietz H, Arnold G, Kirchhof B, et al. Pyogenic granuloma of the cornea: report of a case and review of the literature. *Graefes Arch. Clin. Experimental Ophthalmol.* 1996 Feb;234(2):131-136.
9. Cameron JA, Mahmood MA. Pyogenic granulomas of the cornea. *Ophthalmol.* 1995 Nov 1;102(11):1681-1687.
10. Minckler D. Pyogenic granuloma of the cornea simulating squamous cell carcinoma. *Arch Ophthalmol.* 1979 Mar;97(3):516-517.
11. Googe JM, Mackman G, Peterson MR, et al. Pyogenic granulomas of the cornea. *Surv Ophthalmol.* 1984 Nov;29(3):188-192.
12. Papadopoulos M, Snibson GR, McKelvie PA. Pyogenic granuloma of the cornea. *Aust J Ophthalmol.* 1998 May;26(2):185-158.
13. Proia AD, Small KW. Pyogenic granuloma of the cornea induced by "snake oil". *Cornea.* 1994 May;13(3):284-286.
14. Srinivasan S, Prajna NV, Srinivasan M. Pyogenic granuloma of cornea: A case report. *Indian J Ophthalmol.* 1996 Jan;44(1):39.
15. Al-Towerki AA. Pyogenic granuloma. *Int Ophthalmol.* 1995 Sep;19(5):287-291.
16. Abateneh A, Bekele S. Case Report: Corneal Pyogenic Granuloma: Rare Complication of Infectious Keratitis. *Ethiop J Health Sci.* 2014 Apr 15;24(1):85-88.