

THE EFFECT OF THERAPY ON THE OCULAR SURFACE IN PATIENTS WITH UNILATERAL PAEDIATRIC GLAUCOMA

Janderová M.¹, Filouš A.¹, Hložánek M.¹, Dotřelová D.¹,
Mahelková G.^{1,2}

¹ Department of Ophthalmology, 2nd Faculty of Medicine, Charles University and Motol University Hospital

² Institute of Physiology, 2nd Faculty of Medicine, Charles University

Supported by the project of the Ministry of Health for conceptual development of the research organisation 00064203 FN MOTOL.

The authors of the study declare that no conflict of interest exists in the compilation, theme and subsequent publication of this professional communication, and that it is not supported by any pharmaceuticals company. The study has not been submitted to any professional journal or printed elsewhere, with the exception of congress abstracts

Received: 29 July 2020

Accepted: 22 December 2020

Available on-line: 11 March 2021



MUDr. Martina Janderová

Corresponding author:

MUDr. Gabriela Mahelková, Ph.D.

Oční klinika dětí a dospělých

2. LF UK a FN v Motole

V Úvalu 84

150 06 Praha 5

gabriela.mahelkova@fnmotol.cz

SUMMARY

Purpose: The aim of the study was to evaluate ocular surface and tear film in patients with pediatric (primary or secondary) unilateral glaucoma and compare results obtained from the treated eye and untreated healthy eye.

Methods: Patients with unilateral pediatric glaucoma, followed in the outpatient department of the Department of Ophthalmology, Motol University Hospital, were included in this study. Tear osmolarity, corneal epithelial thickness, lower tear meniscus area, Schirmer test, corneal fluorescein staining and tear break-up time test (TBUT) were evaluated in both healthy and treated eye. The Ocular Surface Disease Index (OSDI) was used to establish subjective impairment. The values obtained through testing the healthy and treated eye were compared.

Results: Thirteen patients met the inclusion criteria of the study. The mean age of the patients was 17.2 ± 8.1 years. There was statistically significant decrease in corneal epithelial thickness and TBUT in the treated eye ($45.9 \pm 5.3 \mu\text{m}$, 6.0 ± 1.7 second resp.) compared to the healthy eye ($50.2 \pm 2.6 \mu\text{m}$, 8.8 ± 3.2 second resp.; $p = 0.0106$, $p = 0.0015$ resp.). Fluorescein staining score of the ocular surface was higher in the treated eye (1.7 ± 2.1) than in the healthy eye (0.5 ± 0.8 ; $p = 0.0243$). We found no statistically significant difference in the other evaluated parameters between the treated and the healthy eyes.

Conclusion: The results confirmed signs of ocular surface damage in treated eyes. The damage may be induced by chronic topical antiglaucoma therapy, but that could be a consequence of the previous ocular surgery as well. The possible damage of the ocular surface should be taken into account when selecting appropriate treatment in these patients.

Key words: ocular surface, antiglaucoma therapy, preservative agent

Čes. a slov. Oftal., 77, 2021, No. 1, p. 28–34

INTRODUCTION

Glaucoma is a heterogeneous group of pathologies, the most significant risk factor of which is increased intraocular pressure (IOP). In children we distinguish between primary glaucoma (congenital, infantile, juvenile) and secondary glaucoma, the latter of which is caused by an impediment of draining of the chamber fluid as a consequence of another ocular or systemic pathology [1]. In both cases this may be only a unilateral affliction.

The aim of glaucoma treatment is to prevent apoptosis of the retinal ganglion cells by means of reducing intraocular pressure and improving ocular perfusion, and therefore

to prevent the progression of the pathology. In treatment of paediatric glaucomas it is often necessary to indicate a surgical procedure already in the early phase, and in the case of resolving congenital glaucomas surgical treatment is the primary method. Despite this, in many cases it is subsequently necessary to continue with medicamentous therapy using locally applied preparations.

The negative influence of preservative agents in eye drops on the development of damage to the tissues of the ocular surface and the onset of dry eye syndrome has now been well documented [2–6]. Dry eye syndrome (DES) is a multifactorially conditioned disorder of tears and the ocular surface, which is connected with instability of the tear

film and subjective complaints on the part of the patient, including deterioration of visual acuity. Impairment of homeostasis of the ocular surface and the tear film leads to an increase of osmolarity of the tear film, and the activation of a cascade of anti-inflammatory factors. The development of chronic inflammation leads to a further impairment of stability of the tear film – thus a vicious cycle is established [7,8].

Symptoms of dry eye syndrome have been described in up to 60 % of adults patients treated for glaucoma [4,9,10,11]. With regard to the long-term application of antiglaucoma drops, patients with glaucoma are chronically exposed to the effect of preservative substances [12]. The toxic effect of these substances, in particular benzalkonium chloride (BAK), may explain the high prevalence of dry eye syndrome observed in this group of patients and the correlation between symptoms, the number of applied antiglaucomatous drugs and the duration of treatment [2,6,13,14]. However, changes of the tear film and the ocular surface have been described also following antiglaucoma and other ocular surgeries [15-17].

The aim of the study was to evaluate changes of the ocular surface and tear film in patients with unilateral paediatric primary or secondary glaucoma, and to compare the findings in the treated eye with the other untreated healthy eye.

METHOD

The study included patients with unilateral glaucoma who underwent long-term observation at the paediatric clinic at the Department of Ophthalmology of the 2nd Faculty of Medicine, Charles University and Motol University Hospital. The patients were actively sought in the period of 2016-2018 from the available patient database, and invited to take part in the study. The study included only patients who were interested in taking part in the study and were capable of undergoing the relevant examination. All the participants in the study signed an informed consent form approved by the Ethical Commission of Motol University Hospital.

A detailed medical history of the patients was recorded (length of observation of glaucoma, surgical procedures, length and type of used medicamentous therapy), as well as the precise diagnosis. A detailed ocular examination was also performed, including best corrected central visual acuity (BCVA), the current values of intraocular pressure (IOP) were recorded, an examination of tear osmolarity was performed, as well as an examination of the corneal epithelial thickness (CET), an examination of the lower tear meniscus area (LTMA), Schirmer test I (ST1, without application of anaesthetic), staining of the ocular surface with the aid of fluorescein and evaluation of the stability of the tear film by a tear break-up time test (TBUT). Tear osmolarity was measured using the instrument TearLab Osmolarity System (TearLab Corop, San Diego, CA, USA). A tear sample (50 nl) was taken from the lower temporal tear meniscus with the aid of a microchip, and was subsequently analysed by an automatic instrument. Osmolarity was measured twice, al-

ways simultaneously in both eyes, and the mean value was recorded, as well as the higher of both values for each eye. Measurement of CET of the cornea and LTMA was performed using a Fourier-Domain AS-OCT system (Optovue Inc., Fremont, CA, USA) with the corneal adaptation extension CAM-L. We measured the LTMA on a 4-millimetre vertical scan (scan designated for imaging of chamber angle), which was rotated vertically and centred to the lower tear meniscus at number 6, with the patient in upward gaze position. The surface was measured with the aid of an instrument for measuring the surface, which is available within the framework of the instrument software (Fig. 1). CET of the cornea was read on a horizontal OCT cross-section of the cornea in three places, and the mean value was recorded for each eye. For evaluation of the vital staining of the ocular surface, we used an evaluation according to the Oxford schema [18]. The schema contains 5 panels A-E, in which 3 zones are displayed on each of the panels: temporal bulbar conjunctiva – cornea – nasal bulbar conjunctiva. The range of punctate epitheliopathy of each zone is evaluated from 0 to 5, the maximum possible value is 15 (corresponding to a finding of severe epitheliopathy in all three zones). We evaluated the finding after blinking of the patient with the aid of a slit lamp and slip-on blue filter. In the evaluation of the stability of the tear film (TBUT; evaluation of time from blinking to the break-up of the tear film), the measurement was performed three times and the mean value was recorded. A standardised questionnaire (Ocular Surface Disease Index, OSDI; modification evaluating complaints for each eye separately) was used for determining subjective complaints. In the questionnaire, on a scale of 0-4 (0 – never, 1 – occasionally, 2 – half the time, 3 – most of the time, 4 – constantly) patients evaluate the subjective incidence of complaints during the course of the previous week with the aid of 12 questions. We subsequently obtain the resulting score by substituting this into the formula. The results fluctuate within the range of 0-100, in which a higher score represents greater affliction (0-12 = normal; 13-22 = mild DES; 23-32 = moderately advanced SSO; 33-100 = advanced SSO).

Values were compared between the treated eye and the healthy eye without treatment. The results are presented

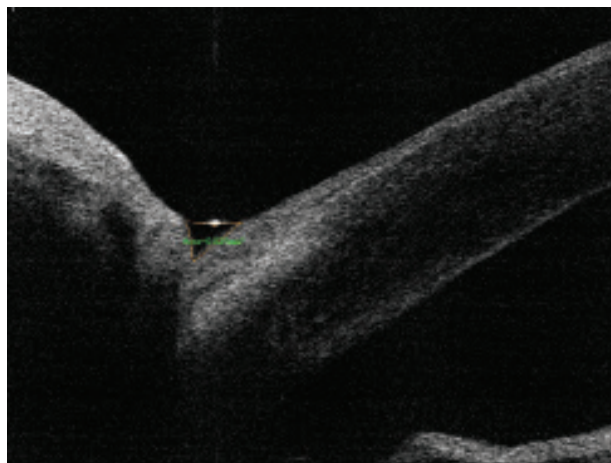


Fig. 1. Measurement of lower tear meniscus area (LTMA)

as the mean values \pm SD. The results were statistically analysed with the aid of a paired t-test (software for statistical data processing StatView 5.0 (SAS Institute Inc., Cary, NC, USA) in the case of parametric data distribution, and with the aid of a Wilcoxon paired test for non-parametric data. The borderline of statistical significance was considered to be the value of $p < 0.05$.

RESULTS

Within the framework of the study a total of 13 patients were examined. The mean age of the patients was 17.2 ± 8.1 years (range 6-32 years). All the patients applied anti-glaucoma therapy only into one eye, the other eye was healthy and without treatment.

Six patients were observed with primary unilateral glaucoma, the remaining patients with secondary unilateral

glaucoma – three patients after surgery for congenital unilateral cataract, one patient after cataract surgery with persistent fetal vasculature, in two patients the basic diagnosis was Sturge-Weber syndrome, in one patient ectropion uveae. The mean length of treatment of the eye with glaucoma was 13.6 ± 7.9 years (range 3-29 years). In all cases, the patients were treated with local preparations with a content of preservative substances (BAK). All the patients had undergone at least one operation on the treated eye, twelve patients had undergone an antiglaucoma procedure, in four patients we had performed surgery of congenital cataract. The mean value of intraocular pressure in the treated eye was 15.9 ± 4.3 mmHg (range 8-23 mmHg), in the healthy eye 15.8 ± 3.1 mmHg (range 13-21 mmHg). The differences between the values of intraocular pressure in the treated and healthy eye were not statistically significant ($p = 0.9231$). None of the patients used preparations

Table 1. Characteristics of cohort of patients

Patient no.	Age at time of examination (years)	Primary diagnosis	Total treatment time (years)	Antiglaucoma therapy	Length of treatment with stated preparation	Performed antiglaucoma procedure	IOP, treated eye (mmHg)	IOP, healthy eye (mmHg)	BCVA, treated eye	BCVA, healthy eye
1	17	Primary congenital glaucoma	16	Xalatan	10	TO	16	18	1.0	1.0
2	32	Sturge-Weber syndrome	29	Xalacom	5	TO, TE 2x	20	20	0.5	1.0
3	18	Primary congenital glaucoma	18	Xalacom	11	TO 2x	14	13	0.3	1.0
4	14	Congenital cataract	14	Azarga	3	---	20	18	0.004	1.0
5	17	Persistent foetal vasculature	9	Cosopt	6	TO 3x	15	17	movement	1.0
6	14	Congenital cataract	12	Azarga	2	CPC 3x	17	16	0.025	1.0
7	6	Sturge-Weber syndrome	5	Azarga	2	TO, CPC 3x	15	16	1.0	1.0
8	28	Primary congenital glaucoma	25	Ganfort	7	TO	15	14	0.003	0.8
9	18	Congenital cataract	5	Azarga	3	SLT	23	21	0.6	0.8
10	12	Ectropion uveae	10	Cosopt	4	TE, CPC	21	16	1.0	1.0
11	29	Primary congenital glaucoma	3	Carteol	3	TE	13	10	0.3	1.0
12	13	Primary congenital glaucoma	12	Carteol	6	TO	10	14	1.0	1.0
13	6	Primary congenital glaucoma	6	Carteol	6	TO	8	13	1.0	1.0

IOP – intraocular pressure at time of examination

BCVA – best corrected visual acuity

TO – trabeculotomy

TE – trabeculectomy

CPC – cyclophotocoagulation

SLT – selective laser trabeculoplasty

of the type of artificial tears. The characteristics of the cohort of patients are presented in summary in table 1.

The results of the examinations of the individual patients are presented synoptically in table 2. None of the patients stated subjective complaints determined with the aid of the OSDI questionnaire in the healthy eye. Subjective complaints in the treated eye were recorded as minimal for twelve patients, with the score fluctuating within the range of 0-10.4 points (corresponding to the range of normal values). Only in one patient were the values of the OSDI score almost 40, which attests to advanced DES.

Mean tear osmolarity in the treated eye was 305.0 ± 9.9 mosmol/l, and in the healthy eye 307.3 ± 11.6 mosmol/l. The differences in the values between the healthy and treated eye were not statistically significant ($p = 0.4317$). The value of tear osmolarity in the treated eye in all patients fluctuated within the limits of the norm. In the healthy eye in four cases osmolarity was higher than 316 mosmol/l.

Mean corneal CET in the treated eye was 45.9 ± 5.3 μm , in the healthy eye 50.2 ± 2.6 μm . Corneal CET in the treated eye was statistically significantly lower than in the healthy eye ($p = 0.0106$). Mean LTMA in the treated eye was 0.024 ± 0.027 mm², in the healthy eye 0.034 ± 0.029 mm². The difference was not statistically significant ($p = 0.1596$).

The mean value of the Schirmer test for the treated eye was 28.5 ± 10.9 mm/5 min, and in the healthy eye 27.3 ± 9.5 mm/5 min. The values were not statistically significant

ly different ($p = 0.5665$). The values of the Schirmer test were reduced in the treated eye in two patients (below 10 mm/5 min; no. 11 and 13), in one of these patients the value was reduced also in the healthy eye (no. 11), in the second patient (no. 13) the value was borderline in the healthy eye. In the other patients the values in both the treated and the untreated eye were within the limits of the norm.

We did not demonstrate clinically severe affliction of the ocular surface in any single case within the aid of fluorescein staining. However, the ocular surface was stained by fluorescein statistically significantly more in the treated eyes (1.7 ± 2.1) than in the healthy eyes (0.5 ± 0.8 ; $p = 0.02433$). The values of TBUT in the treated eyes (6.0 ± 1.7 s) were statistically significantly lower than in the healthy eyes (8.8 ± 3.2 s; $p = 0.0015$).

DISCUSSION

It has now been well documented by a series of studies that chronic local antiglaucoma therapy increases the risk of development of DES in patients, either as a consequence of the content of preservative substances or as an adverse effect of the active agent itself [6,10,12,13,19,20,21].

The diagnosis of DES, especially the initial stages of the pathology, is difficult. After introducing testing of tear osmolarity, some authors have demonstrated good specificity and sensitivity of this examination in the diagnosis

Table 2. Results of individual measurements

Patient no.	OSDI, treated eye	Mean osmolarity, treated eye (mosmol/l)	Higher osmolarity value, treated eye (mosmol/l)	Mean osmolarity, healthy eye (mosmol/l)	Higher osmolarity value, healthy eye (mosmol/l)	CET, treated eye (μm)	CET, healthy eye (μm)	LTMA, treated eye (mm ²)	LTMA, healthy eye (mm ²)	Schirmer test, treated eye (mm/5 min)	Schirmer test, healthy eye (mm/5 min)	Fluorescein staining, treated eye	Fluorescein staining, healthy eye	TBUT, treated eye (s)	TBUT, healthy eye (s)
1	2,1	312,5	317	300	302	48	50	0,003	0,009	25	34	4	1	7	14
2	4,2	314,5	324	321,5	328	48	51	0,013	0,029	35	15	0	0	8	10
3	4,2	305,5	307	304,5	306	35	47	0,021	0,01	35	35	0	0	7	10
4	39,6	302	304	316,5	322	55	50	0,003	0,007	35	25	1	0	2,5	2,5
5	10,4	305,5	307	302	307	51	54	0,005	0,01	35	35	5	0	6	10
6	4,2	301,5	303	322,5	330	41	51	0,011	0,016	25	23	0	0	7	9
7	6,1	311	313	308,5	310	47	51	0,015	0,09	35	35	5	0	7	9
8	4,2	324	330	318,5	322	41	47	0,009	0,029	35	35	4	2	3	5
9	4,2	301,5	305	298	306	44	47	0,08	0,07	35	35	0	0	5	7
10	0,0	307,5	322	320,5	321	44	51	0,08	0,08	30	25	2	1	5	12
11	2,1	302	303	301	302	50	48	0,024	0,029	6	9	1	2	5	6
12	0,0	283,5	291	293,5	296	47	55	0,025	0,026	35	35	0	0	6	9
13	0,0	294,5	299	287,5	291					5	14	2	1	7	12

OSDI – standardised questionnaire for evaluating subjective complaints

CET – corneal epithelial thickness

LTMA – lower temporal meniscus area

TBUT – tear break-up time

of DES, and proposed measurement of osmolarity as the "gold standard" for the diagnosis of the pathology [22-25]. In patients treated with antiglaucomatous drugs, a correlation has been demonstrated between tear osmolarity and the results of evaluation of subjective complaints with the aid of OSDI, TBUT values, the number of applied preparations and the frequency of application of drugs per day [2,14,26,27].

In our study the values of tear osmolarity were highly variable, and the values in the treated eyes did not demonstrate a significant difference in comparison with the values of the healthy eyes. In fact, values considered pathological (above 316 mosmol/l) were recorded also in healthy eyes. Our results thus correspond with other studies that indicate disparate results of measurement of osmolarity and a lack of consensus on the threshold value of tear osmolarity [23,28-31]. Halkiadis et al. did not demonstrate any difference in tear osmolarity in patients treated with antiglaucomatous agents without subjective complaints in comparison with the values in healthy control groups [32]. In our study also, the majority of patients stated only minimal or no subjective complaints. Only in one patient did we record more severe subjective complaints. This patient also had a markedly reduced TBUT in both eyes. In our study we did not observe frequency of blinking. Increased frequency of blinking in this patient may have compensated for higher instability of the tear film, and as a result we did not demonstrate pathological results of further examinations. Only small damage to the ocular surface was confirmed by the results of fluorescein staining.

One of the causes leading to the onset of dry eye syndrome (DES) is considered to be the toxic effect of the preservative substances contained in eye drops [6,10,13,33,34]. In general, these substances disrupt the cellular wall of bacteria, and at the same time may increase the penetration of substances through the cornea. The most frequently used preservative agent is BAK. Its good bactericidal properties have long overshadowed its toxic effects on the surface tissues of the eye, conjunctiva and cornea. It has been described that BAK has a pro-apoptotic and anti-inflammatory effect on conjunctival cells, destabilises goblet cells, causes metaplasia of the conjunctival epithelial cells, by damaging the cells of the corneal epithelium impairs its barrier function and increases the activation of keratocytes in the corneal stroma [35-38]. Also in clinical trials, changes in the morphology of the corneal epithelial cells and a reduction of the thickness of the corneal epithelium have been confirmed in patients treated for glaucoma [14,39-41]. In accordance with these results, in our patients we demonstrated lesser thickness of the corneal epithelium in the treated eye. It is assumed that in patients with dry eye syndrome, excessive induction of apoptosis of the epithelial cells occurs as a consequence of a disorder of homeostasis and malfunction of the tear film, and at the same time, due to the influence of reflexively increased blinking frequency, there is an increase of mechanical traction, which leads to a further thinning of the epithelium of the affected cornea. An abnormally rapid turnover

of tissue and hyperplasia of the epithelium is a common reaction to "stress reactions" [8,13,42]. In an endeavour to compensate for increased apoptosis, increased proliferation of epithelial cells may result. This theory is supported also by the results of our previous study on patients with unilateral buphthalmos and the studies by Martone et al., which in treated eyes demonstrated higher density of the basal epithelial cells [43,35] with the aid of a corneal confocal microscope.

The influence of local antiglaucoma therapy on tear production, measured with the aid of a Schirmer test or on the basis of measurement of the lower tear meniscus area, is not clear [19,45,46]. The large dispersion of values of the tear meniscus in treated eyes recorded in our study may support the conclusions of the study by the authors Shimazaki et al., who demonstrated an unchanged or even slightly increased value of the Schirmer test in patients with DES. The authors assume that in the initial stages of DES, reflex hypersecretion may take place [46].

The results of an examination of TBUT in the healthy and treated eye in our study confirm lower stability of the tear film in the treated eye. The possible contribution of preservative agents in antiglaucomatous preparations to the development of instability of the tear film has been repeatedly demonstrated [14,15,19,26,34].

At present, considerable attention is being focused also on the influence of ocular surgery on homeostasis of the ocular surface and the development of symptoms of DES. Despite the fact that the results are not unequivocal, an increased incidence of subjective and objective symptoms of DES has been described following glaucoma operations, after cataract surgery and after pars plana vitrectomy [15-17,47-53]. Our results thus may document not only the adverse effect of locally applied medications, but may also concern the consequences of previous surgical procedures on the affected eye. A limitation of our study is also the small number of patients and the different primary pathology, which is due to the fact that the incidence of unilateral paediatric glaucoma is very rare.

Despite this, our results support the current recommendations, which emphasise that the aim of modern glaucoma therapy, in addition to sufficient reduction of IOP and prevention of the progression of damage to sight, is also an endeavour to reduce the adverse effects of long-term therapy. This especially concerns limiting the content of preservative agents in drops [2,3,6,14,54,55]. Until 2009, only one antiglaucomatous drug without preservative agents was available in the Czech Republic [56,57]. Since that time there has been a pronounced expansion in the availability of preparations without preservative agents. In the choice of therapy, especially for paediatric patients, it is necessary to remember that patients diagnosed with glaucoma at an early age will use local therapy for a long period of time, and in addition its adverse effects may be further potentiated by changes triggered by surgical procedures. Even relatively small changes to the surface of the treated eye in our cohort of paediatric patients point to the risk of development of affliction of the ocular surface du-

ring the subsequent course of life, and accent the need for the choice of the most sparing preparation. At the same time, it is necessary to reckon with a higher risk of development of symptoms of DES in the case of indication of further surgical procedures.

CONCLUSION

In the presented study, we observed the influence of antiglaucoma therapy on the development of symptoms of DES in patients with unilateral paediatric primary or secondary glaucoma, and the results of the examinations were compared with the values in the other, healthy eye. In the treated eye we demonstrated statistically significant

ly lower CET, lower values of TBUT, and the surface of the treated eyes was more markedly stained with fluorescein. Changes of osmolarity of the tear film in the treated eyes, values of the Schirmer test and the size of the lower tear meniscus area were not statistically significant, and were considerably variable. The results confirm changes of the ocular surface and tear film in these patients, which may be triggered by the adverse effects of chronically applied antiglaucoma therapy, or may be the consequence of an undergone surgical procedure. From the perspective of minimising these adverse effects, it is suitable to focus increased attention in clinical practice to the choice of pharmaceutical preparation, especially with regard to the content of preservative agents.

LITERATURE

- Papadopoulos M, Khaw PT. Childhood glaucoma. In: Taylor D, Hoyt CS. *Pediatric Ophthalmology and Strabismus*. 5th ed. New York: Elsevier Saunders; 2014:458–71.
- Fechtnner RD, Godfrey DG, Budenz D, Stewart JA, Stewart WC, Jasek MC. Prevalence of ocular surface complaints in patients with glaucoma using topical intraocular pressure-lowering medications. *Cornea*. 2010;29:618–621.
- Jaenen N, Baudouin C, Pouliquen P, Manni G, Figueiredo A, Zeyen T. Ocular symptoms and signs with preserved and preservative-free glaucoma medications. *Eur J Ophthalmol*. 2007;17:341–349.
- Leung EW, Medeiros FA, Weinreb RN. Prevalence of ocular surface disease in glaucoma patients. *J Glaucoma*. 2008;17:350–355.
- Mastropasqua R, Agnifili L, Mastropasqua L. Structural and Molecular Tear Film Changes in Glaucoma. *Curr Med Chem*. 2019;26:4225–4240.
- Zhang X, Vadoothker S, Munir WM, Saeedi O. Ocular Surface Disease and Glaucoma Medications: A Clinical Approach. *Eye Contact Lens*. 2019;45:11–18.
- Craig JP, Nichols KK, Akpek EK et al. TFOS DEWS II Definition and Classification Report. *Ocul Surf*. 2017;15:276–283.
- Bron AJ, de Paiva CS, Chauhan SK et al. TFOS DEWS II pathophysiology report. *Ocul Surf*. 2017;15:438–510.
- Valente C, Lester M, Corsi E, Rolando M. Symptoms and signs of tear film dysfunction in glaucomatous patients. *J Ocul Pharmacol Ther*. 2011;27:281–285.
- Anwar Z, Wellik SR, Galor A. Glaucoma therapy and ocular surface disease: current literature and recommendations. *Curr Opin Ophthalmol*. 2013;24:136–143.
- Stewart WC, Stewart JA, Nelson LA. Ocular surface disease in patients with ocular hypertension and glaucoma. *Curr Eye Res*. 2011;36:391–398.
- Výborný P, Sičáková S, Veselá Flórová Z. Konzervační činidla – denní dávka benzalkonium chloridu v léčbě glaukomu z pohledu pacienta [Preservative substances - the daily dose of benzalkonium chloride in glaucoma treatment from the patients point of view]. *Cesk Slov Oftalmol*. 2014;70:95–97.
- Baudouin C, Labbe A, Liang H, Pauly A, Brignole-Baudouin F. Preservatives in eyedrops: the good, the bad and the ugly. *Prog Retin Eye Res*. 2010;29:312–334.
- Pflugfelder SC, Baudouin C. Challenges in the clinical measurement of ocular surface disease in glaucoma patients. *Clin Ophthalmol*. 2011;5:1575–1583.
- Lee SY, Wong TT, Chua J, Boo C, Soh YF, Tong L. Effect of chronic anti-glaucoma medications and trabeculectomy on tear osmolarity. *Eye (Lond)*. 2013;27:1142–1150.
- Kato K, Miyake K, Hirano K, Kondo M. Management of Postoperative Inflammation and Dry Eye After Cataract Surgery. *Cornea*. 2019;38 Suppl 1:S25–S33.
- Elksnis E, Lace I, Laganovska G, Erts R. Tear osmolarity after cataract surgery. *J Curr Ophthalmol*. 2018;31:31–35.
- Methodologies to diagnose and monitor dry eye disease: report of the Diagnostic Methodology Subcommittee of the International Dry Eye Workshop (2007). *Ocul Surf*. 2007;5:108–152.
- Wong ABC, Wang MTM, Liu K, Prime ZJ, Danesh-Meyer HV, Craig JP. Exploring topical anti-glaucoma medication effects on the ocular surface in the context of the current understanding of dry eye. *Ocul Surf*. 2018;16:289–293.
- Fogagnolo P, Torregrossa G, Tranchina L et al. Tear Film Osmolarity, Ocular Surface Disease and Glaucoma: A Review. *Curr Med Chem*. 2019;26:4241–4252.
- Mlčáková E, Mlčák P, Karhanová M, Langová K, Marešová K. Hodnocení očního povrchu u pacientů léčených analogy prostaglandinů s ohledem na obsaženou konzervační látku [Ocular Surface Evaluation in Patients Treated with Prostaglandin Analogues Considering Preservative Agent]. *Cesk Slov Oftalmol*. 2016;72:120–127.
- Sullivan BD, Whitmer D, Nichols KK et al. An objective approach to dry eye disease severity. *Invest Ophthalmol Vis Sci*. 2010;51:6125–6130.23.
- Tomlinson A, Khanal S, Ramaesh K, Diaper C, McFadyen A. Tear film osmolarity: determination of a referent for dry eye diagnosis. *Invest Ophthalmol Vis Sci*. 2006;47:4309–4315.
- Versura P, Profazio V, Campos EC. Performance of tear osmolarity compared to previous diagnostic tests for dry eye diseases. *Curr Eye Res*. 2010;35:553–564.
- Potvin R, Makari S, Rapuano CJ. Tear film osmolarity and dry eye disease: a review of the literature. *Clin Ophthalmol*. 2015;9:2039–2047.
- Labbe A, Terry O, Brasnu E, Van Went C, Baudouin C. Tear film osmolarity in patients treated for glaucoma or ocular hypertension. *Cornea*. 2012;31:994–999.
- Erb C, Gast U, Schremmer D. German register for glaucoma patients with dry eye. I. Basic outcome with respect to dry eye. *Graefes Arch Clin Exp Ophthalmol*. 2008;246:1593–1601.
- Amparo F, Jin Y, Hamrah P, Schaumberg DA, Dana R. What is the value of incorporating tear osmolarity measurement in assessing patient response to therapy in dry eye disease? *Am J Ophthalmol*. 2014;157:69–77 e62.
- Khanal S, Millar TJ. Barriers to clinical uptake of tear osmolarity measurements. *Br J Ophthalmol*. 2012;96:341–344.
- Mahelková G, Veselá V, Seidler Štangová P, et al. Osmolarita slz u pacientů s těžkým syndromem suchého oka před a po aplikaci autologního séra. Porovnání s hodnotami zdravých dobrovolníků [Tear Osmolarity in Patients with Severe Dry Eye Syndrome Before and After Autologous Serum Treatment: a Comparison with Tear Osmolarity in Healthy Volunteers]. *Cesk Slov Oftalmol*. 2015;71:184–188.
- Szalai E, Berta A, Szekanecz Z, Szucs G, Modis L, Jr. Evaluation of tear osmolarity in non-Sjogren and Sjogren syndrome dry eye patients with the TearLab system. *Cornea*. 2012;31:867–871.
- Halkiadakis I, Kontadakis GA, Tsiakou D, Patsea E, Mitropoulos P, Kandarakis AS. Effect of Glaucoma Medication in Tear Film Osmolarity of Patients Without Symptoms of Ocular Discomfort. *J Ocul Pharmacol Ther*. 2015;31:330–334.
- Gomes JAP, Azar DT, Baudouin C et al. TFOS DEWS II iatrogenic report. *Ocul Surf*. 2017;15:511–538.
- Cvenkel B, Stunf S, Srebotnik Kirbis I, Stojan Flezar M. Symptoms and signs of ocular surface disease related to topical medication in patients with glaucoma. *Clin Ophthalmol*. 2015;9:625–631.

35. Chen W, Li Z, Hu J et al. Corneal alternations induced by topical application of benzalkonium chloride in rabbit. *PLoS One*. 2011;6:e26103.
36. Clouzeau C, Godefroy D, Riancho L, Rostene W, Baudouin C, Brignole-Baudouin F. Hyperosmolarity potentiates toxic effects of benzalkonium chloride on conjunctival epithelial cells in vitro. *Mol Vis*. 2012;18:851–863.
37. Pisella PJ, Debbasch C, Hamard P et al. Conjunctival proinflammatory and proapoptotic effects of latanoprost and preserved and unpreserved timolol: an ex vivo and in vitro study. *Invest Ophthalmol Vis Sci*. 2004;45:1360–1368.
38. Xiong C, Chen D, Liu J et al. A rabbit dry eye model induced by topical medication of a preservative benzalkonium chloride. *Invest Ophthalmol Vis Sci*. 2008;49:1850–1856.
39. Cennamo G, Montorio D, Del Prete S, Del Prete A, Cennamo G. Anterior-Segment Optical Coherence Tomography and Scanning Electron Microscopy to Evaluate Corneal Epithelial Changes in Patients Undergoing Glaucoma Therapy. *Cornea*. 2018;37:1522–1526.
40. Montorio D, Cennamo G, Breve MA et al. Evaluation of corneal epithelial thickness in glaucomatous patients using anterior-segment optical coherence tomography. *J Biophotonics*. 2020;13:e201900095.
41. Cui X, Hong J, Wang F et al. Assessment of corneal epithelial thickness in dry eye patients. *Optom Vis Sci*. 2014;91:1446–1454.
42. Fabiani C, Barabino S, Rashid S, Dana MR. Corneal epithelial proliferation and thickness in a mouse model of dry eye. *Exp Eye Res*. 2009;89:166–171.
43. Mahelkova G, Filous A, Odehnal M, Cendelin J. Corneal changes assessed using confocal microscopy in patients with unilateral buphthalmos. *Invest Ophthalmol Vis Sci*. 2013;54:4048–4053.
44. Martone G, Frezzotti P, Tosi GM et al. An in vivo confocal microscopy analysis of effects of topical antiglaucoma therapy with preservative on corneal innervation and morphology. *Am J Ophthalmol*. 2009;147:725–735 e721.
45. Agnifili L, Brescia L, Scatena B et al. Tear Meniscus Imaging by Anterior Segment-Optical Coherence Tomography in Medically Controlled Glaucoma. *J Glaucoma*. 2020;29:374–380.
46. Shimazaki J, Hanada K, Yagi Y et al. Changes in ocular surface caused by antiglaucomatous eyedrops: prospective, randomised study for the comparison of 0.5% timolol v 0.12% unoprostone. *Br J Ophthalmol*. 2000;84:1250–1254.
47. Tong L, Hou AH, Wong TT. Altered expression level of inflammation-related genes and long-term changes in ocular surface after trabeculectomy, a prospective cohort study. *Ocul Surf*. 2018;16:441–447.
48. Gonzalez-Mesa A, Moreno-Arrones JP, Ferrari D, Teus MA. Role of Tear Osmolarity in Dry Eye Symptoms After Cataract Surgery. *Am J Ophthalmol*. 2016;170:128–132.
49. Ishrat S, Nema N, Chandravanshi SCL. Incidence and pattern of dry eye after cataract surgery. *Saudi J Ophthalmol*. 2019;33:34–40.
50. Hanyuda A, Ayaki M, Tsubota K, Negishi K. Discrepancies in Persistent Dry Eye Signs and Symptoms in Bilateral Pseudophakic Patients. *J Clin Med*. 2019;8.
51. Lam J, Wong TT, Tong L. Ocular surface disease in posttrabeculectomy/mitomycin C patients. *Clin Ophthalmol*. 2015;9:187–191.
52. Sato T, Koh S, Yasukura YI et al. Surgical Factors Affecting Changes in Ocular Surface Dynamics in the Early Postoperative Period After 25-Gauge Vitrectomy. *Eye Contact Lens*. 2019;45:254–259.
53. Lee JH, Na KS, Kim TK, Oh HY, Lee MY. Effects on ocular discomfort and tear film dynamics of suturing 23-gauge pars plana vitrectomies. *Arq Bras Oftalmol*. 2019;82:214–219.
54. Broadway DC, Grierson I, O'Brien C, Hitchings RA. Adverse effects of topical antiglaucoma medication. I. The conjunctival cell profile. *Arch Ophthalmol*. 1994;112:1437–1445.
55. Karhanová M, Mlčák P, Fryšák Z, Marešová K. Účinnost a snášenlivost tafluprostu 0,0015% bez konzervačních látek v léčbě glaukomu a oční hypertenze [Ocular Surface Evaluation in Patients Treated with Prostaglandin Analogues Considering Preservative Agent]. *Cesk Slov Oftalmol*. 2012;68:150–155.
56. Mlčák P, Karhanová M, Marešová K. Konzervativní léčba glaukomu. *Prakt lékař*. 2009;5:22–25.
57. Liehneová I. Farmakoterapie glaukomu [Glaucoma medical therapy]. *Cesk Slov Oftalmol*. 2010;66:155–158.