proLékaře.cz | 2.2.2026

MAGNETIC RESONANCE STRENGTH 1.5T – POSSIBILITIES FOR OPTIC NERVE IMAGING

[1, 3]Hanzlíková P., [2, 3]Chmelová J.

[1] MR department, Sagena s.r.o., Frýdek-Head: MUDr. Pavla Hanzlíková
[2]Radiology and Imaging Methods, Ostrava City Hospital,
Head: doc. MUDr. Jana Chmelová, Ph.D.,
[3]Department of Radiology, Faculty of Medicine, Palacký University Olomouc, Head prof. MUDr. Miroslav Heřman, Ph.D.

This article follows on from the lecture: Hanzlíková P., Chmelová J. :MR imaging of the optic nerve, presented at the 24th anniversary of the Czech Ophthalmology Society in Olomouc, 22-24 September 2016

The authors of the study declare that no conflict of interest exists in the compilation, theme and subsequent publication of this professional communication, and that it is not supported by any pharmaceuticals company. This declaration relates to all co-authors.



MUDr. Pavla Hanzlíková
MR oddělení Sagena
8. Pěšího pluku 2450
738 01 Frýdek-Místek
e-mail: hanzlikova@sagena.cz

SUMMARY

Due to the increased availability of MRI, this modality is the first choice for patients with a suspected pathology of the optic nerve, chiasm and optic tracts. Magnetic resonance imaging allows to evaluate the optic nerve itself as well as the gain or atrophy, its focal changes; it also allows detailed views of the surrounding structures such as vagina of the optic nerve and the mutual ratio between the full thickness of the nerve and the vagina, and the nerve itself. MR method uses a tissue contrast of an adipose tissue structures to a detailed imaging of the orbit. These data can play an important role not only in the diagnosis of the diseases with ophthalmic symptoms, but also in the diagnosis of the diseases of the nervous system. We are presenting a comprehensive overview of basic sequences used to show the optic nerve and the structures of the orbit as well as highlighting the benefits of their use and emphasizing their limitations. Imaging of the optic nerve and eye sockets may be standardized, and thus make the assessment easier for the following examinations that should be ideally performed using the same equipment and the same protocol display. The issue of imaging on the display unit with the strength of 1.5 Tesla is discussed; it is a machine that is largely represented across the Czech Republic.

Key words: magnetic resonance imaging, scanner strength of 1.5 T, optic nerve, optic path, vagina of optic nerve

Čes. a slov. Oftal., 73, 2017, No. 1, p. 34–39

INTRODUCTION

Diagnosis of morphological changes to the structure of the optic nerve is a necessary component of identifying pathologies not only of the optic nerve, but also other ocular and neurological pathologies.

Imaging of the 1st segment is the domain of ophthalmology, for the imaging of further segments it is essential to perform magnetic resonance.

An essential role in the diagnostic algorithm is played by CT (computed tomography), which assists in the diagnosis of calcifications and changes to bone structures.

Examination of the optic nerves is preceded by imaging of the brain by the standard protocol.

An essential component of examination and preparation for examination is the completion of an application form by the indicating doctor. It is essential to provide a brief communication of the patient's anamnesis and the results of examinations to date, but in particular it is necessary to focus on the clinical issue. The modality of MR enables various configurations of the imaging protocol, and this is modified depending on the sought cause of clinical complaints.

Optic nerve

The optic nerve is classified among the cranial nerves, but is not a genuine cranial nerve – it is a promontory of the central nervous system, a further bipolar neuron of the CNS is located in the retina. The sheath of the optic nerve is formed by oligodendrocytes, and not by Schwann cells [3, 8].

The centripetal fibres from the neurons in the retina converge on the disc of the optic nerve, pass through the fine ligament meshwork of the lamina cribrosa centripetally and form themselves into the optic nerve.

The optic nerve is divided into 4 segments [7]:

1. **intraocular** segment: the nerve fibres converge centripetally from the retina toward the disc and the lamina cribrosa
2. **intraorbital** segment: segment of the nerve inside the intraconal space, the nerve is surrounded by the dura mater, and is linked with the subarachnoid spaces of the brain
3. **intracanalicular** segment: segment between the fibrous ring of the cone up to the optic canal
4. **intracranial or prechiasmatic** segment: segment in the central cranial cavity up to the chiasma

There follows the segment of the **optic chiasma** and **optic tract** – the fibres originating from the temporal part of the retinal fibres do not cross, the fibres from the nasal part

proLékaře.cz | 2.2.2026

cross – a part of the fibres transmits information ipsilaterally temporally and contralaterally nasally from each optic nerve – these fibres continue as the "optic tract" up to the corpus geniculatum laterale thalamus. The continue centripetally as branches of **optic radiation**.

Imaging of first segment of optic nerve

Imaging of the intraocular segment of the optic nerve is the domain of ophthalmology. It is important to evaluate the number of fibres of the optic nerve, their thickness and the arrangement of the individual layers peripapillary. For this purpose it is possible to use laser methods, as well as methods based on the use of visible light [4, 7, 9].

Imaging of 2nd to 4th segments of optic nerve by magnetic resonance

Imaging of the optic nerve should always be preceded by an examination of the brain by the standard protocol.

Upon imaging the orbits as structures with a high fat content, we make use especially of sequences with suppression of the fat signal.

MR sequences

In the Czech Republic instruments with a field strength of 1.5 Tesla are most frequently used.

It is essential to start out from the technical limitations of the field strength, which enables us to examine the optic nerves by a protocol ensuring layers with a width of 3 mm. With regard to the limitation of the field strength, it is not possible to perform certain new sequences on these instruments (e.g. DIR sequence can be produced on instruments with a strength of 3Tesla).

An essential component of imaging of the orbits and the optic nerve is standard imaging of the brain [6]. The authors consider T2 TSE, Flair, DWI (b0, b 1000, ADC), SWI in 5 mm transverse cross-sections, sagittal T1 SE sequence with a sectional strength of 5 m supplemented by a coronary level in T2 TSE echo to represent a sufficient protocol for brain imaging in the basic protocol.

There then follows imaging targeted at the orbits.

Native sequences

We produce native sequences (sequences without the use of contrast substances) on an instrument with a field strength of 1.5T in a maximum 3 mm width of the layer.

First applied are sequences in **T2 TSE** W with fat suppression.

The next sequence may be native **T1 SE** sequences, which utilise a natural tissue contrast between the high T1 fat signal and low liquid signal.

A sequence suitable for evaluating the content of the optic sheaths of the cerebrospinal fluid and the thickness of the actual optic nerve as against the total width of the nerve and sheath is the sequence **T2 TSE 3D** from the group of gradient sequences (CISS - Siemens, FFE - Philips, FIESTA-C - GE, SSFP - Toshiba). This method has its drawback in pronounced sensitivity to artefacts especially in the proximity of the

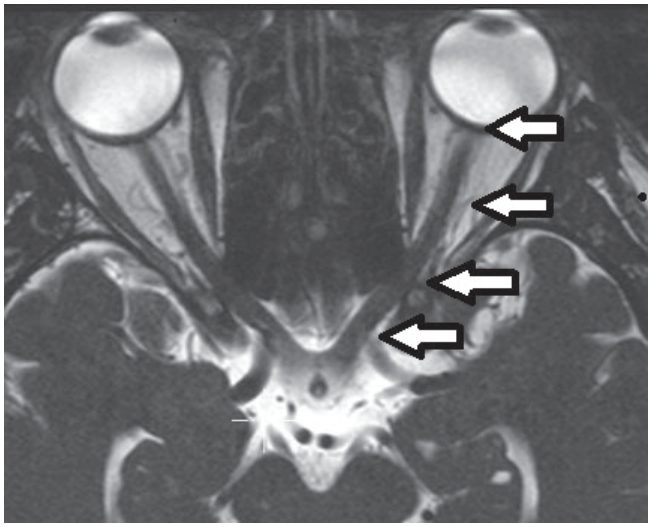

Fig.1 Portions of optic nerve in T2 W in transversal plane (ciss).

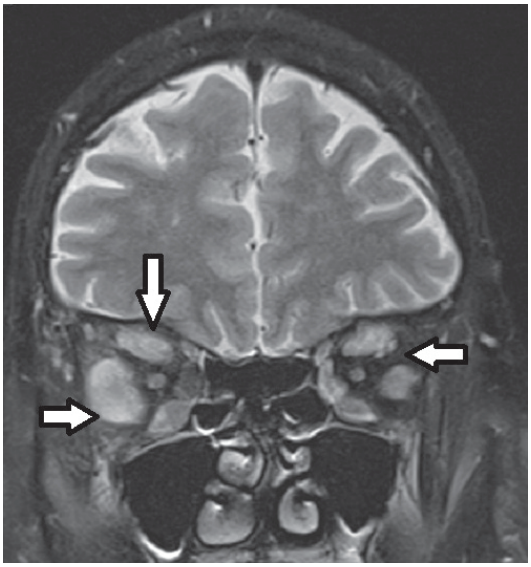

Fig. 2 Coronary T2 images with fat suppression inflammatory infiltration of extraocular muscles, typical image of endocrine ophthalmopathy.

Table 1 Sections of optic nerve and preferred modality of imaging.

Optic nerve – total length 47-50 mm		*Imaging*
1. Intraocular segment	1 mm	OCT, HDR, GDX
2. Intraorbital segment	25–30 mm	MR
3. Intracanalicular segment	5–9 mm	MR
4. Intracranial segment	10-16 mm	MR

proLékaře.cz | 2.2.2026

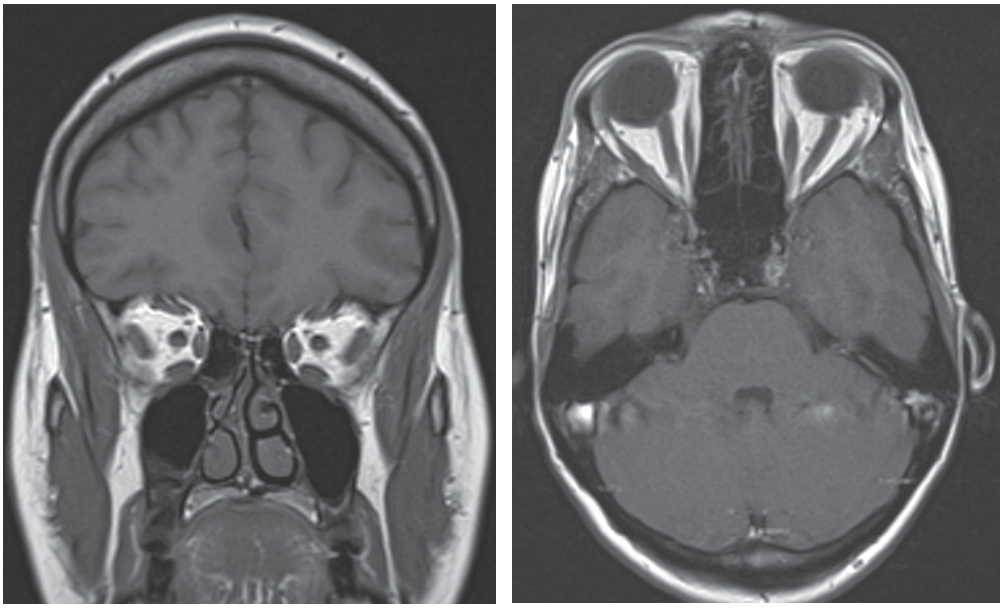

Fig. 3a, 3b T1 W scan of optic nerve in coronal and transversal plane. A normal result.

oral cavity (dental braces, tooth replacements).

The group of native sequences is supplemented by diffuse weighted images **DWI**, and it is necessary to produce ADC maps. These sequences are appropriate for assessment of free diffusion of water molecules on the principle of Brownian motion – they enable us to assess the presence of ischemia, edema, presence of cellular purulence and malignant tissue. This sequence is composed of two types of images – a series of images with increasing suppression of the tissue signal and progressive accentuation of breach of free diffusion. The second series of images is formed by logarithms of the original images – ADC maps, i.e. maps of the apparent diffusion coefficient. Again it is necessary to consider use in the presence of artefacts in the oral cavity.

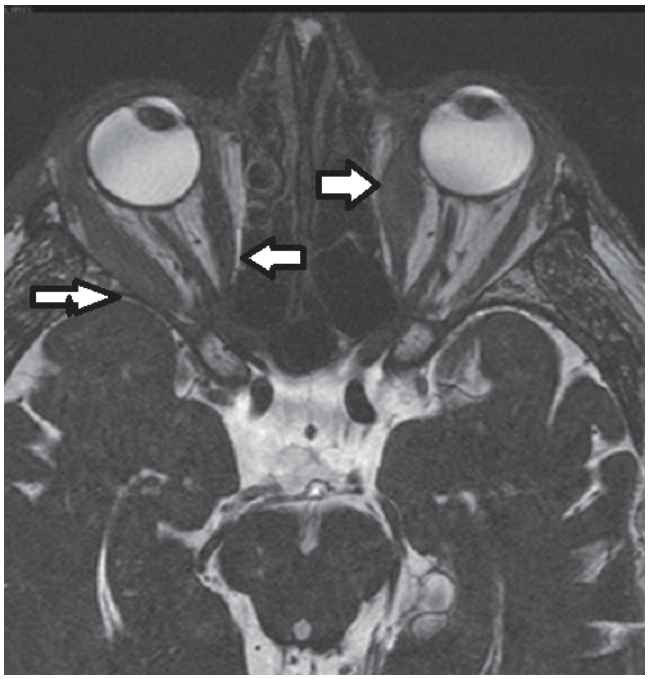

Fig. 4 T2 CISS (contructive interference in steady state) technic in transversal plane with inflammation of ocular muscles. Dominated disability rectus lateralis right, left medial rectus. The endocrine ophthalmopathy.

Post-contrast sequences

Use of contrast substances enables a complex evaluation of pathological changes of the signal of natively demonstrated afflictions of the nerve or sheath.

The basic sequences following application of a contrast substance are **T1 SE** sequences, either with fat suppression or retention of a high fat signal [1, 5, 6].

It is possible to use **T1 SE** sequences with magnetisation transfer. In addition to evaluation of saturation of the optic nerve, these sequences are also a useful tool for evaluating the content of the central vein.

A further option is to use sequences from the group of gradient echo (**GRE**), ideally with fat suppression [8, 9]. These sequences enable 3D imaging and production of reconstructions on any level. Here also it is necessary to note sensitivity to artefacts.

Supplementary examinations

A post-contrast GRE scan with fat suppression and MPR (multiplanar reconstruction) enables evaluation of the condition of the cavernous sinus, the area of the sella turcica, meninges, and it is possible to use highlighting of the content of blood vessels to advantage.

In the case of suspicious of carotido-cavernous fistulas, native angiography of the brain arteries by the time-of-flight method – **TOF** – highlighting of flow in the blood vessel is indicated [8, 9].

In order to exclude fistulas it is possible to use angiography with the use of a contrast substance, in which we are ca-

proLékaře.cz | 2.2.2026

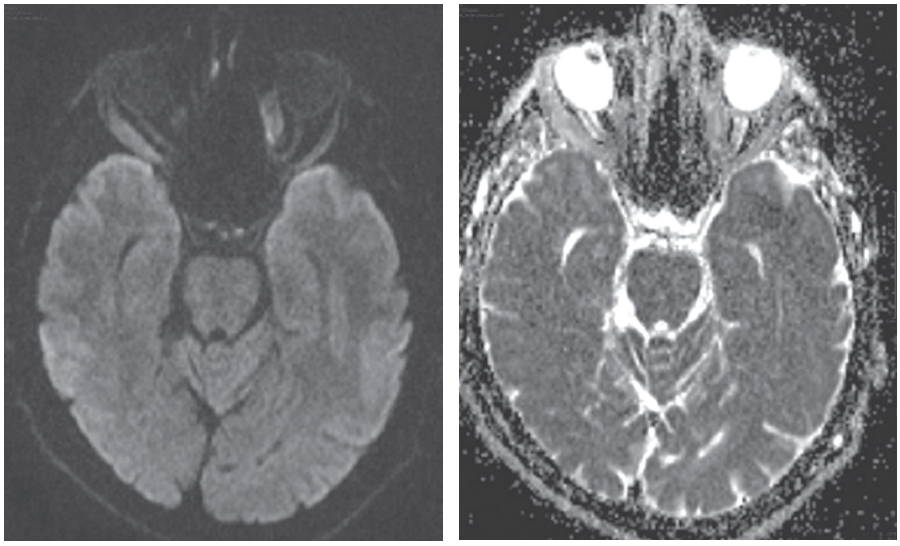

Fig. 5a, 5b Diffusion-weighted images of inflammation of ocular muscles in high diffusion weighted image (5a) and ADC map (5b). The same patient as in figure 4.

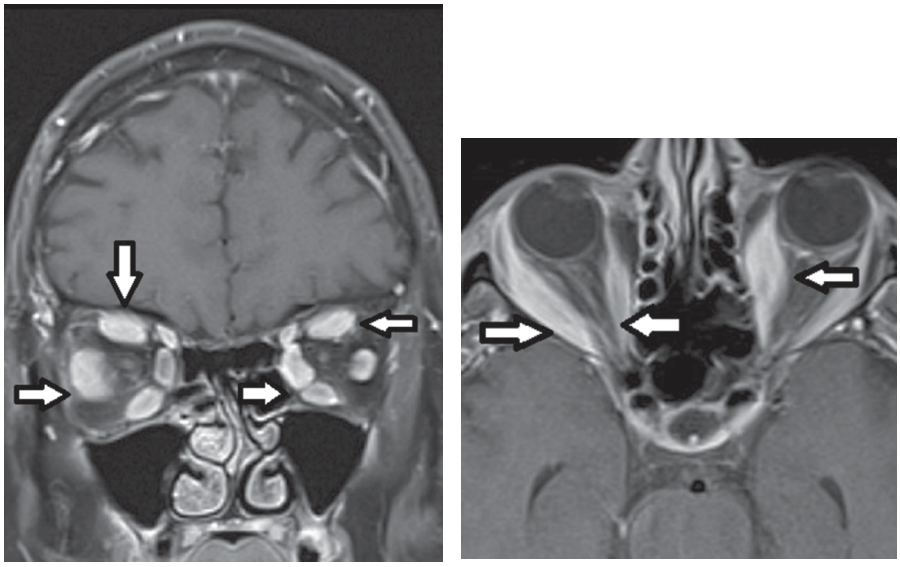

Fig. 6a, 6b T1 W scans with fat suppression with application contrast agent in coronal and transversal plane. It is obvious pathological enhancement of ocular muscles. The same patient as in figure 4.

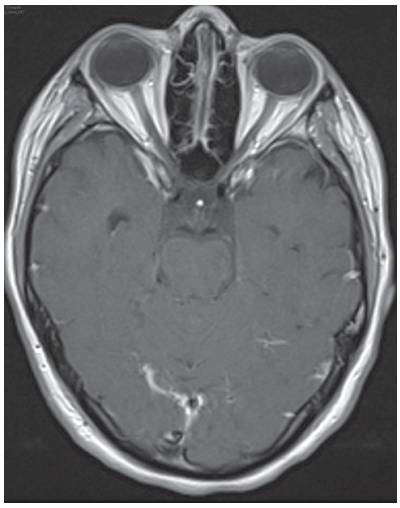

Fig. 7 Transversal plane in T1 W with magnetic transfer. A normal result.

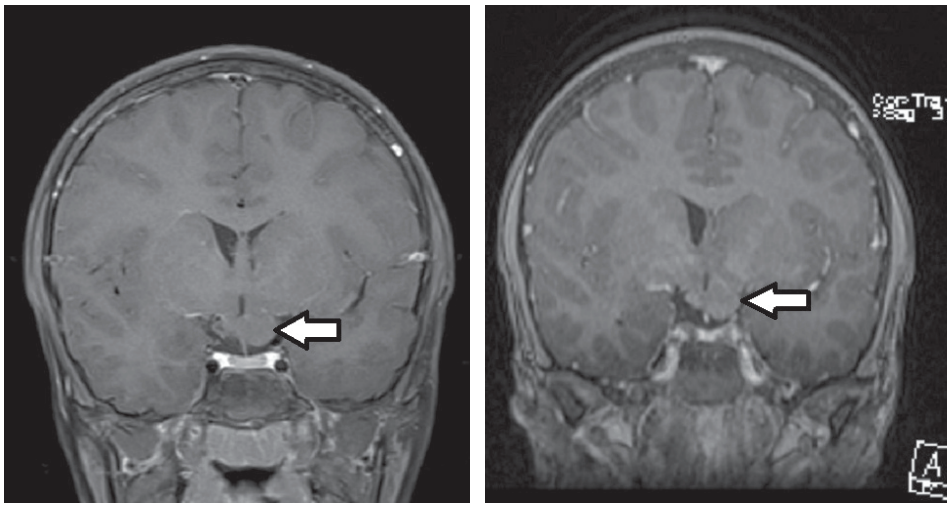

Fig. 8a, 8b Compared T1 SE coronary scan (fig. 8a) and T1 GRE (Gradient Recalled Echo) - coronal multiplanar reconstruction - with fat suppression (fig. 8b). The optic chiasm glioma.

proLékaře.cz | 2.2.2026

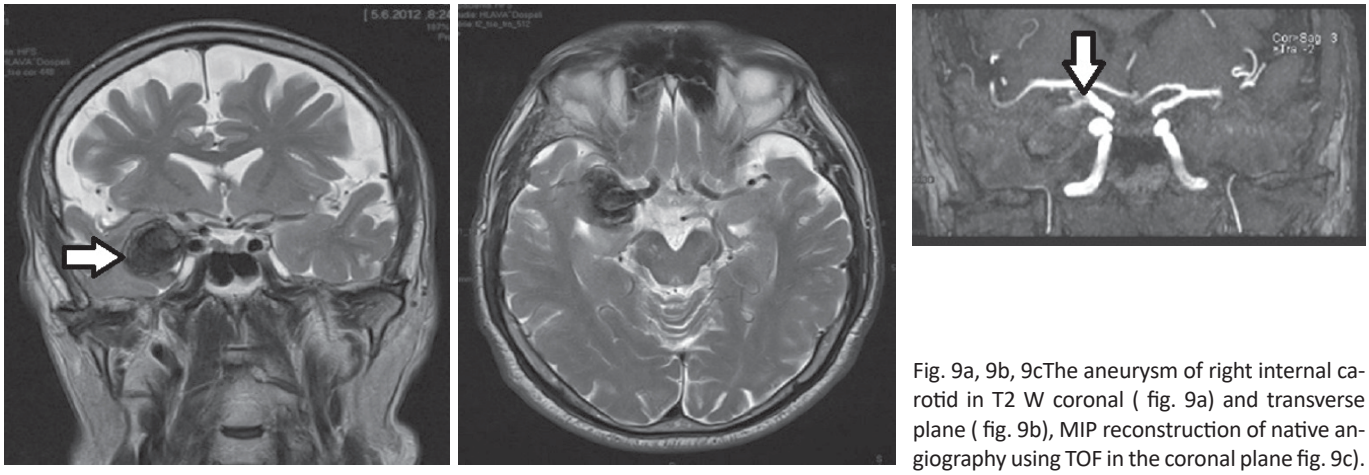

Fig. 9a, 9b, 9cThe aneurysm of right internal carotid in T2 W coronal (fig. 9a) and transverse plane (fig. 9b), MIP reconstruction of native angiography using TOF in the coronal plane fig. 9c).

pable of displaying in time and assessing the passage of the contrast substance through the individual vascular structures - **CE-MRA (contrast MR angiography)**. If we evaluate passage through a structure other than a vascular structure, the term used is **dynamic contrast examination**.

DISCUSSION

Imaging of the optic nerve using MR provides us with a quality tool for evaluating deposit changes of the optic nerve – changes which are both natively detectable and changes detectable following the administration of a contrast substance [1, 7].

We are capable of assessing the width of the nerve itself also in comparison with the other side. Comparison is the basis of evaluation of atrophy or hypertrophy of the optic nerve. It is necessary also to evaluate the width of the content of the sheath of the optic nerve as against

Table 2 The basic differencial diagnosis of optic nerve hypertrophy and atrophy.

Changes of width of optic nerve	
Hypertrophy of optic nerve	*Atrophy of optic nerve*
Optic neuritis	**Demyelinating disease - RSM, m. Devic**
Glioma of optic nerve	**Post-inflammatory atrophy**
Meningeoma of sheath of optic nerve	**Pressure or traction atrophy**
Intracranial hypertension	**Consecutive atrophy - atrophy in retinal pathologies**
Leukemic infiltration, infiltration of lymphoma	**Vascular atrophy**
Sarcoidosis	**Metabolic atrophy**
Morbus Graves	**Post-traumatic neuropathy**
Central retinal vein occlusion	**Hereditary atrophy – m. Behr, Leber optic atrophy**
Hemangioblastoma	
Haemorrhage	

Table 3 Increasing intensity of optic nerve in T2W.

Causes of increase in T2 signal optic nerve – native assessment	
Non-infectious causes	*Infectious causes*
RSM - most common	**Lyme disease**
Neuromyelitis optica - morbus Devic	**Toxoplasmosis**
Sarcoidosis	**HIV**
ADEM – acute disseminated encephalomyelitis	**Varicella and herpes virus**
SLE – systemic lupus erythematosus	
Affliction by toxins - metabolic origin	
Post-radiation changes	

proLékaře.cz | 2.2.2026

Table 4 Pathological processes in middle fossa with failure of vision.

Pathological processes in middle cranial fossa - rating with intravenous contrast administration	
Cavernous sinus thrombosis	**intravenous contrast**
Meningitis	**intravenous contrast**
Expansion of the middle cranial fossa and surroundings	**intravenous contrast wiht angiography**
Meningeoma en plaque	**intravenous contrast**
Infiltration meninges of the brain upon blood and tumour diseases	**intravenous contrast**
Carotid cavernous fistula - direct and indirect - optimal dynamic display time	**intravenous contrast, angiography optimally with dynamic contrast enhancement**

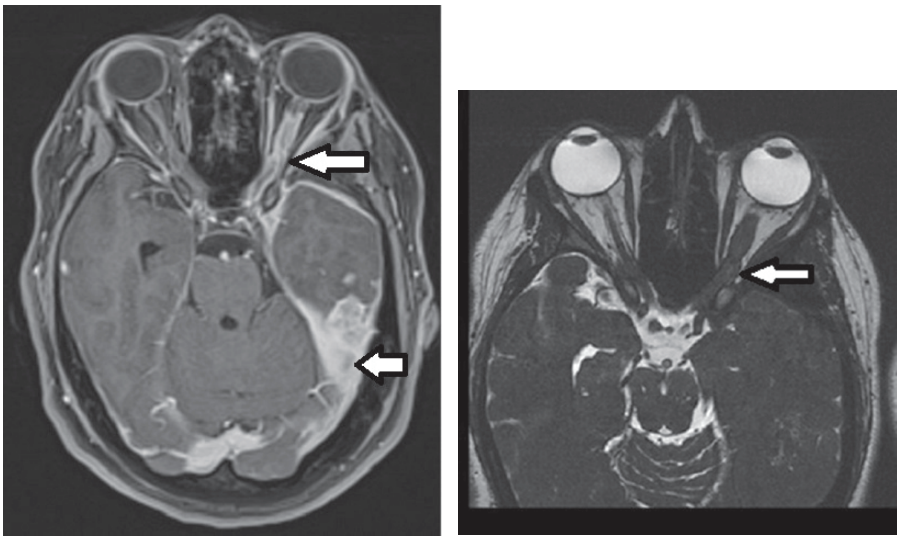

Fig. 10a, 10b Hypertrofic pachymeningitis of left hemisphere is hitting the optic nerve sheaths T1W transversal scan with fat supression (fig. 10a) and in T2 CISS scan in the transverse plane (fig. 10b).

the overall width of the nerve and sheath, which is not possible without correlation with the condition of the SA space along the brain [3, 4].

Separate attention should undoubtedly be devoted to the sheath of the optic nerve within the scope of the orbit up to the optic canal, by which direction it passes centripetally into the meninges [3, 4].

A component of examination of the optic nerves and orbits is always an examination of the brain and careful evaluation of the structures of the middle fossa, sella turcica, cavernous sinus or meninges on the cranial base [3, 8].

Examination of the vascular structures of the orbit and middle fossa is also essential.

CONCLUSION

Imaging of the optic nerve in the 2nd to 4th segments is the domain of magnetic resonance. MR is capable of assessing the thickness of the nerve, its structure with imaging of deposit changes, and assessing the nerve sheaths. It is capable of imaging in detail the chiasma, optic nerves and structures of the middle fossa.

The standard for examination of the orbit and optic nerves is imaging of the brain.

It is essential to ensure close co-operation with the indicating doctor, ideally an ophthalmologist, with the radio diagnostic technician.

LITERATURE

1. **Guy J. et al:** Enhancement and Demyelination of the Intraorbital Optic Nerve: Fat Suppression Magnetic Resonance Imaging. Ophthalmology, 1992; 713–7192.
2. **Greaney M. J. et al:** Comparison of Optic Nerve Imaging Methods to Distinguish Normal Eyes from Those with Glaucoma. Invest. Ophthalmol Vis Sci, 2002; 3(1): 140–145 .
3. **Foram G.:** Magnetic resonance imaging of optic nerve. Indian Radiol Imaging. 2015; Oct- Dec; 25(4): 421–438.
4. **Harbison H., Noble V.:** Using MRI of the optic nerve sheath to detect elevated intracranial pressure. Critical Care, 2008; 12: 181.
5. **Mangrum W. et al:** Duke Review of MRI Principles, Philadelphia, Elsevier Health Sciences, 2012, p. 278. ISBN 978-1-4557-0084-4.
6. **Mechl M., Tintěra J., Žižka J. et al.:** Protokoly MR zobrazování, Praha, Galén, 2014; s. 18–43. ISBN 978-80-7492-109-4.
7. **Miller D. H. et al:** Magnetic resonance imaging of the optic nerve in optic neuritis. Neurology February 1988; 38(2): p. 175.
8. **Montaleone P.:** The optic nerve: A clinical perspective. Univ West Ont Med J, 2010; 79: 37, 9.
9. **Trip S. Anand et al:** Optic nerve atrophy and retinal nerve fibre layer thinning following optic neuritis: Evidence that axonal loss is a substrate of MRI-detected atrophy. NeuroImage 2006; 31 (1): p. 286–293.