proLékaře.cz | 23.10.2026

Sudden death due to a rare brain tumor: An autopsy case

Eren B.[1], Türkmen N.[2], Çomunoglu N.[3], Öz B.[4], Şenel B.[5], Eren F.[6]

[1] *Council of Forensic Medicine of Turkey, Bursa Morgue Department, Bursa, Turkey*
[2] *Department of Forensic Medicine, Uludag University, Council of Forensic Medicine of Turkey, Bursa Morgue Department, Bursa, Turkey*
[3] *Dr Lütfi Kirdar Kartal Research and Training Hospital, Department of Pathology, Istanbul, Turkey*
[4] *Department of Pathology, Istanbul University Cerrahpasa Medical Faculty, Istanbul, Turkey*
[5] *Council of Forensic Medicine of Turkey, Istanbul, Turkey*
[6] *Department of Pathology, Sevket Yilmaz Public Hospital, Bursa, Turkey*

Case was presented in IAFS(International Association of Forensic Sciences) 18th Triennial Meeting, July 21–26, 2008, New Orleans, LA, USA.

SUMMARY
Sudden death in persons with intracranial neoplasms is a rare mechanism of death detected in the forensic autopsies. 10 years-old girl was brought to a local clinic death shortly after analgesic therapy for headache. Autopsy findings showed a large, solid cerebellar mass. Histological diagnosis was pilomyxoid astrocytoma, low-grade tumor with features alike to pilocytic astrocytomas. In this case report we present and discuss rare autopsy case of pilomyxoid astrocytoma from medicolegal point of view.

Keywords: sudden death – brain – pilomyxoid astrocytoma – autopsy

Náhlé úmrtí při vzácném mozkovém nádoru: Případ z pitvy

SOUHRN
Náhlé úmrtí osob s nitrolebním nádorem je při soudnělékařských pitvách málo častou příčinou smrti. 10-leté děvče bylo převezeno na místní kliniku mrtvé, krátce po analgetické léčbě pro bolesti hlavy. Pitevní nález prokázal rozsáhlou, solidní mozečkovou tkáň. Histologická diagnosa zněla: pilomyxoidní astrocytom, nízký stupeň nádoru s rysy podobnými piloidnímu astrocytomu.
V tomto sdělení je prezentován a diskutován řídký pitevní nález pilomyxoidního astrocytomu ze soudnělékařského hlediska.

Klíčová slova: náhlá smrt – mozek – pilomyxoidní astrocytom – pitva

Soud Lek 2012; 57(4): 60–61

Sudden death in a case with a brain neoplasm is rarely reported in medico legal literature (1). Pilomyxoid astrocytomas, newly described neoplasms, were identified as low-grade tumors with same features like pilocytic astrocytomas (2–7). But according recent reports, pilomyxoid astrocytomas had some different histological features and aggressive manner (4,8).

CASE REPORT

According to the document of death a 10 years-old girl was brought to the local clinic death after several week therapies for headache. The cause of death was unknown and forensic autopsy was mandated by prosecutor after investigation. A forensic autopsy was performed in Council of Forensic Medicine Bursa Morgue department. The family members stated that she had been medically evaluated in public hospital for the headache that has started two weeks ago, and it was administrated analgesic therapy. The victim body was 128 cm in height and 35 kg in weight. No traumatic marks were detected either on external or internal examination. During autopsy, brain dissection findings showed a large, solid, with myxoid cut surface enhancing 4,5x4 cm tumor mass involving cerebellum, with extension to hemispheres, the fourth ventricle and also invading the brain stem. The histological examination of the cerebellar mass.was performed. On microscopic evaluation of the tumor histological diagnosis was as a low-grade glioma consistent with pilomyxoid astrocytoma; monomorphous cytologic appearance, myxoid matrix and angiocentric cell arrangement were detected. Immunohistochemically, pilomyxoid astrocytoma was diffusely positive for GFAP and vimentin, but negative for chromogranin and synaptophysin. Macroscopic and microscopic examination of the internal organs was unremarkable, only lungs revealed edema. Investigation of the blood, urine, and organ specimens revealed none of the substances screened in systematic toxicological analysis. After autopsy the death was reported due to brain tumor invading the brain stem.

DISCUSSION

Sudden death incidence due to a brain tumor was reported in ranges from 0.16 to 3.2 %, with predominance of gliomas in the

✉ ***Correspondence address:***
Dr.Bülent Eren:
Council of Forensic Medicine of Turkey Bursa Morgue Department
Heykel, Osmangazi 16010, Bursa, Turkey
tel.: +90 224 222 03 47 fax: +90 225 51 70
e-mail: drbulenteren@gmail.com

proLékaře.cz | 23.10.2026

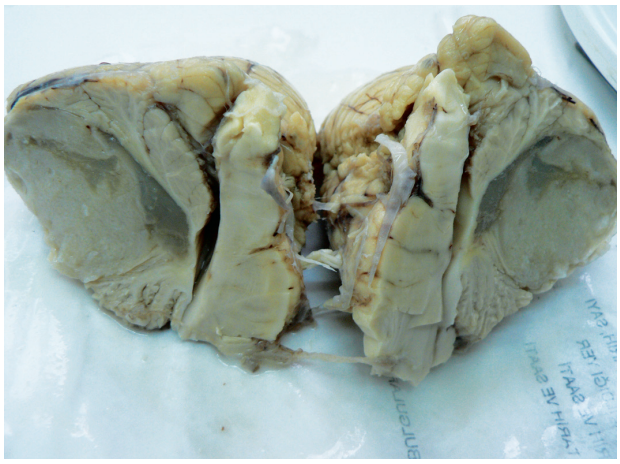

Fig 1. Macroscoppic apperance of the tumor

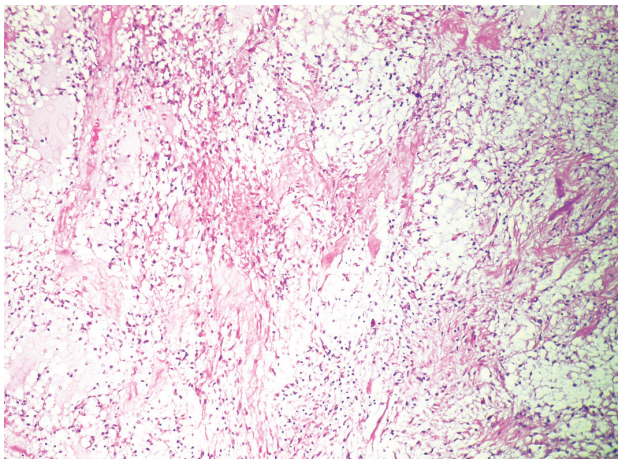

Fig 2. Myxoid matrix and angiocentric cell arrangement (H&E, x100)

review paper of Büttner et al (1). Pilomyxoid astrocytoma was described recently (2) as a glial neoplasm composed of piloid tumour cells lying within a rich myxoid background and tumor cells often show a significant angiocentric arrangement. The tumour was newly determined as a low-grade glioma and was reported as a type of pilocytic astrocytoma. (2–4). Pilomyxoid astrocytoma is a tumor of early childhood, but has been reported in older children like our case, who was 10 years-old girl. Physical signs and symptoms of tumor were related to mass effect. Major clinical signs in the early childhood are developmental delay and vomiting. In older children as presented in our case, headaches, nausea and disorientation were reported as the most frequent clinical manifestations (4). On radiologic investigation tumor was reported to appear as a properly well demarked mass in the hypothalamic region, with most distinctive imaging features as solid appearance and homogenous contrast-enhancement (5,6). The hypothalamic region was the most typical localization reported, but tumor we detected was located on cerebellum. The most important pathologic features of pilomyxoid astrocytoma include a monomorphous cytological character, myxoid matrix and angiocentric cell arrangement. Because most of these features can be detected, at least focally, in typical pilocytic astrocytoma, current pathologic practice prevents the diagnosis of pilomyxoid astrocytoma to those tumors that exhibit the characteristics in a non-uniform pattern (4,7,8). Histological appearance of pilomyxoid astrocytoma is a hypercellular and strikingly monomorphous neoplasm, composed by monomorphous bipolar cells in contrast to the often biphasic appearance that is characteristic of ordinary pilocytic astrocytoma. Pilomyxoid astrocytoma typically lacks Rosenthal bers and only exceptionally displays eosinophilic granular bodies. Mitotic gures may be seen but are not abundant. Immunohistochemically, pilomyxoid astrocytoma stains diffusely for GFAP and vimentin, but is negative for neuronal markers such as chromogranin and synaptophysin. (4,7). Some researches supported that the pilomyxoid astrocytoma histology was related with aggressive clinical behavior than pilocytic astrocytoma (3,4,7). Although most studies of pilomyxoid astrocytoma note the resemblance to pilocytic astrocytoma and suggest an astrocytic origin, on the other hand some others have declared ependymal origin (8). Sudden death due to undiagnosed primary intracranial tumors is rarely reported in forensic autopsy practice (1,9). The mechanism of death in the reported cases were tumor obstruction of cerebrospinal fluid outflow resulting in the usual complications as herniation phenomenon seen with increased intracranial pressure (9), besides Büttner et al also mentioned sudden hemorrhage into the tumoral mass (1). But in our case there were no specific signs of increased intracranial pressure, or tumor hemorrhage. We suggest that the possible mechanism of sudden death was associated with this slow-growing, aggressive neoplasm was tumor's location itself. Tumor was directly invading the brain stem, where were located the vital centers, leading to cardiopulmonary depression. In the literature review, the acceptance of pilomyxoid astrocytoma as a unique tumor entity is still unclear and without conclusion (2,3,4,7,8), but pilomyxoid astrocytoma, previously described in the pilocytic astrocytoma group, had different histological and clinical features, and these properties indicated the requirmet of pilomyxoid astrocytoma's registration as a different tumor type. In this paper we presented and discussed rare autopsy case of pilomyxoid astrocytoma, we aimed to provide information for clarification the properties of this interesting pediatric tumor, also to expose the cause of sudden death from medico legal point of view.

REFERENCES

1. **Büttner A, Gall C, Mall G, Weis S.** Unexpected death in persons with symptomatic epilepsy due to glial brain tumors: a report of two cases and review of the literature. *Forensic Sci Int* 1999; 100: 127–136.
2. **Tihan T, Fisher PG, Kepner JL, et al.** Pediatric astrocytomas with monomorphous pilomyxoid features and a less favorable outcome. *J Neuropathol Exp Neurol* 1999; 58: 1061–1068.
3. **Fernandez C, Figarella-Branger D, Girard N, et al.** Pilocytic astrocytomas in children: prognostic factors – a retrospective study of 80 cases. *Neurosurgery* 2003; 53: 544–553.
4. Komotar RJ, Burger PC, Carson BS, et al. Pilocytic and pilomyxoid hypothalamic/chiasmatic astrocytomas. *Neurosurgery* 2004; 54: 72–79.
5. **Arslanoglu A, Cirak B, Horska A, et al.** MR imaging characteristics of pilomyxoid astrocytomas. *Am J Neuroradiol* 2003; 24: 1906–1908.
6. **Cirak B, Horska A, Barker PB, Burger PC, Carson BS, Avellino AM.** Proton magnetic resonance spectroscopic imaging in pediatric pilomyxoid astrocytoma. *Childs Nerv Syst* 2005; 21: 404–409.
7. **Chikai K, Ohnishi A, Kato T, et al.** Clinico-pathological features of pilomyxoid astrocytoma of the optic pathway. *Acta Neuropathol (Berl)* 2004; 108: 109–114.
8. **Fuller CE, Frankel B, Smith M, et al.** Suprasellar monomorphous pilomyxoid neoplasm:an ultastructural analysis. *Clin Neuropathol* 2001; 20: 256–262.
9. Forensic Pathology Reviews, Volume 2 **Michael Tsokos** (Ed. & Series Ed.); Humana Press, New Jersey, 2004, pp 45–61