

# Clinical Profile and Surgical Outcomes in Brown Syndrome – A Retrospective Case Series

Singh Anupam<sup>1</sup>, Prakash Nandu<sup>1</sup>, Buch Pankti<sup>1</sup>,  
Choudhary Anue<sup>1</sup>, Kumar Barun<sup>2</sup>

<sup>1</sup>Department of Ophthalmology, All India Institute of Medical Sciences, Rishikesh, India

<sup>2</sup>Department of Cardiology, All India Institute of Medical Sciences, Rishikesh, India

Submitted to the editorial board: January 12, 2026

Accepted for publication: March 17, 2026

Available on-line: May 7, 2026

*All the above-enlisted authors declare that no conflict of interest exists in the compilation, theme, and subsequent publication of this professional communication, and that no pharmaceutical company supports it. The study has not been submitted to another journal and is not printed elsewhere, except for congress summaries and recommended procedures.*



Prof. Dr. Anupam Singh

Correspondence address:  
Ophthalmology Department  
AIIMS Rishikesh  
Uttarakhand  
India  
E-mail: dr.anupamsingh@gmail.com

## SUMMARY

**Aim:** To evaluate the clinical, sensory, and motor characteristics of patients with Brown syndrome treated at a tertiary health care center, with a focus on the long-term outcomes of conservative and surgical interventions.

**Material and Methods:** This retrospective case series evaluated 14 patients diagnosed with Brown syndrome. A comprehensive clinical assessment included a detailed history, best-corrected visual acuity, a prism cover test for primary position deviation, nine-gaze motility with quantitative elevation-in-adduction, fundus torsion, and sensory status. Of 14 patients, 11 had congenital Brown syndrome and 3 had acquired forms. Congenital cases were stratified by severity using standard criteria: mild (isolated elevation deficit in adduction with orthophoria; n = 4), moderate (downshoot in adduction with minimal/no primary deviation; n = 2), and severe (significant primary vertical deviation ± abnormal head posture; n = 5). Mild to moderate cases underwent observation with appropriate refractive correction, and acquired cases underwent etiology-specific management, which also included observation for the restrictive strabismus. Severe congenital cases (n = 5) underwent superior oblique chicken suture lengthening.

**Results:** Following a one-year follow-up, mild (n = 4) and moderate (n = 2) congenital cases remained stable without progression under conservative management, whereas acquired etiologies (n = 3) showed resolution after etiology-targeted management. Five patients with the congenital severe form achieved successful primary position alignment after superior oblique chicken suture lengthening, with improvements in objective torsion, abnormal head posture, and stereoacuity, without any adverse outcomes.

**Conclusion:** Most cases of Brown syndrome (64%) can be managed by adopting a conservative approach, depending on the etiology and severity. Only severe forms with significant primary position deviation require surgical intervention. Superior oblique chicken suture lengthening is a safe procedure that yields favorable long-term outcomes with minimal complications.

**Key words:** Brown syndrome, chicken suture, outcome, clinical profile

*Čes. a slov. Oftal., 82, 2026, No. x, p.*

## INTRODUCTION

Brown syndrome is a complex ocular motility disorder, presenting with restricted elevation of the affected eye in adduction, most often due to abnormalities involving the superior oblique (SO) tendon-trochlea complex [1]. It is characterized by restricted elevation of the affected eye in adduction, downshoot in adduction, 'V' pattern, a positive forced duction test (FDT) for the superior oblique tendon, and no superior oblique overaction. Although it is usually congenital, acquired cases may occur following trauma, inflammatory or autoimmune systemic diseases, or previous ocular or sinonasal surgeries. Clinically, patients often present with primary position hypotropia, limited elevation in adduction, diplopia, amblyopia, and an abnormal compensatory head posture (AHP) [2].

The underlying pathophysiology is typically linked to a fibrotic or inelastic segment of the superior oblique tendon, particularly near the trochlea. This variability in tendon elasticity contributes to the diverse clinical presentations and degrees of severity observed among patients. Recent literature suggests that congenital Brown syndrome may result from defective trochlear nerve nucleus or axon development, leading to improper superior oblique muscle-tendon-trochlea complex development. This can lead to a long, lax, absent, or improperly inserted tendon, or a limited, poorly defined trochlea. Therefore, it may be proposed that the congenital Brown may fall within the spectrum of congenital cranial dysinnervation disorders (CCDDs). [3]. In some cases, spontaneous improvement may occur over time, regardless of the etiology [4].

Management options vary according to the severity of the symptoms and etiology. In mild to moderate forms of congenital cases without significant primary position deviation or amblyopia, observation is recommended. Severe forms of congenital Brown require surgical intervention. Furthermore, in acquired cases, treatment of the underlying systemic disease, along with observation, is appropriate in most instances.

Surgical management of Brown syndrome remains challenging, especially in patients with significant symptoms, who show little response to observation or conservative therapy [5]. Surgical management aims to relieve the mechanical restriction of the superior oblique tendon through techniques such as tenotomy, tendon elongation with silicon expander, or recession [5,6]. Nevertheless, these procedures carry potential risks, including overcorrection, granuloma formation, and secondary superior oblique palsy.

The “chicken suture” technique, first described by Knapp, represents a modification of traditional weakening procedures. By using partial suture fixation before tenotomy or elongation, this method allows for a graded weakening of the tendon, thereby improving surgical predictability and reducing the likelihood of overcorrection [7].

This retrospective case series aims to report the clinical profiles and long-term motor and sensory outcomes in patients presenting with Brown syndrome.

## MATERIAL AND METHODS

This retrospective study was conducted at a tertiary care center in northern India, after obtaining ethical clearance from the Institutional Ethics Committee and adhering to the principles outlined in the Declaration of Helsinki. The medical records of all cases of Brown syndrome that presented to the Squint Clinic between January 2022 and December 2024 were reviewed. The cases with complete records, a minimum follow-up of 1 year, and participants willing to provide written informed consent were included in the final analysis. Patients with a history of previous strabismus surgery, any neurological disorder, and those with incomplete records were excluded. Detailed information regarding clinical history, including age at presentation, onset and progression of symptoms, presence of diplopia, abnormal head posture, diminution of vision, history of trauma, prior ocular or sinonasal surgery, systemic illness, and family history, was obtained.

A total of 14 patients, 11 with congenital and 3 with acquired Brown syndrome, were included in this study. All patients underwent a comprehensive ophthalmic evaluation, including best-corrected visual acuity, cycloplegic refraction, ocular motility evaluation by duction and version testing, the Hirschberg test, and the prism bar cover test. Based on clinical findings, participants were classified as mild (limitation of elevation in adduc-

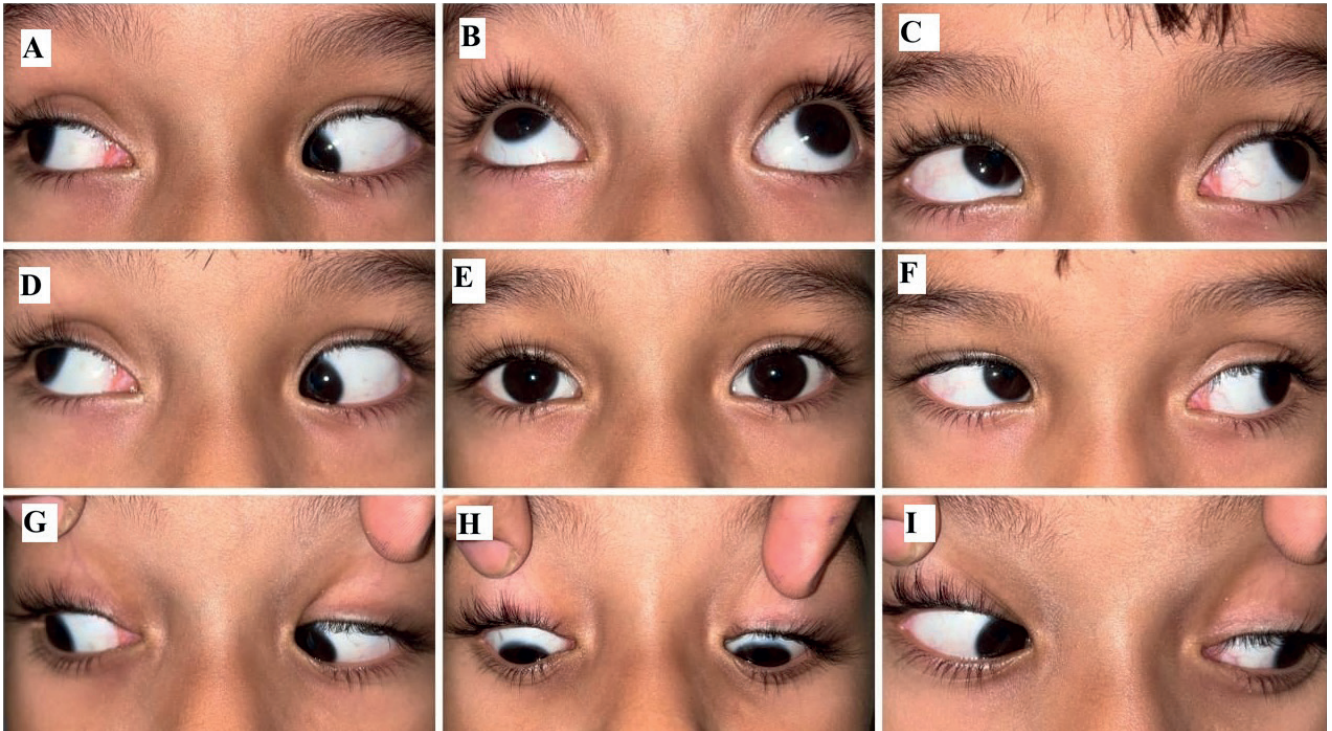
tion without deviation in the primary position), moderate (downshoot in adduction with minimal or no deviation in the primary position), or severe Brown syndrome (presence of significant vertical deviation in the primary position and/or abnormal head posture) [2]. Dilated fundus examination was performed in all patients, and fundus photographs were taken for record purposes. Objective fundus torsion was measured in terms of disc fovea angle (DFA), using fundus photographs acquired in the primary position. The images were analyzed using Image J and CorelDRAW X7 software to estimate DFA, which was quantified as the angle between a line connecting the geometric center of the optical disc to the fovea and a horizontal line across the disc center. DFA was recorded as a positive value when the fovea was positioned above the center of the optic disc, and as a negative value when the fovea was positioned below the center of the disc [8].

Sensory evaluation included the Worth four-dot test and Titmus stereoacuity testing.

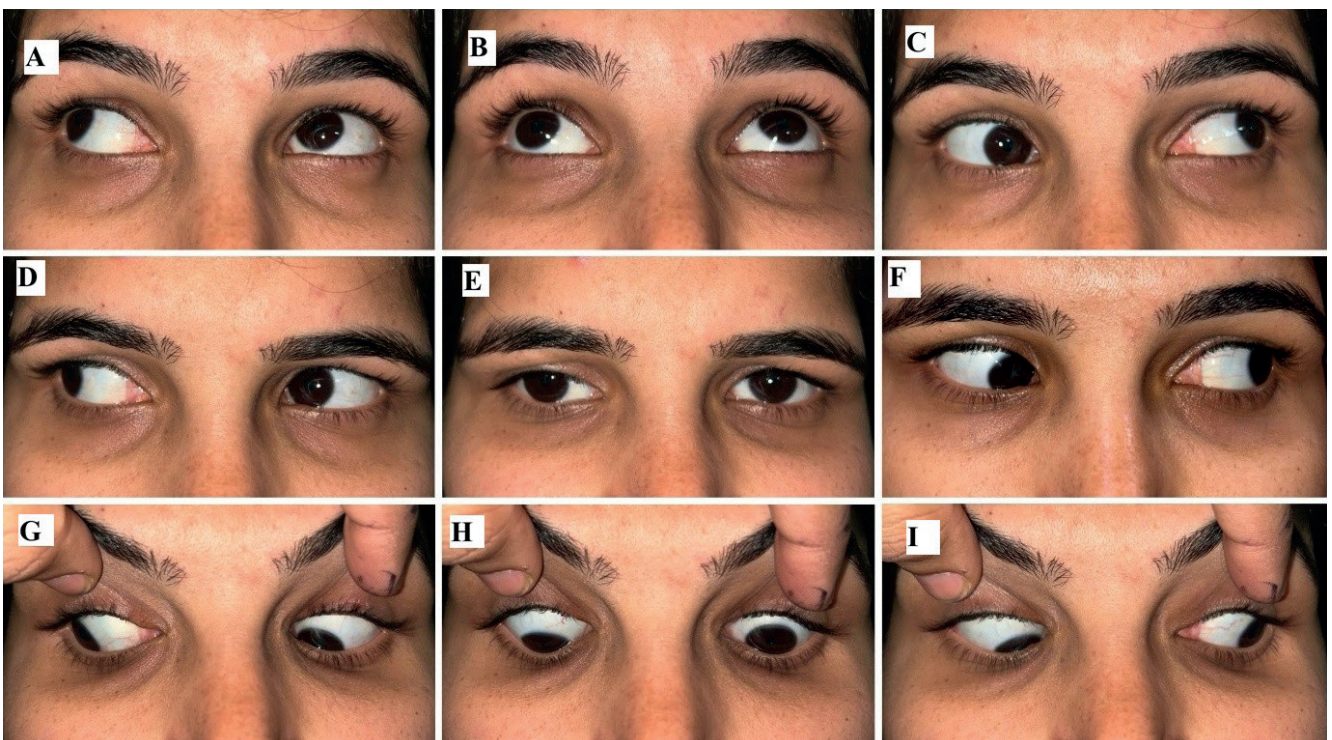
Out of 11 congenital cases, 4 patients had mild Brown syndrome, showing orthotropic in the primary position, and were managed conservatively with refractive correction and observation. Two patients with moderate Brown syndrome and 3 acquired cases having minimal hypotropia in the primary position were managed conservatively with refractive correction and observation. Only 5 patients had severe congenital Brown syndrome, with significant vertical deviation in primary position, and underwent surgical management (Figure 1, 2). Five patients who met the criteria for surgical intervention underwent the superior oblique lengthening procedure, using a chicken suture after confirming superior oblique tendon restriction on exaggerated Guyton's tendon traction test. To achieve adequate globe exposure and traction, an inferonasal traction suture was placed using 60 silk. A superior fornix conjunctival incision was fashioned posterior to the limbus, and a Desmarest retractor was used to enhance visualization. Through a small incision in the intermuscular septum, the superior rectus tendon was carefully identified, hooked, and exposed. The superior oblique tendon was then identified and marked approximately 4 mm nasal to the nasal border of the superior rectus muscle. A double-armed 50 Ethion suture was passed through the tendon with full-thickness bites and secured with locking sutures on either side, and a second similar suture was placed 4 mm nasal to the first. The tendon segment between the sutures was then clamped with artery forceps, and a slip knot was applied. The tendon was cut between the clamp, and final suture knots were tied, ensuring separation of the cut ends of the tendon by 8 mm. Release of tendon restriction was confirmed by repeated exaggerated Guyton's traction test. The conjunctiva was then closed meticulously, using 80 Vicryl sutures (Figure 3A–H). In patients with horizontal deviation, horizontal recti surgery was planned according to the

primary position of the horizontal deviation. A successful outcome was defined by horizontal alignment within 10 PD, and vertical alignment within 5 PD in the primary position.

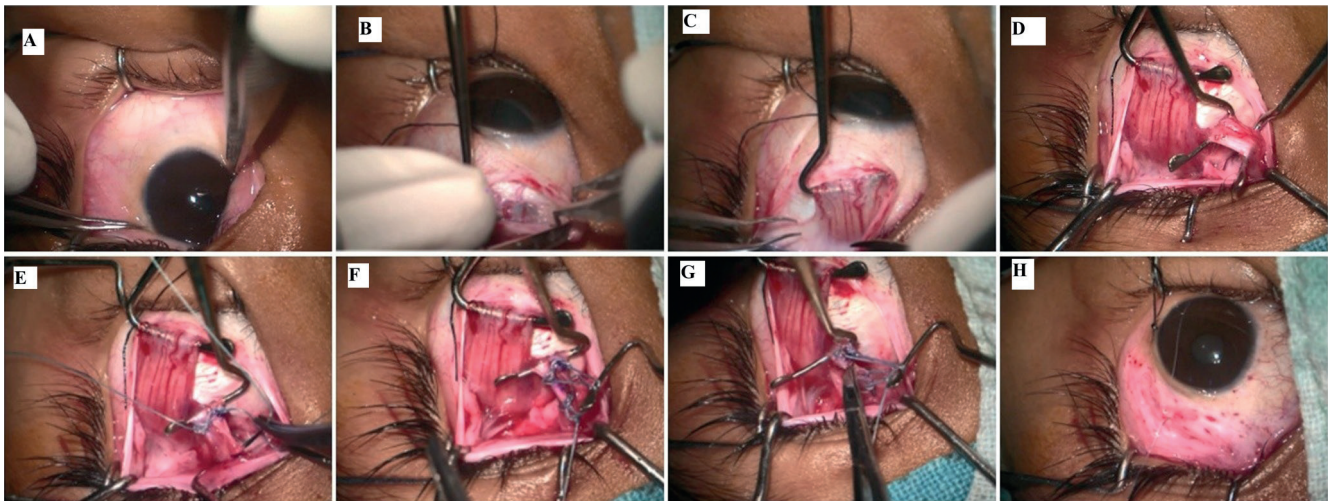
Postoperatively, patients were followed up for at least 1 year, with assessments of ocular alignment in primary gaze, residual vertical deviation, ocular motility, ocular torsion, and sensory outcomes. (Figure 4, 5).



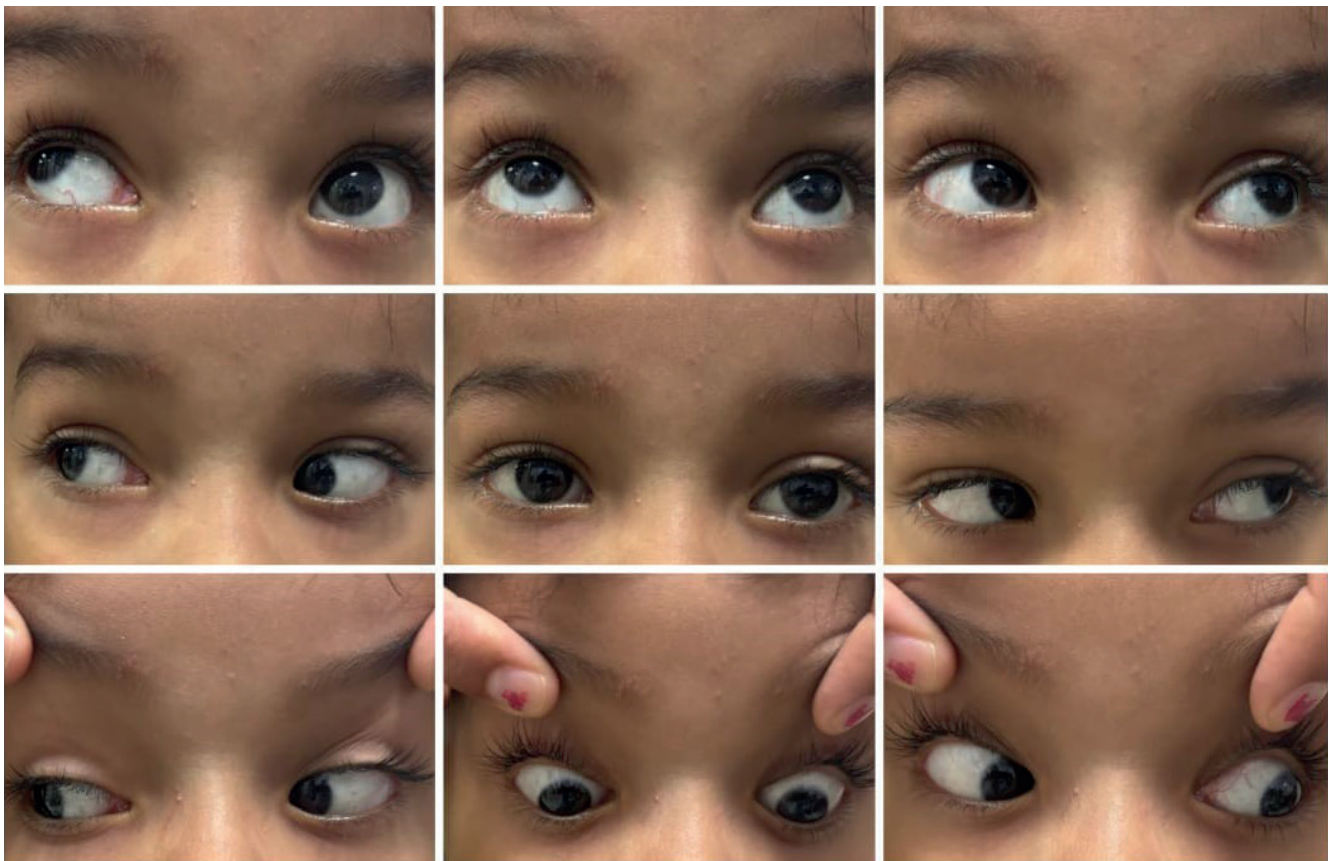
**Figure 1.** Pre-operative nine-gaze photographs of Case 1 revealing marked limitation of elevation in adduction (-4 limitation) in the left eye (OS) (A, D), with normal extraocular movements in the right eye (OD), suggestive of severe Brown syndrome OS



**Figure 2.** Preoperative nine-gaze photographs of Case 4 demonstrating marked elevation limitation and downshoot (C, F) in adduction OD with exotropia in primary position (E), suggestive of exotropia with congenital severe Brown OD  
OD – right eye



**Figure 3.** Intraoperative photographs showing positive exaggerated Guyton's tendon traction test for Superior Oblique (SO) (A), isolation and hooking of the superior rectus and SO tendon (B–D). Placement of double-armed 5-0 Ethibond suture on the SO tendon 4 mm apart and controlled separation of the tendon ends to achieve approximately 8 mm of tendon lengthening (E–G), followed by conjunctival closure by 8-0 Vicryl sutures (H)

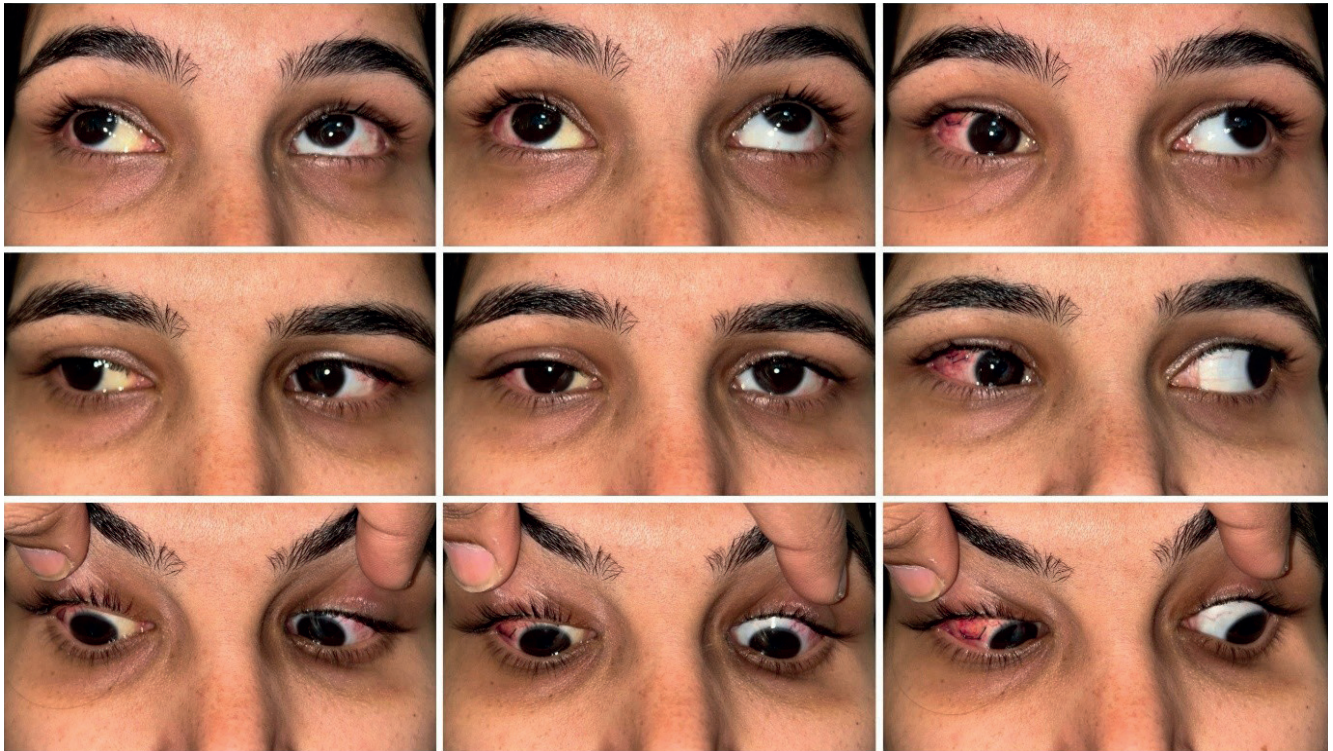


**Figure 4.** Postoperative nine-gaze photographs of Case 1 showing marked improvement in elevation in adduction with orthophoria in primary gaze

## RESULTS

The basic and demographic details of the study participants are summarized in Table 1. The mean age was 17 years (range 4–38 years), and the majority were females (64%). All cases presented unilaterally, with the right

eye involved in most patients (64%). The most common presenting complaint was downshoot in adduction, followed by AHP in congenital cases, while diplopia was the chief complaint in all acquired cases. Mild Brown cases did not have any complaints; they were diagnosed incidentally.



**Figure 5.** Postoperative nine-gaze photographs of Case 4 showing marked improvement in elevation in adduction with orthophoria in primary gaze

Only 5 cases required surgical intervention, while 9 were managed conservatively (including 3 acquired cases). Refractive correction was advised for mild and moderate congenital Brown patients, with regular follow-ups, as none had any evidence of amblyopia, suppression, and stereoacuity was in the normal range, 80–40 sec of arc. Three patients with acquired Brown syndrome secondary to specific underlying etiologies required targeted management: the first case was associated with thyroid eye disease, manifesting as restrictive myopathy in the setting of thyroid ophthalmopathy, for which systemic medical treatment with steroids and close monitoring of inflammatory activity was instituted. The second case had acquired Brown following endoscopic sinus surgery and was also managed conservatively, improving over nine months of follow-up. The third case was attributed to an inflammatory etiology, secondary to myocysticercosis of the superior oblique. This case was managed conservatively with antiparasitic therapy, anti-inflammatory agents, and serial monitoring of cystic resolution and motility improvement.

Long-term sensory and motor outcomes were assessed in all 14 patients over a minimum 1-year follow-up period. Mild (n = 4) and moderate (n = 2) cases managed conservatively remained stable without progression of limitation, deviation, suppression, amblyopia, or development of abnormal head posture. Acquired cases (n = 3) had favorable outcomes and were orthophoric in primary position and diplopia-free in primary and down-gaze positions.

**Table 1.** Baseline and demographic details of the participants (n = 14)

Basic Details	Mean/Range/Frequency
Age	17 years (range 4–38 years)
Sex	
Male	5
Female	9
Etiology	
Congenital	11
Acquired	3
Laterality	
Right	9
Left	5
Grades	
Mild	4
Moderate	5 (2 congenital, 3 acquired)
Severe	5
Presenting complaints	
Incidental	4
Vertical deviation	3
Horizontal deviation	3
Downshoot in adduction	5
AHP	3
Diplopia	3 (only in acquired cases)
Management	
Conservative	9
Surgery	5

AHP – abnormal head posture

The preoperative and postoperative details of all 5 patients with severe congenital Brown syndrome, who underwent superior oblique chicken suture surgery, have been summarized in Tables 2 and 3, respectively.

The mean primary position horizontal deviation among patients who underwent surgical intervention was 20 PD (range, 0–45 PD), and the vertical deviation was 22 PD (range, 20–30 PD). All these patients had objective intorsion, DFA ranging from +9.06° to +15.06° in the affected eye. Two of them required SO chicken suture lengthening by 8 mm only, and the remaining 3 required additional horizontal recti surgery, depending upon the primary position horizontal deviation. All patients achieved a successful surgical outcome, with primary position horizontal alignment within 10 PD and vertical alignment within

4 PD. Objective torsion improved without any torsional diplopia postoperatively, DFA ranging from -1.56° to +7.04° in the affected eye. Only one patient experienced suppression on the W4DT, which resolved after surgical correction. AHP and stereopsis improved in all cases postoperatively. None of the patients reported any other adverse outcomes.

## DISCUSSION

Brown syndrome manifests as a restrictive strabismus, characterized by mechanical limitation of elevation in adduction, resulting from pathology of the superior oblique tendon-trochlea complex. The clinical severity

**Table 2.** Preoperative details of the participants who underwent surgical intervention (n = 5)

Case	Age/sex	BCVA (OD)	BCVA (OS)	Primary position deviation (PD)	Sensory status on the W4DT and TT	Objective Torsion in terms of Disc Fovea Angle in degree	Diagnosis	FDT	Strabismus Surgery performed
1	4Y/M	6/6	6/9	20 PD vertical	Suppression on W4DT, Gross stereopsis only	OD -2.08° OS +15.06°	OS severe Brown syndrome	Positive	OS chicken suture lengthening of SO by 8 mm.
2	14Y/F	6/9	6/6	45 PD horizontal 20 PD vertical	No Suppression, 400 sec of arc	OD +9.06°, OS -3.28°	OD severe Brown syndrome with alternate divergent squint	Positive	OD chicken suture lengthening of SO by 8 mm and bilateral LR recession 10 mm
3	16Y/F	6/6	6/6	20 PD horizontal 30 PD vertical deviation	No Suppression, 160 sec of arc	OD +12.06° OS -2.09°	OD severe Brown syndrome	Positive	OD chicken suture lengthening of SO by 8 mm and LR recession 8 mm
4	22Y/F	6/6	6/6	35 PD horizontal, 20 PD vertical	No Suppression, 140 sec of arc	OD +9.86° OS -1.09°	OD severe Brown syndrome with alternate divergent squint	Positive	OD chicken suture lengthening of SO by 8 mm, OD LR recession 10mm, OS LR recession 9mm
5	26Y/M	6/6	6/6	20 PD vertical	No Suppression, 100 sec of arc	OD -0.98° OS +13.05°	OS severe Brown syndrome	Positive	OS chicken suture lengthening of SO by 8 mm

BCVA – best corrected visual acuity, W4DT – Worth four dot test, TT – Titmus test, OD – right eye, OS – left eye, PD – prism diopters, FDT – forced duction test, Y – year, M – male, F – female, SO – superior oblique, LR – lateral rectus

**Table 3.** Long-term postoperative motor and sensory outcomes of the participants who underwent surgical intervention (n = 5)

Case	Deviation In Primary Gaze	Objective Torsion in terms of disc fovea angle	Sensory Improvement	Long-Term Outcome
1	Orthophoric	OD -1.98° OS +7.04°	W4DT: no suppression, TT: 200 sec of arc	Alignment was maintained for 24 months.
2	Orthophoric	OD -1.56°, OS -2.88°	W4DT: no suppression, TT: 200 sec of arc	Alignment was maintained for 18 months.
3	Orthophoric (hypotropia within 4 PD)	OD +5.06° OS -1.90°	W4DT: no suppression, TT: 100 sec of arc	Alignment was maintained for 18 months.
4	Orthophoric, Hypotropia within 4 PD	OD +3.86° OS -1.26°	W4DT: no suppression, TT: 80 sec of arc	Alignment was maintained for 15 months.
5	Orthophoric horizontally, hypotropia within 4 PD	OD -1.68° OS +6.06°	W4DT: no suppression, TT: 80 sec of arc	Alignment was maintained for 12 months.

OD – right eye, OS – left eye, PD – prism diopters, W4DT – Worth four dot Test, TT – Titmus test

varies considerably and has traditionally been categorized based on motility patterns and primary position alignment: mild cases demonstrate isolated limitation of elevation in adduction without primary gaze deviation; moderate cases exhibit characteristic downshoot during adduction with minimal or no primary deviation; and severe forms feature substantial vertical deviation in primary gaze, often with compensatory abnormal head posture [2]. Although congenital Brown syndrome predominates clinically, acquired forms occur following trauma, inflammatory processes, such as scleritis or idiopathic orbital inflammation, or iatrogenic insults, including sinus or orbital surgery.

The natural history of congenital Brown syndrome remains variable, with longitudinal studies documenting spontaneous improvement or resolution in up to 75% of mild or asymptomatic cases over several years [6,9]. This probably reflects the maturation of the tendon-trochlea complex, leading to motor improvement and adaptive neural plasticity, resulting in sensory improvement. This variability supports observation as the initial strategy for patients who lack significant primary deviation, abnormal head posture, symptomatic diplopia, or an amblyopia risk. In our case series, approximately 64% of patients were managed conservatively, with satisfactory motor and sensory outcomes, which is in concurrence with the previous literature.

However, conservative measures prove inadequate when misalignment compromises binocular function or quality of life, leading to intractable diplopia, fusion decompensation, AHP, or sensory adaptations like suppression. Surgical intervention then becomes imperative. The risk of postoperative overcorrection – manifesting as iatrogenic superior oblique palsy with hypertropia and extorsion – mandates graded, controlled tendon weakening techniques that preserve residual superior oblique function and ensure alignment stability.

Surgical approaches for Brown syndrome can be divided into irreversible procedures (complete superior oblique tenotomy, tenectomy, recession, or combined tenotomy with ipsilateral inferior oblique weakening) and reversible/adjustable methods (sheathotomy, silicone spacers, Z-tenotomy, posterior tenectomy, or superior oblique chicken suture) [5,10]. The chicken suture technique, originally described by Philip Knapp and subsequently refined, involves placing non-absorbable suture spacers between partial tendon splits to achieve controlled elongation (typically 8–10 mm) without disinsertion. This permits intraoperative titration via repeated traction testing, effectively relieving restriction, while minimizing excessive weakening that could cause superior oblique palsy, consecutive intorsion, or torsional diplopia [11,12]. Long-term data confirm the superiority of graded techniques over free tenotomy, which carries a 20–30% risk of overcorrection.

In our series of 14 patients, we evaluated one-year sensory and motor outcomes following superior oblique

chicken suturing in 5 cases with severe congenital Brown syndrome, in conjunction with conservative management for milder or acquired forms. The surgically treated subgroup ( $n = 5$ , severe congenital) achieved primary gaze alignment, resolution of abnormal head posture, and sustained motility gains without decompensation. Postoperative torsion normalized on fundus photography, binocular single vision was restored where feasible, and no secondary vertical misalignment occurred.

These findings align with published series on superior oblique lengthening, reporting stable long-term alignment in up to 100% of cases, without any overcorrection or adverse outcomes. The chicken suture, due to its controlled slippage, which preserves tendon integrity, demonstrates an advantage over free tenotomy, which historically yields unpredictable results and a 25% incidence of iatrogenic palsy. Extensive reviews confirm the benefits of suture spacers in moderate-to-severe cases, including reduced inflammation and a lower re-surgery rate [11–13].

Compared to Wright's silicone expanders (which have comparable alignment but a 5–10% risk of extrusion or granuloma), chicken suture avoids foreign body complications while achieving precision elongation of 8–10 mm. None of our patients developed superior oblique palsy after 8 mm of chicken suture lengthening of SO (12–30% in complete tenotomies), postoperative A-pattern exotropia, or torsional diplopia, validating the safety of controlled weakening.

Mild residual elevation limitation persisted in some cases, consistent with reports of 20–40% post-lengthening, probably due to trochlear fibrosis. Nevertheless, functional outcomes excelled, with high satisfaction and no reoperations. Surgical goals thus emphasize symptom relief, restoration of binocularity, and alignment in the primary position.

Limitations include the retrospective design, a modest sample size ( $n = 14$ ), single-center data, and the absence of a control group. Larger prospective comparative studies are needed, but ethical concerns prevent randomization in severe cases where surgery is clearly indicated.

## CONCLUSION

In conclusion, this series demonstrates that mild to moderate cases of congenital Brown syndrome, without any evidence of primary position deviation or loss of binocularity, can be managed by observation alone. Acquired cases require targeted therapy of the underlying etiology, followed by observation for resolution of restriction. Superior oblique chicken suture lengthening is a safe, predictable, and lasting procedure for treating severe congenital Brown syndrome, yielding favorable long-term outcomes with minimal complications.

## REFERENCES

1. Fu L, Gurnani B, Malik J. Brown syndrome. InStatPearls [Internet] 2024 Mar 3. StatPearls Publishing.
2. Khorrami-Nejad M, Azizi E, Tarik FF, Akbari MR. Brown syndrome: a literature review. *Therapeutic Advances in Ophthalmology*. 2024;16:1-13.
3. Ellis FJ, Jeffery AR, Seidman DJ, Sprague JB, Coussens T, Schuller J. Possible association of congenital Brown syndrome with congenital cranial dysinnervation disorders. *JAAPOS*. 2012;16(6):558-564.
4. Wright KW. Brown's syndrome: diagnosis and management. *Trans Am Ophthalmol Soc*. 1999;97:1023-1109.
5. Koc AA, Aygit ED, Inal A, et al. Brown Syndrome: Features and Long-term Results of Management. *Beyoglu Eye J*. 2021;6(3):223-228.
6. Mirmohammadsadeghi A, Akbari MR, Sadeghi M, Masoomian B, Saatchi M. Surgical Treatment of Congenital Brown Syndrome, A Review. *J Binocular Vis Ocular Motility*. 2025;8:1-7.
7. Singh A, Khurana M, Mallik KB, Pandey PK, Kumar B. Long-term outcomes of superior oblique chicken suture in two sisters of familial unilateral brown syndrome: Case report and literature review. *The Pan-Am J Ophthalmol*. 2025;7(1):138.
8. Pandey PK, Singh A, Jayaraj S, et al. Long-term surgical outcomes of bilateral symmetrical superior oblique nasal tenotomy in patients of large A-pattern exotropia. *J Curr Ophthalmol*. 2024;35(4):375-380.
9. Dawson E, Barry J, Lee J. Spontaneous resolution in patients with congenital Brown syndrome. *J Am Assoc Pediatric Ophthalmol Strab*. 2009;13(2):116-118.
10. Wright KW, Strube YN. Superior oblique tendon weakening procedures. In *Color Atlas of Strabismus Surgery: Strategies and Techniques* 2025 Aug 20 (pp. 159-168). Cham: Springer Nature Switzerland.
11. Stager Jr DR, Parks MM, Stager Sr DR, Pesheva M. Long-term results of silicone expander for moderate and severe Brown syndrome (Brown syndrome "plus"). *Journal of American Association for Pediatric Ophthalmology and Strabismus*. 1999;3(6):328-332.
12. Suh DW, Guyton DL, Hunter DG. An adjustable superior oblique tendon spacer with the use of nonabsorbable suture. *J AAPOS*. 2001;5(3):164-171.
13. Suh DW, Oystreck DT, Hunter DG. Long-term results of an intraoperative adjustable superior oblique tendon suture spacer using nonabsorbable suture for Brown syndrome. *Ophthalmology*. 2008;115(10):1800-1804.