

DIABETIC RETINOPATHY – DIAGNOSTICS AND TREATMENT GUIDELINES

Studnička J^{1,2}, Němčanský J^{3,4}, Vysloužilová D⁵, Ernest J^{6,7,8}, Němec P⁸

¹Department of Ophthalmology, University Hospital Hradec Králové and Faculty of Medicine, Charles University in Hradec Králové, Czech Republic

²VISUS, spol. s r.o., Police nad Metují, Czech Republic

³Department of Ophthalmology, University Hospital Ostrava, Czech Republic

⁴Department of Craniofacial Surgery, Faculty of Medicine, University of Ostrava, Czech Republic

⁵Department of Ophthalmology, University Hospital Brno Bohunice, Faculty of Medicine, Masaryk University Brno, Czech Republic

⁶Neoris Vitreoretinal Center, s.r.o., Prague, Czech Republic

⁷Axon Clinical, s.r.o., Prague, Czech Republic

⁸Department of Ophthalmology, Central Military Hospital and 1st Faculty of Medicine, Charles University Prague, Czech Republic

The authors of the study declare that no conflict of interests exists in the compilation, theme and subsequent publication of this professional communication, and that it is not supported by any pharmaceuticals company.

Received: June 4, 2023

Accepted: July 16, 2023

Available on-line: September 20, 2023



First author

Doc. MUDr. Jan Studnička, Ph.D.

Corresponding author

MUDr. Jan Němčanský, Ph.D., MBA

Oční klinika FN Ostrava

17. listopadu 1790

708 52 Ostrava

E-mail: jan.nemcansky@fno.cz

SUMMARY

Diabetic retinopathy is one of the most common complications of diabetes mellitus and represents a serious health, social and economic problem. With the expected increase in the number of patients with diabetes, it is becoming the leading cause of severe vision loss in the working-age population. The presented guidelines summarize the current knowledge about this disease in order to standardize and update the procedures for the diagnosis, classification and treatment of diabetic retinopathy.

Key words: diabetic retinopathy, diabetes mellitus, guidelines

Čes. a slov. Oftal., 79, 2023, No. 5, p. 238–247

INTRODUCTION AND EPIDEMIOLOGY

Diabetes mellitus (DM) represents one of the most serious health problems of the present day. It is estimated that it currently affects 537 million people worldwide, with an expected increase to 750 million by the year 2030 [1–3].

Serious late complications of DM include diabetic retinopathy (DR), diabetic kidney disease (diabetic nephropathy), diabetic polyneuropathy and diabetic foot. These are microvascular complications of DM which usually affect the patient simultaneously.

With the increasing prevalence of DM and the growing number of its attendant complications, diabetes is becoming the main cause of severe loss of sight in the working-age population, above all as a consequence of diabetic macular edema (DME) and proliferative diabetic retinopathy (PDR) [4].

In 2020, DR and DME were diagnosed in more than 100 million people worldwide, and it is expected that this number will increase to 160 million by 2045. The prevalence of DR and DME in Europe is 19%, which represents more than 11 million patients [5].

The incidence and progression of diabetic retinopathy and its complications depends on the quality and intensification of diabetes treatment [6,7].

The development of complications of DR depends on the length of duration of diabetes [8], on the degree of intensity of monitoring of glycemia [9], on the compensation of other comorbidities, above all cardiovascular diseases, hypertension [10], hyperlipidemia [11], and renal disorders [12,13]. Genetic influences are also manifested in the development of PDR [14,15].

In 2017 there were one million patients with DM in the

Czech Republic (CZ), and it is expected that this number will increase by 30% in the coming years. Approximately 100 000 people suffer from DR, and one quarter of these have proliferative form of DR. Almost 2 200 patients with DR are also classified as blind [16].

In the past, the main method of treatment of DR was only laser photocoagulation of the retina [17].

At present primarily pharmacological intraocular treatment is beginning to be applied in the treatment of DR, and in many cases it is possible to achieve the maximum therapeutic effect through a combination of a number of available methods of treatment – laser, pharmacological treatment and surgery.

PATHOGENESIS OF DIABETIC RETINOPATHY

The fundamental triggering factor in the onset of DR is hyperglycemia, which leads via a variety of mechanisms to a disorder of microcirculation. An early, clinically significant manifestation of DR is capillary dilation and changes of blood through-flow. In diabetic patients these changes are considered to represent metabolic auto-regulation for improvement of the retinal mechanism [18]. The continuing pathological process is manifested in capillary pericyte loss. There is a disruption of contact between the endothelial cells and pericytes, which cease to influence blood flow in the capillaries. At the same time, pericytes are responsible for providing structural support for capillaries, and their loss leads to localized buckling of the capillary vascular walls. This process is associated with the formation of microaneurysms, which are the most common clinical symptom of the onset of DR [19]. Besides loss of pericytes, the course of the pathogenesis of DR is also characterized by apoptosis of the endothelial cells and thickening of the basal membrane, which together contribute to a breach of the blood-retinal barrier [20]. Subsequent extravasation leads to the onset of retinal edema and the depositing of proteins and lipids in the form of hard exudates [21]. In addition, pronounced loss of pericytes and endothelial cells has the consequence of capillary occlusion and ischemia. Disruptions of axonal transport occur in the retinal nerve fiber layer, and cotton-wool deposits appear. Retinal ischemia and hypoxia lead to an increased production of vascular endothelial growth factor (VEGF) by means of activation of hypoxia-inducible factor 1 (HIF-1). HIF-1 increases the permeability of capillaries, which is followed by an accumulation of extracellular fluid [22]. Further angiogenic factors contribute to the regulation of vascular permeability, e.g. angiopoietins (Ang-1, Ang-2) [23].

A fundamental role in the pathophysiology of DR is also played by chronic inflammatory changes of the capillaries. A key process in the early phases of inflammation is thought to be leukostasis, which contributes to retinal microvasculature occlusion, damage to the endothelium and breach of the blood-retinal barrier. In the further course, inflammatory mediators are released, activating changes in the retinal nerve and glial cells. This intensifies retinal hypoxia, which in the late stages is followed by the forma-

tion of neovascularizations (NV). Direct responsibility for their development is borne by numerous pro-angiogenic cytokines: VEGF, IGF-1 (insulin-like growth factor), PEDF (pigment epithelium-derived growth factor), transforming growth factor beta (TGF- β), basic fibroblast growth factor (bFGF), HGF (hepatocyte growth factor), Ang-2, NGFR (nerve growth factor receptor) as well as placental growth factor (PIGF) [24–26]. Neovascular capillaries are fragile and susceptible to hemorrhage. High levels of inflammatory mediators correlate with the development of fibrosis in the advanced stages of PDR [27]. The maturing of fibrovascular membranes leads to the occurrence of traction, and in the terminal stages to tractional retinal detachment.

Another factor which is manifested within the progression of DR is neurodegeneration. It has been demonstrated that neurodegeneration occurs in the diabetic retina on a structural, functional and molecular level. This also takes place in the case that microvascular abnormalities are not yet clinically evident. It is highly probable that neurodegeneration causes microvasculopathy, rather than vice versa [28–30].

DIAGNOSIS OF DIABETIC RETINOPATHY

The diagnostic methods used in the examination of patients with diabetic retinopathy include recording of the patient's medical history, with emphasis on the length of duration of diabetes and its compensation (level of glycated hemoglobin – HbA1c), general pharmacological treatment, associated diseases (arterial hypertension, hypercholesterolemia, kidney diseases) and ocular complaints (character and length of complaints). The above-stated parameters are significant in connection with the metabolic memory of the organism.

Among the basic objective examinations we include determination of best corrected visual acuity (BCVA), measurement of intraocular pressure, gonioscopy in order to exclude NV of the chamber angle and examination of the anterior segment of the eye on a slit lamp.

A key examination is assessment of the finding on the retina. For this purpose we use indirect ophthalmoscopy with the aid of a slit lamp and an auxiliary lens (biomicroscopy of ocular fundus), and we document the finding by fundus photography. Fundus photography including red-free photography enables a detailed evaluation of the finding and comparison over time (the red-free image provides higher sensitivity than ordinary color photography in the diagnosis of DR). For documenting the maximum of changes and the condition of the retinal periphery we currently use wide-angle systems which display up to 82% of the surface of the retina, and enable a view up to 270 degrees [31,32]. Evaluation of the condition of the retinal periphery is essential for the diagnosis, monitoring, treatment and prognosis of DR. It has been demonstrated in trials that 30–40% of eyes with DR at the same time manifest presence of peripheral retinal lesions [31,33,34]. Peripheral retinal lesions are associated with a 3.2 times increased risk of progression of DR by two or more degrees, and a 4.7 times increased risk of progression to PDR within four years [35].

Other examinations essential for the diagnosis of DR include optical coherence tomography (OCT), OCT angiography (OCTA) and fluorescence angiography (FAG) with the use of their wide-angle modalities in order to diagnose the condition of the retinal periphery [36]. In connection with the rapid advances in diagnostic examination methods in recent years, the deployment of modern computer technologies in the diagnostic and decision-making process has become increasingly significant. The evaluation of examination results with the aid of neural networks (artificial intelligence) and their transmission via telemedicine is being ever-increasingly applied. So far these technologies have found application in screening, but we can expect their expansion also into specialized ophthalmological care [37–39].

CLINICAL PICTURE OF DIABETIC RETINOPATHY

Diabetic retinopathy is characterized by the presence of the following retinal lesions:

- Microaneurysms
- Retinal hemorrhages
- Venous malformations – dilation, (omega) loops, venous beading
- Cotton-wool spots
- Intraretinal microvascular abnormalities (IRMA)
- Retinal thickening – edema
- Retinal ischemia
- Hard exudates (lipid deposit)
- Retinal neovascularization on optic nerve disc (NVD)
- Retinal neovascularization elsewhere (NVE)
- Neovascularization of iris

- Neovascularization of ciliary body
- Epiretinal membranes
- Retinal hemorrhages
- Tractional retinal detachment

CLASSIFICATION OF DIABETIC RETINOPATHY

We divide diabetic retinopathy based on the presence of the above-stated lesions into two basic degrees: nonproliferative DR (NPDR) and proliferative DR (PDR).

A summary is presented in Table 1 [40–43].

TREATMENT OF DIABETIC RETINOPATHY

The fundamental precondition for the successful treatment of DR is the treatment of the underlying pathology and associated diseases, good compensation of diabetes and adherence to regimen and lifestyle adjustments (patient compliance).

Specific treatment of DR then incorporates laser photocoagulation, medicamentous therapy with intraocular injections and surgical treatment – pars plana vitrectomy (PPV) [40,41,44–47]. In many cases we achieve the best results through a combination of the aforementioned methods.

Treatment of other complications of DM also have their specifics (e.g. secondary neovascular glaucoma, cataract etc.).

Treatment of hyperglycemia

The need for close compensation of DM is a fundamental precondition for the successful treatment of DR, and

Table 1. Diabetic retinopathy classification

Diabetic retinopathy	Clinical signs
No DR (0)	No abnormalities
Mild nonproliferative DR (1)	Microaneurysms only
Moderate nonproliferative DR (2)	Mikroaneurysms and other signs (dot and blot retinal hemorrhages, hard exudates, cotton wool spots), no signs of severe NPDR
Severe nonproliferative DR (3) • Very severe NPDR *	At least one of the following signs present • Intraretinal hemorrhages (≥ 20 in each quadrant) • Venous beading (in 2 quadrants) • IRMA (in 1 quadrant) No signs of PDR
Proliferative DR (4) • High risk PDR **	Severe NPDR and 1 or more of the following signs present • Neovascularization • Intravitreal/preretinal hemorrhage

* at least 2 of 3 signs are present

** at least 3 of the following signs are present:

o NVE

o NVD

o Moderate NV

Localized in area up to 1 disc diameter distance to the disc margin and with size of 1/4 – 1/3 disc diameter

NVE larger than 1/2 disc diameter

o Intravitreal or preretinal hemorrhage

DR – diabetická retinopatie, NPDR – neproliferativní DR, PDR – proliferativní DR, IRMA – intraretinální mikrovaskulární abnormalita, NVD – neovaskularizace disku, NVE – neovaskularizace mimo terč disku

leads to a reduction of the risk of onset and progression of DR. Reduction of the value of HbA1c by 1% leads to a reduction of the risk of onset of microvascular complications by 37% [48]. Close compensation of diabetes and intensive insulin therapy may be associated with an increased risk of severe hypoglycemia. As a result, for patients with a medical history of severe hypoglycemia, expected shorter length of life and advanced micro and macrovascular complications or extensive comorbidities, we prefer less stringent glycemic targets [49].

In connection with compensation of DM it is necessary to highlight the risk of occurrence of early normoglycemia deterioration syndrome. This is manifested in a rapid progression of DR following a sharp drop in the level of glycosylated hemoglobin. The occurrence and severity of this syndrome depends on the level of HbA1c, the degree of DR and the length of duration of subcompensated diabetes, and requires timely therapeutic intervention and intensive monitoring [46,47]. This condition affects patients e.g. after the introduction of an intensified insulin regimen, following pancreas transplant etc.

Treatment of hypertension

Attaining normal blood pressure values is of fundamental importance for diabetic patients. Reduction of systolic blood pressure by 10 mmHg leads to a decrease in the risk of microvascular complications by 11% [48].

Treatment of dyslipidemia

The results of observational studies describe a connection between serum lipids and diabetic retinopathy. Increased values of general and LDL cholesterol and triglycerides are associated with the progression of retinopathy, proliferative retinopathy [50,51] and the development of macular edema [52]. Treatment with fenofibrates (potentially in combination with statins) leads to a significant reduction of the risk of DR [53,54].

Laser treatment of DR

The aim of classic laser photocoagulation therapy is the occlusion of infiltrating microaneurysms, thermal destruction of ischemic retina, increase of oxygen supply to the surrounding retina, reduction of washing out of proangiogenic factors and release of cytokines from the cells of the retinal pigment epithelium (RPE) and Müller cells. This is followed by a stabilization of visual functions, a regression of the presence and prevention of the occurrence of new NV. In the case of laser treatment of the retinal periphery, panretinal laser photocoagulation is performed. According to the Diabetic Retinopathy Study (DRS) and Early Treatment Diabetic Retinopathy Study (ETDRS), it is effective to perform panretinal laser photocoagulation of the retina in cases of very advanced NPDR [55] and for PDR [17].

Panretinal photocoagulation (PRP) has also been used for the treatment of PDR, and has significantly reduced the risk of severe loss of sight, especially in cases with highly risk complications such as hemorrhage into the vitreous [43]. However, due to its destructive nature, extensive laser therapy may cause permanent damage to retinal cells,

with a slight loss of central vision and deteriorating vision under mesopic conditions and at night [56]. PRP may also lead to loss of the peripheral visual field [56–58].

Occurrence or progression of DME may also occur [59,60], as well as reduction of contrast sensitivity [58,61,62], damage to the posterior ciliary nerves, leading to corneal dilation and accommodative dysfunctions [63]. However, even despite these disadvantages, PRP still remains a key component in the treatment of advanced form of NPDR and PDR. PRP should be performed promptly, without unnecessary delay – according to the type of selected laser in one or more sessions over the course of several weeks (for technique see below). Following the performance of PRP it is essential to assess the effect, and according to the finding it is often necessary to supplement PRP (if regression is not achieved or if new NV appear, in the case of new hemophthalmos). It is stated that further supplementary laser coagulation is required in up to 65% of cases [45].

In pregnant women with a high degree of the risk of development of complications, timely performance of PRP is recommended in the case of advanced form of NPDR at the beginning of pregnancy, primarily due to the risk of deterioration and progression of PDR during the course of pregnancy [27]. Similarly, in juveniles, for whom anti-VEGF therapy constitutes a risk, timely performance of PRP before the development of NV is recommended [27].

Reduction of the adverse effects of laser treatment can be achieved through the use of laser systems transmitting impulses with a duration of tens of microseconds to hundreds of nanoseconds, i.e. by one to two rows lower than classical photocoagulators. A higher output is used, and the tissues are burdened overall with lower energy. Upon threshold photocoagulation of the retina (i.e. with a visible laser beam), in which we aim to achieve an effect comparable to classical photocoagulation, the optimum time appears to be 20 ms. Upon shorter times there is a risk of rupture of the RPE [64].

Reduction of the time of performance of laser treatment and thus the burden on the patient is enabled by systems using charges produced in preset formulae (patterns) with the aid of a scanner controlled by a microprocessor. The individual configurations and parameters (spacing between beams, radii of circles, shapes of matrices etc.) can be altered immediately during treatment. A necessary precondition for full use of these instruments is a short time of application of the individual impulses (also while preserving the intervals between the individual impulses) [65].

So-called “Pattern lasers” are being ever-increasingly applied in regular clinical practice, since they enable safe performance of PRP in a single session, provide the possibility of significant time savings for the patient and the provider, and at the same time are substantially better tolerated by patients (less pain, while preserving effectiveness) [66–70].

TECHNIQUE OF PERFORMANCE OF PRP

PRP is performed in full artificial mydriasis and under local anesthesia. The typical baseline configuration of the argon laser is exposure of 0.1 seconds with an initial output of 250 mW [40]. Alternatively, it is possible to use an exposure of 0.2 seconds with an initial energy of 120 mW. In the case

of pattern lasers we use an exposure time of 20 ms. The size of the beam is configured according to the lens used so that the size of the beam on the retina is 500 μm . The output is progressively increased until a whitish reaction appears on the retina. Laser beams are set at a width of one beam apart. A total of 1600–3000 laser beams are placed in several sessions upon the use of classical lasers, in the case of pattern lasers it is possible to perform the treatment in a single session. Upon laser treatment of the retina we avoid areas with tractional detachment, pigmented deposits and hemorrhage. The laser is applied at a distance of 2 to 3 diameters of the disc from the center of the macula, and 1 diameter of the disc from the optic nerve disc, outside of the vascular arcade in the direction towards the periphery [40].

Pharmacological intraocular intravitreal therapy

Intravitreal applications of anti-VEGF preparations are currently applied in the treatment of both DR and DME. The professional foundation for their clinical use has been provided by numerous randomized clinical trials [27,45,71–73]. At present two anti-VEGF agents have been approved for intraocular use, in which effectiveness in the treatment of PDR has been demonstrated, namely ranibizumab (trial DRCR.net - protocol S) and aflibercept (trial CLARITY) [45,58]. In trials, both preparations have demonstrated a comparable effect and non-inferiority as against PRP, and in an annual evaluation aflibercept in fact demonstrated superiority in comparison with PRP (CLARITY). With the aid of anti-VEGF treatment it is possible to achieve stabilization of PDR, and in comparison with PRP this treatment has a superior influence on visual acuity, a lesser risk of progression of PDR and fewer indications for PPV [27,45,58,71,72]. Another advantage of anti-VEGF agents is the exclusion of the risk of the complications that accompany PRP – i.e. loss of visual field, loss of night vision and

accommodative dysfunctions. In 50% of patients anti-VEGF therapy has demonstrated a reduction of NV and a reduction of the number of necessary subsequent PPV to 2–6 % (as against 15% in the case of PRP monotherapy) [17]. Anti-VEGF agents are administered within a fixed regimen or in a “treat and extend” regimen – with progressive extension of the therapeutic intervals – similarly as in the treatment of DME.

Disadvantages of anti-VEGF therapy are the higher price of treatment and the potential risks ensuing from intraocular administration of pharmaceuticals. Anti-VEGF is also less advantageous for patients with limited cooperation, in whom omission or discontinuation of treatment presents higher risks for the development of PDR than discontinuation and deferral of a planned PRP session [27,74,75].

Anti-VEGF therapy may also be considered in combination with classical methods in the case of neovascular glaucoma upon a background of DR, although the results of clinical trials are not yet conclusive [27,76].

Another possibility of the application of these preparations is recurring or newly occurring hemorrhage into the vitreous upon a background of PDR, even if no clear recommendations are yet available concerning the intervals of application and dosing [77–80].

The above-stated methods of treatment are so-called “reactive”, although the first studies demonstrating the benefit of prophylactic administration of anti-VEGF for advanced NPDR are now appearing [81].

Surgical treatment of DR – pars plana vitrectomy

We typically indicate surgical treatment in cases where laser or pharmacological treatment alone is insufficiently effective, or in the case that the opacity of the ocular media prevents any assessment of the condition of the vitreous and retina. In these cases PPV enables the subsequent

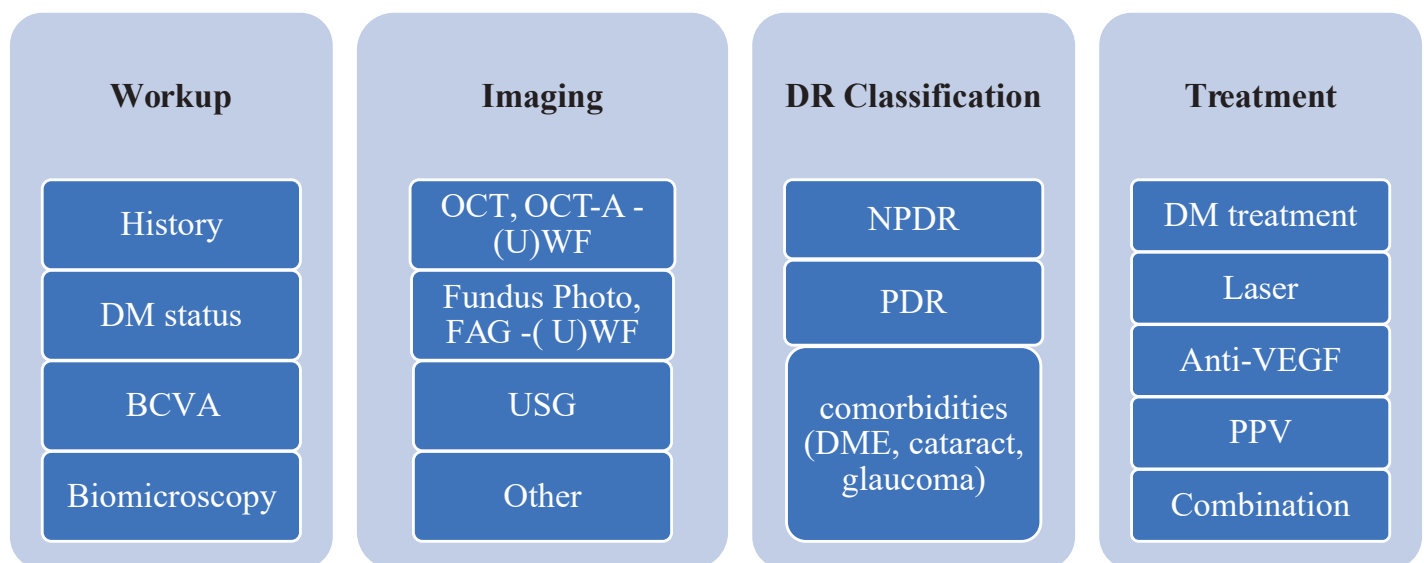


Figure 1. Diabetic retinopathy diagnostics and treatment

DM – diabetes mellitus, BCVA – best corrected visual acuity, OCT – optic coherent tomography, OCT-A – OCT angiography, FAG – fluorescein angiography, UWF – ultra wide field, USG – ultrasonography, NPDR – nonproliferative diabetic retinopathy, PDR – proliferative diabetic retinopathy, DME – diabetic macular edema, VEGF – vascular endothelial growth factor, PPV – pars plana vitrectomy

commencement of laser or other treatment. Indications of PPV for PDR have expanded markedly thanks to advances in surgical technology (suture-free system, modern surgical instruments, innovations in instrument technique, perioperative imaging methods and pre and perioperative use of intravitreal applications of anti-VEGF or corticoids). Advances in the instrument equipment and surgical techniques enable earlier indication for surgery, with lower risks of complications and quicker postoperative rehabilitation. The choice of surgical technique is strictly individual, according to the present pathology, experience of the operating surgeon and the possibilities of patient cooperation. The postoperative regime is also extremely important for the overall success of the operation – patient education, local pharmacological treatment, positioning and observation of patient.

INDICATIONS FOR PPV IN DR

- newly occurring hemophthalmos: stipulation of indication for PPV depends on a series of factors. In addition to the length of duration and the extent of hemophthalmos, it is also necessary to take into account the state of compensation of diabetes and associated diseases, the condition of the other eye

and any history of previous laser coagulation. For eyes without previous PRP, earlier indication for PPV is more advantageous than waiting for spontaneous resorption [27,82,83]

- recurrence of hemophthalmos following previous PPV: in addition to the objective finding and its dynamics, timing also depends on other supplementary examinations (ultrasound) and the patient's overall condition, stipulation of indication for re-operation is always at the discretion of the surgeon
- tractional and tractional-rhegmatogenous retinal detachment: a component of the operation is the complete removal of all pathological tissue, removal of the pathology of the vitreoretinal interface, gliovascular proliferations and performance or supplementing of PRP
- gliovascular retinovitreal and papillovitreal proliferation (OCT is significantly applied perioperatively)
- preretinal tractional membranes
- DME in the above-stated indications, not responding to intravitreal or anti-VEGF or corticoid treatment, in which pathology of the vitreoretinal interface is demonstrated. In connection with PPV for DME, the role of peeling of the membrane limitans interna (MLI) during the surgical procedure is often discussed. Even

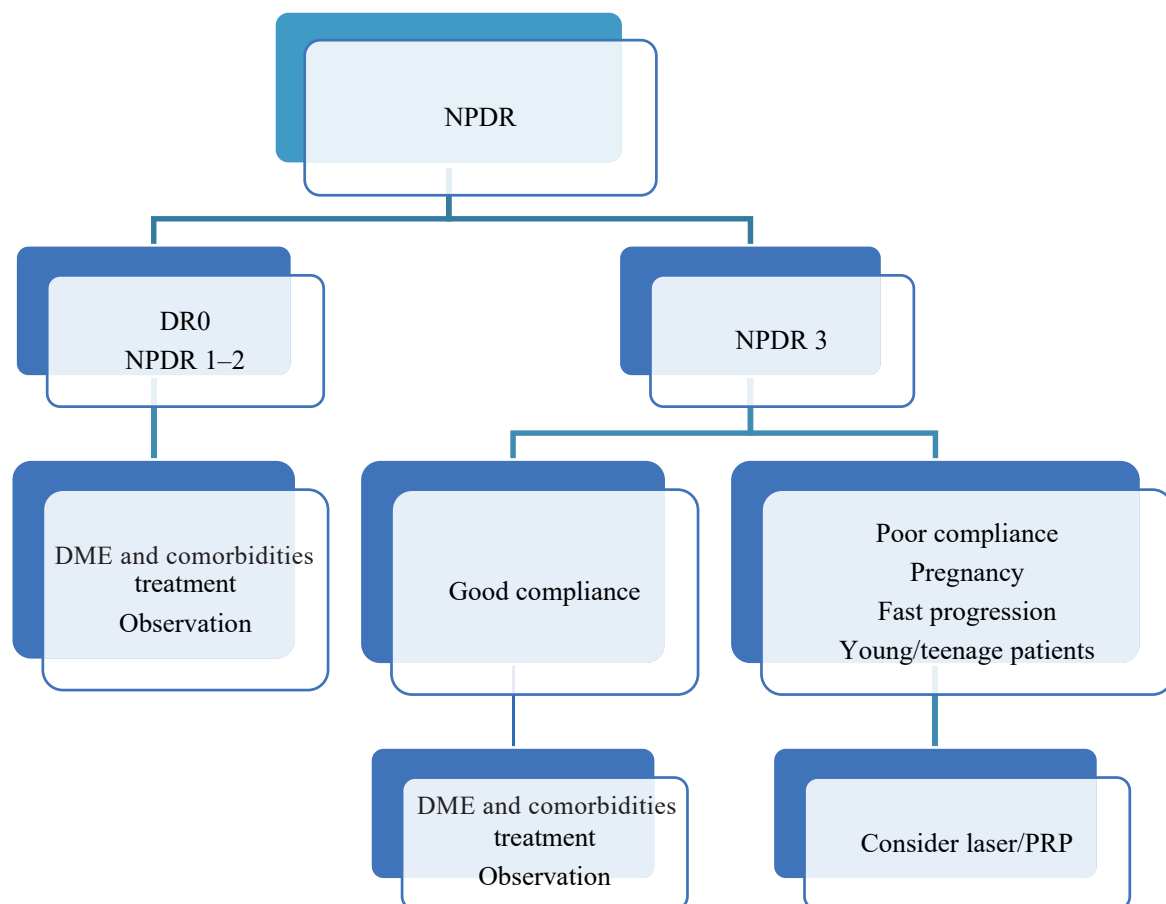


Figure 2. Management of NPDR treatment

** If both NPDR and DME are present, DME must be treated, preferably first. Combination therapy is effective and preferred in such cases (e.g. anti-VEGF + laser)*

DR – diabetic retinopathy, NPDR – nonproliferative DR, PRP – panretinal photocoagulation, DME – diabetic macular edema, VEGF – vascular endothelial growth factor

though it has been demonstrated in a series of studies that the MLI is markedly pathologically altered in patients with DME, there is no consensus of opinion regarding the essential importance of peeling as part of PPV. However, in general removal of clearly pathological MLI with tractional manifestations is considered useful [84–86]. It is known from experiences and literary data that a significant role for reducing edema is played by complete removal of the posterior cortical vitreous, which acts as a metabolic barrier to nutrition of the inner retinal layers [85,87]. A removed cortical vitreous and MLI from the macular region furthermore increase the sensitivity of the tissues to anti-VEGF or corticoid treatment [84,88–90].

Combined treatment of DR

From clinical trials there ensues an unequivocally positive effect of combining individual therapeutic options (laser, anti-VEGF therapy, PPV) on the course of DR. We may rationally assume that a combination of the above-mentioned methods shall lead to their synergic action, thereby increasing the therapeutic efficacy while at the same time reducing the burden on the patient. This synergic effect has already been unequivocally demonstrated in the case of PPV and endolaser photocoagulation of the retina.

COMBINED TREATMENT OF DR BY LASER AND ANTI-VEGF PREPARATIONS

It is advantageous to commence treatment of PDR with an initial saturating dose of anti-VEGF, and subsequently to perform full PRP [45,91], or to supplement laser coagulation in regions with hypoxia and nonperfusion and in regions where regression of NV does not occur despite anti-VEGF treatment. Such an approach brings markedly better results for the stabilization of PDR and improvement of visual acuity than PRP alone. In addition to reducing NV, anti-VEGF at the beginning of treatment reduces retinal edema and enables the performance of more sparing laser coagulation, with less trauma caused to the retina and a reduced risk of disorders of the visual field following PRP [60,61,92]. Combined treatment of anti-VEGF and PRP appears to be appropriate primarily where PDR occurs simultaneously with DME [45,60,93]. A reduction of the overall number of anti-VEGF injections has been demonstrated following supplementary laser coagulation [27,71].

COMBINED TREATMENT OF DR WITH ANTI-VEGF AND PPV (ANTI-VEGF ASSISTED PPV)

The question of indications of an anti-VEGF preparation before PPV is still a matter of discussion. So far only limited

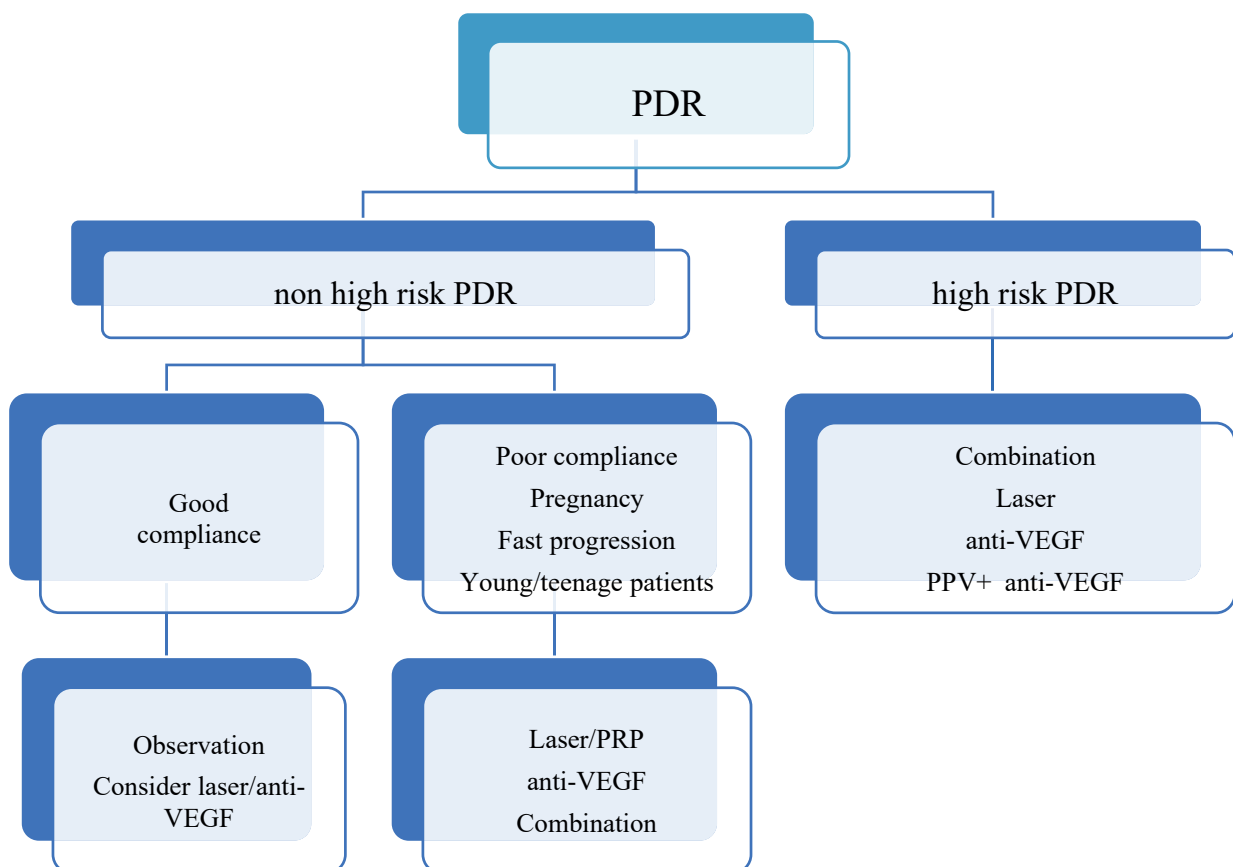


Figure 3. Management of PDR treatment

** If both PDR and DME are present, DME must be treated, preferably first. Combination therapy is effective and preferred in such cases (e.g. anti-VEGF + laser)*

PDR – proliferative diabetic retinopathy, PRP – panretinal photocoagulation, VEGF – vascular endothelial growth factor, PPV – pars plana vitrectomy

data is available from clinical trials which could demonstrate the effectiveness of anti-VEGF in the preoperative preparation before PPV. However, there are a large number of clinical trials which demonstrate the advantage of using anti-VEGF in the pre, peri and postoperative period [89,94–98]. Application of an anti-VEGF preparation 2–7 days before the planned operation limits the progression of intraocular hemorrhage in the period between the indication and the actual PPV procedure, reduces perioperative hemorrhage, eases removal of gliovascular membranes and reduces the risk of postoperative hemorrhage. This significantly reduces the operating time and also shortens postoperative rehabilitation [27]. This approach is especially advantageous for patients with type I diabetes with florid NV, which is frequently accompanied by perioperative or postoperative hemorrhage.

DIABETIC RETINOPATHY AND SPECIAL CIRCUMSTANCES

DR and pregnancy

DR may worsen due to physiological changes during pregnancy itself, and also as a consequence of decompensation of the internal environment and disorders of metabolic control of pregnant women [99,100,101].

- Eye examination is necessary before and during pregnancy
- Diagnosis and evaluation of the degree of DR and subsequent selection of an adequate monitoring regime and strategy of treatment is of key importance
- Pregnancy is not a contraindication for laser or surgical treatment (preference for local anesthesia)
- Application of anti-VEGF is controversial, though in in-

dividual cases administration may be considered (preferentially in 2nd half of pregnancy) [102]

- DR should not be a contraindication for natural vaginal birth [40,41,47]

DR and cataract surgery

It has been demonstrated that progression of both DR and DME may occur following cataract surgery [103,104]. As a result, the following recommendations are appropriate:

- in the case of incipient cataract, with good BCVA and a fundus which enables good examination, observation is appropriate [40]
- in the case of medium stage cataract, it is first of all appropriate to treat DR and DME, and following their stabilization to consider the performance of cataract surgery (if an improvement of vision can be expected) [40]
- in the case of advanced cataract which does not enable evaluation of the finding and applicable treatment of the retina, it is appropriate to perform timely cataract surgery with subsequent timely evaluation and treatment of the retina, and if applicable to perform combined cataract surgery and PPV with perioperative laser treatment of the retina [40]

DIAGRAM OF DIAGNOSIS AND TREATMENT OF DR AND ALGORITHMS OF DECISION-MAKING PROCEDURE

Diagrams of the diagnosis and treatment of DR and the algorithms of the decision-making procedure for NPDR and PDR are presented in Fig. 1–3.

REFERENCES

1. Diabetes is "a pandemic of unprecedented magnitude" now affecting one in 10 adults worldwide. *Diabetes Res Clin Pract.* 2021;181:109133.
2. Panozzo G, Cicinelli MV, Augustin AJ, et al. An optical coherence tomography-based grading of diabetic maculopathy proposed by an international expert panel: The European School for Advanced Studies in Ophthalmology classification. *Eur J Ophthalmol.* 2020;30(1):8-18.
3. Huang YT, Chang YC, Meng PP, et al. Optical Coherence Tomography Biomarkers in Predicting Treatment Outcomes of Diabetic Macular Edema After Dexamethasone Implants. *Front Med (Lausanne).* 2022;9:852022.
4. Cheung N, Mitchell P, Wong TY. Diabetic retinopathy. *Lancet.* 2010;376(9735):124-136.
5. Teo ZL, Tham YC, Yu M, et al. Global Prevalence of Diabetic Retinopathy and Projection of Burden through 2045: Systematic Review and Meta-analysis. *Ophthalmology.* 2021;128(11):1580-1591.
6. Jones CD, Greenwood RH, Misra A, Bachmann MO. Incidence and progression of diabetic retinopathy during 17 years of a population-based screening program in England. *Diabetes Care.* 2012;35(3):592-596.
7. Yau JW, Rogers SL, Kawasaki R, et al. Global prevalence and major risk factors of diabetic retinopathy. *Diabetes Care.* 2012;35(3):556-564.
8. Klein R, Knudtson MD, Lee KE, Gangnon R, Klein BE. The Wisconsin Epidemiologic Study of Diabetic Retinopathy XXIII: the twenty-five-year incidence of macular edema in persons with type 1 diabetes. *Ophthalmology.* 2009;116(3):497-503.
9. Stratton IM, Kohnner EM, Aldington SJ, et al. UKPDS 50: risk factors for incidence and progression of retinopathy in Type II diabetes over 6 years from diagnosis. *Diabetologia.* 2001;44(2):156-163.
10. Tight blood pressure control and risk of macrovascular and microvascular complications in type 2 diabetes: UKPDS 38. UK Prospective Diabetes Study Group. *Bmj.* 1998;317(7160):703-713.
11. Klein R, Klein BE, Moss SE, Davis MD, DeMets DL. The Wisconsin Epidemiologic Study of Diabetic Retinopathy. IX. Four-year incidence and progression of diabetic retinopathy when age at diagnosis is less than 30 years. *Arch Ophthalmol.* 1989;107(2):237-243.
12. Bhavsar AR, Tornambe PE. 25 years of progress in the treatment of retinal diseases: where we have been, where we are now, and where we will be. *Retina.* 2006;26(6 Suppl):S1-6.
13. Bhagat N, Grigorian RA, Tutela A, Zarbin MA. Diabetic macular edema: pathogenesis and treatment. *Surv Ophthalmol.* 2009;54(1):1-32.
14. Forrest IS, Chaudhary K, Paranjpe I, et al. Genome-wide polygenic risk score for retinopathy of type 2 diabetes. *Hum Mol Genet.* 2021;30(10):952-960.
15. Kuo JZ, Wong TY, Rotter JI. Challenges in elucidating the genetics of diabetic retinopathy. *JAMA Ophthalmol.* 2014;132(1):96-107.
16. Vseteckova P, Kvapil M, Majek O. Návrh doporučeného diagnostického a klinického postupu pro program screeningu diabetické retinopatie a makulárního edému u pacientů s diabetem na národní úrovni Praha: Národní screeningové centrum; 2021. Available from: <https://nsc.uzis.cz/zdraveoci/res/file/dokumenty/navrh-doporučeného-diagnostického-a-klinického-postupu-1.pdf>.
17. Early photocoagulation for diabetic retinopathy. ETDRS report number 9. Early Treatment Diabetic Retinopathy Study Research Group. *Ophthalmology.* 1991;98(5 Suppl):766-785.
18. Bek T. Diameter Changes of Retinal Vessels in Diabetic Retinopathy. *Curr Diab Rep.* 2017;17(10):82.
19. Ejaz S, Chekarova I, Ejaz A, Sohail A, Lim CW. Importance of pericytes and mechanisms of pericyte loss during diabetes retinopathy. *Diabetes Obes Metab.* 2008;10(1):53-63.

20. Beltramo E, Porta M. Pericyte loss in diabetic retinopathy: mechanisms and consequences. *Curr Med Chem*. 2013;20(26):3218-3225.
21. Sosna T. Historie diagnostiky a léčby diabetické retinopatie. [History of diagnosis and therapy of diabetic retinopathy]. *Vnitr Lek*. 2016;62(11 Suppl 4):S136-141. Czech
22. Huang H, He J, Johnson D, et al. Deletion of placental growth factor prevents diabetic retinopathy and is associated with Akt activation and HIF1 α -VEGF pathway inhibition. *Diabetes*. 2015;64(1):200-212.
23. Patel JJ, Hykin PG, Gregor ZJ, Boulton M, Cree IA. Angiopoietin concentrations in diabetic retinopathy. *Br J Ophthalmol*. 2005;89(4):480-483.
24. Adamis AP, Miller JW, Bernal MT, et al. Increased vascular endothelial growth factor levels in the vitreous of eyes with proliferative diabetic retinopathy. *Am J Ophthalmol*. 1994;118(4):445-450.
25. Caldwell RB, Bartoli M, Behzadian MA, et al. Vascular endothelial growth factor and diabetic retinopathy: pathophysiological mechanisms and treatment perspectives. *Diabetes Metab Res Rev*. 2003;19(6):442-455.
26. Shima DT, Adamis AP, Ferrara N, et al. Hypoxic induction of endothelial cell growth factors in retinal cells: identification and characterization of vascular endothelial growth factor (VEGF) as the mitogen. *Mol Med*. 1995;1(2):182-193.
27. Amoaku WM, Ghanchi F, Bailey C, et al. Diabetic retinopathy and diabetic macular oedema pathways and management: UK Consensus Working Group. *Eye (Lond)*. 2020;34(Suppl 1):1-51.
28. Barber AJ, Lieth E, Khin SA, Antonetti DA, Buchanan AG, Gardner TW. Neural apoptosis in the retina during experimental and human diabetes. Early onset and effect of insulin. *J Clin Invest*. 1998;102(4):783-791.
29. Sohn EH, van Dijk HW, Jiao C, et al. Retinal neurodegeneration may precede microvascular changes characteristic of diabetic retinopathy in diabetes mellitus. *Proc Natl Acad Sci U S A*. 2016;113(19):E2655-2664.
30. van Dijk HW, Kok PH, Garvin M, et al. Selective loss of inner retinal layer thickness in type 1 diabetic patients with minimal diabetic retinopathy. *Invest Ophthalmol Vis Sci*. 2009;50(7):3404-3409.
31. Silva PS, Cavallerano JD, Sun JK, Soliman AZ, Aiello LM, Aiello LP. Peripheral lesions identified by mydriatic ultrawide field imaging: distribution and potential impact on diabetic retinopathy severity. *Ophthalmology*. 2013;120(12):2587-2595.
32. Grading diabetic retinopathy from stereoscopic color fundus photographs—an extension of the modified Airlie House classification. ETDRS report number 10. Early Treatment Diabetic Retinopathy Study Research Group. *Ophthalmology*. 1991;98(5 Suppl):786-806.
33. Aiello LP, Oda I, Glassman AR, et al. Comparison of Early Treatment Diabetic Retinopathy Study Standard 7-Field Imaging With Ultrawide-Field Imaging for Determining Severity of Diabetic Retinopathy. *JAMA Ophthalmol*. 2019;137(1):65-73.
34. Verma A, Alagorie AR, Ramasamy K, et al. Distribution of peripheral lesions identified by mydriatic ultra-wide field fundus imaging in diabetic retinopathy. *Graefes Arch Clin Exp Ophthalmol*. 2020;258(4):725-733.
35. Silva PS, Cavallerano JD, Haddad NM, et al. Peripheral Lesions Identified on Ultrawide Field Imaging Predict Increased Risk of Diabetic Retinopathy Progression over 4 Years. *Ophthalmology*. 2015;122(5):949-956.
36. Schwartz R, Khalid H, Sivaprasad S, et al. Objective Evaluation of Proliferative Diabetic Retinopathy Using OCT. *Ophthalmol Retina*. 2020;4(2):164-174.
37. Grzybowski A, Borna P. Artificial Intelligence in Diabetic Retinopathy. In: Grzybowski A, editor. *Artificial Intelligence in Ophthalmology*. Cham: Springer International Publishing; 2021. p. 139-159.
38. Grzybowski A. Artificial intelligence for diabetic retinopathy screening. *Acta Ophthalmologica*. 2022;100(S275).
39. Grzybowski A. Promises and hazards of artificial intelligence. *Acta Ophthalmologica*. 2022;100(S275).
40. Wong TY, Sun J, Kawasaki R, et al. Guidelines on Diabetic Eye Care: The International Council of Ophthalmology Recommendations for Screening, Follow-up, Referral, and Treatment Based on Resource Settings. *Ophthalmology*. 2018;125(10):1608-1622.
41. Flaxel CJ, Adelman RA, Bailey ST, et al. Diabetic Retinopathy Preferred Practice Pattern®. *Ophthalmology*. 2020;127(1):P66-p145. doi: 10.1016/j.optha.2019.09.02542. Indications for photocoagulation treatment of diabetic retinopathy: Diabetic Retinopathy Study Report no. 14. The Diabetic Retinopathy Study Research Group. *Int Ophthalmol Clin*. 1987;27(4):239-253.
43. Photocoagulation treatment of proliferative diabetic retinopathy: the second report of diabetic retinopathy study findings. *Ophthalmology*. 1978;85(1):82-106.
44. Photocoagulation treatment of proliferative diabetic retinopathy. Clinical application of Diabetic Retinopathy Study (DRS) findings, DRS Report Number 8. The Diabetic Retinopathy Study Research Group. *Ophthalmology*. 1981;88(7):583-600.
45. Gross JG, Glassman AR, Jampol LM, et al. Panretinal Photocoagulation vs Intravitreal Ranibizumab for Proliferative Diabetic Retinopathy: A Randomized Clinical Trial. *Jama*. 2015;314(20):2137-2146.
46. Kalvodová B, Sosna T, Řehák J, et al. Doporučené postupy pro diagnostiku a léčbu diabetické retinopatie. [Recommendations for diagnosis and therapy of diabetic retinopathy]. *Cesk Slov Oftalmol*. 2012;68(6):236-241. Czech.
47. Kalvodová B, Sosna T, Ernest J, et al. Doporučené postupy pro diagnostiku a léčbu diabetické retinopatie. [Recommendations for diagnosis and therapy of diabetic retinopathy]. *Cesk Slov Oftalmol*. 2016;72(6):226-233. Czech.
48. Stratton IM, Cull CA, Adler AI, Matthews DR, Neil HA, Holman RR. Additive effects of glycaemia and blood pressure exposure on risk of complications in type 2 diabetes: a prospective observational study (UKPDS 75). *Diabetologia*. 2006;49(8):1761-1769.
49. Skyler JS, Bergenstal R, Bonow RO, et al. Intensive glycemic control and the prevention of cardiovascular events: implications of the ACCORD, ADVANCE, and VA diabetes trials: a position statement of the American Diabetes Association and a scientific statement of the American College of Cardiology Foundation and the American Heart Association. *Diabetes Care*. 2009;32(1):187-192.
50. Orchard TJ, Dorman JS, Maser RE, et al. Factors associated with avoidance of severe complications after 25 yr of IDDM. Pittsburgh Epidemiology of Diabetes Complications Study I. *Diabetes Care*. 1990;13(7):741-747.
51. Davis MD, Fisher MR, Gangnon RE, et al. Risk factors for high-risk proliferative diabetic retinopathy and severe visual loss: Early Treatment Diabetic Retinopathy Study Report #18. *Invest Ophthalmol Vis Sci*. 1998;39(2):233-252.
52. Uçgun NI, Yildirim Z, Kiliç N, Gürsel E. The importance of serum lipids in exudative diabetic macular edema in type 2 diabetic patients. *Ann NY Acad Sci*. 2007;1100:213-217.
53. Keech AC, Mitchell P, Summanen PA, et al. Effect of fenofibrate on the need for laser treatment for diabetic retinopathy (FIELD study): a randomised controlled trial. *Lancet*. 2007;370(9600):1687-1697.
54. Chew EY, Ambrosius WT, Davis MD, et al. Effects of medical therapies on retinopathy progression in type 2 diabetes. *N Engl J Med*. 2010;363(3):233-244.
55. Preliminary report on effects of photocoagulation therapy. The Diabetic Retinopathy Study Research Group. *Am J Ophthalmol*. 1976;81(4):383-396.
56. Fong DS, Girach A, Boney A. Visual side effects of successful scatter laser photocoagulation surgery for proliferative diabetic retinopathy: a literature review. *Retina*. 2007;27(7):816-824.
57. Muqit MM, Wakely L, Stanga PE, Henson DB, Ghanchi FD. Effects of conventional argon panretinal laser photocoagulation on retinal nerve fibre layer and driving visual fields in diabetic retinopathy. *Eye (Lond)*. 2010;24(7):1136-1142.
58. Sivaprasad S, Prevost AT, Vasconcelos JC, et al. Clinical efficacy of intravitreal aflibercept versus panretinal photocoagulation for best corrected visual acuity in patients with proliferative diabetic retinopathy at 52 weeks (CLARITY): a multicentre, single-blinded, randomised, controlled, phase 2b, non-inferiority trial. *Lancet*. 2017;389(10085):2193-2203.
59. Brucker AJ, Qin H, Antoszyk AN, et al. Observational study of the development of diabetic macular edema following panretinal (scatter) photocoagulation given in 1 or 4 sittings. *Arch Ophthalmol*. 2009;127(2):132-140.
60. Googe J, Brucker AJ, Bressler NM, et al. Randomized trial evaluating short-term effects of intravitreal ranibizumab or triamcinolone acetonide on macular edema after focal/grid laser for diabetic macular edema in eyes also receiving panretinal photocoagulation. *Retina*. 2011;31(6):1009-1027.
61. Preti RC, Ramirez LM, Monteiro ML, Carra MK, Pelayes DE, Takahashi WY. Contrast sensitivity evaluation in high risk proliferative diabetic retinopathy treated with panretinal photocoagulation associated or not with intravitreal bevacizumab injections: a randomised clinical trial. *Br J Ophthalmol*. 2013;97(7):885-889.
62. Subash M, Comyn O, Samy A, et al. The Effect of Multispot Laser Panretinal Photocoagulation on Retinal Sensitivity and Driving Eli-

- gibility in Patients With Diabetic Retinopathy. *JAMA Ophthalmol.* 2016;134(6):666-672.
63. Patel JI, Jenkins L, Benjamin L, Webber S. Dilated pupils and loss of accommodation following diode panretinal photocoagulation with sub-tenon local anaesthetic in four cases. *Eye (Lond).* 2002;16(5):628-632.
 64. Jain A, Blumenkranz MS, Paulus Y, et al. Effect of pulse duration on size and character of the lesion in retinal photocoagulation. *Arch Ophthalmol.* 2008;126(1):78-85.
 65. Blumenkranz MS, Yellachich D, Andersen DE, et al. Semiautomated patterned scanning laser for retinal photocoagulation. *Retina.* 2006;26(3):370-376.
 66. Muqit MM, Marcellino GR, Henson DB, et al. Single-session vs multiple-session pattern scanning laser panretinal photocoagulation in proliferative diabetic retinopathy: The Manchester Pascal Study. *Arch Ophthalmol.* 2010;128(5):525-533.
 67. Moutray T, Evans JR, Lois N, Armstrong DJ, Peto T, Azuara-Blanco A. Different lasers and techniques for proliferative diabetic retinopathy. *Cochrane Database Syst Rev.* 2018;3(3):Cd012314.
 68. Chappelaw AV, Tan K, Waheed NK, Kaiser PK. Panretinal photocoagulation for proliferative diabetic retinopathy: pattern scan laser versus argon laser. *Am J Ophthalmol.* 2012;153(1):137-142.e132.
 69. Nemcansky J, Stepanov A, Nemcanska S, Masek P, Langrova H, Studnicka J. Single session of pattern scanning laser versus multiple sessions of conventional laser for panretinal photocoagulation in diabetic retinopathy: Efficacy, safety and painfulness. *PLoS One.* 2019;14(7):e0219282.
 70. Němčanský J, Stepanov A, Němčanská S, Langrová H, Studnička J. Results of Treatment of Diabetic Retinopathy by the Laser System PASCAL. *Cesk Slov Oftalmol.* 2018;73(5-6):198-203.
 71. Sun JK, Glassman AR, Beaulieu WT, et al. Rationale and Application of the Protocol S Anti-Vascular Endothelial Growth Factor Algorithm for Proliferative Diabetic Retinopathy. *Ophthalmology.* 2019;126(1):87-95.
 72. Alagorie AR, Velaga S, Nittala MG, Yu HJ, Wykoff CC, Sadda SR. Effect of Aflibercept on Diabetic Retinopathy Severity and Visual Function in the RECOVERY Study for Proliferative Diabetic Retinopathy. *Ophthalmol Retina.* 2021;5(5):409-419.
 73. Chatziralli I, Loewenstein A. Intravitreal Anti-Vascular Endothelial Growth Factor Agents for the Treatment of Diabetic Retinopathy: A Review of the Literature. *Pharmaceutics.* 2021;13(8).
 74. Suresh R, Yu HJ, Thoveson A, et al. Loss to Follow-Up Among Patients With Proliferative Diabetic Retinopathy in Clinical Practice. *Am J Ophthalmol.* 2020;215:66-71.
 75. Obeid A, Gao X, Ali FS, et al. Loss to Follow-Up in Patients with Proliferative Diabetic Retinopathy after Panretinal Photocoagulation or Intravitreal Anti-VEGF Injections. *Ophthalmology.* 2018;125(9):1386-1392.
 76. Simha A, Aziz K, Braganza A, Abraham L, Samuel P, Lindsley KB. Anti-vascular endothelial growth factor for neovascular glaucoma. *Cochrane Database Syst Rev.* 2020;2(2):Cd007920.
 77. Antoszyk AN, Glassman AR, Beaulieu WT, et al. Effect of Intravitreal Aflibercept vs Vitrectomy With Panretinal Photocoagulation on Visual Acuity in Patients With Vitreous Hemorrhage From Proliferative Diabetic Retinopathy: A Randomized Clinical Trial. *Jama.* 2020;324(23):2383-2395.
 78. Sinawat S, Rattanapakorn T, Sanguansak T, Yospaiboon Y, Sinawat S. Intravitreal bevacizumab for proliferative diabetic retinopathy with new dense vitreous hemorrhage after full panretinal photocoagulation. *Eye (Lond).* 2013;27(12):1391-1396.
 79. Wirkkala J, Bloigu R, Hautala NM. Intravitreal bevacizumab improves the clearance of vitreous haemorrhage and visual outcomes in patients with proliferative diabetic retinopathy. *BMJ Open Ophthalmol.* 2019;4(1):e000390.
 80. Lim JW, Lee SJ, Sung JY, Kim JS, Nam KY. Effect of prophylactic anti-VEGF injections on the prevention of recurrent vitreous hemorrhage in PDR patients after PRP. *Sci Rep.* 2022;12(1):14484.
 81. Brown DM, Wykoff CC, Boyer D, et al. Evaluation of Intravitreal Aflibercept for the Treatment of Severe Nonproliferative Diabetic Retinopathy: Results From the PANORAMA Randomized Clinical Trial. *JAMA Ophthalmol.* 2021;139(9):946-955.
 82. Fassbender JM, Ozkok A, Canter H, Schaal S. A Comparison of Immediate and Delayed Vitrectomy for the Management of Vitreous Hemorrhage due to Proliferative Diabetic Retinopathy. *Ophthalmic Surg Lasers Imaging Retina.* 2016;47(1):35-41.
 83. Glassman AR, Beaulieu WT, Maguire MG, et al. Visual Acuity, Vitreous Hemorrhage, and Other Ocular Outcomes After Vitrectomy vs Aflibercept for Vitreous Hemorrhage Due to Diabetic Retinopathy: A Secondary Analysis of a Randomized Clinical Trial. *JAMA Ophthalmol.* 2021;139(7):725-733.
 84. Bressler SB, Melia M, Glassman AR, et al. Ranibizumab Plus Prompt or Deferred Laser for Diabetic Macular Edema in Eyes with Vitrectomy before Anti-vascular Endothelial Growth Factor Therapy. *Retina.* 2015;35(12):2516-2528.
 85. Flaxel CJ, Edwards AR, Aiello LP, et al. Factors associated with visual acuity outcomes after vitrectomy for diabetic macular edema: diabetic retinopathy clinical research network. *Retina.* 2010;30(9):1488-1495.
 86. Haller JA, Qin H, Apte RS, et al. Vitrectomy outcomes in eyes with diabetic macular edema and vitreomacular traction. *Ophthalmology.* 2010;117(6):1087-1093.
 87. Chatziralli I, Dimitriou E, Theodossiadis G, et al. Intravitreal ranibizumab versus vitrectomy for recurrent vitreous haemorrhage after pars plana vitrectomy for proliferative diabetic retinopathy: a prospective study. *Int Ophthalmol.* 2020;40(4):841-847.
 88. Iglicki M, Busch C, Lanzetta P, et al. Vitrectomized vs non-vitrectomized eyes in DEX implant treatment for DMO-Is there any difference? the VITDEX study. *Eye (Lond).* 2022.
 89. Wang JK, Huang TL, Chang PY, et al. Comparison of Intravitreal Dexamethasone Implant and Ranibizumab in Vitrectomized Eyes with Diabetic Macular Edema. *J Ophthalmol.* 2021;2021:8882539.
 90. Boyer DS, Faber D, Gupta S, et al. Dexamethasone intravitreal implant for treatment of diabetic macular edema in vitrectomized patients. *Retina.* 2011;31(5):915-923.
 91. Sameen M, Khan MS, Mukhtar A, Yaqub MA, Ishaq M. Efficacy of intravitreal bevacizumab combined with pan retinal photocoagulation versus panretinal photocoagulation alone in treatment of proliferative diabetic retinopathy. *Pak J Med Sci.* 2017;33(1):142-145.
 92. Velaga SB, Nittala MG, Brown T, et al. Longitudinal Change in Retinal Layer Thicknesses in Subjects with Proliferative Diabetic Retinopathy Treated with Intravitreal Aflibercept. *Investigative Ophthalmology & Visual Science.* 2019;60(9):5325-5325.
 93. Mirshahi A, Roohipoor R, Lashay A, Mohammadi SF, Abdoallahi A, Faghihi H. Bevacizumab-augmented retinal laser photocoagulation in proliferative diabetic retinopathy: a randomized double-masked clinical trial. *Eur J Ophthalmol.* 2008;18(2):263-269.
 94. Guan J, Cai N, Liu LM, Zhao N, Liu NN. Ranibizumab Pretreatment in Vitrectomy with Internal Limiting Membrane Peeling on Diabetic Macular Edema in Severe Proliferative Diabetic Retinopathy. *Diabetes Ther.* 2020;11(6):1397-1406.
 95. Wang DY, Zhao XY, Zhang WF, Meng LH, Chen YX. Perioperative anti-vascular endothelial growth factor agents treatment in patients undergoing vitrectomy for complicated proliferative diabetic retinopathy: a network meta-analysis. *Sci Rep.* 2020;10(1):18880.
 96. Zhao XY, Xia S, Chen YX. Antivascular endothelial growth factor agents pretreatment before vitrectomy for complicated proliferative diabetic retinopathy: a meta-analysis of randomised controlled trials. *Br J Ophthalmol.* 2018;102(8):1077-1085.
 97. Russo A, Longo A, Avitabile T, et al. Incidence and Risk Factors for Tractional Macular Detachment after Anti-Vascular Endothelial Growth Factor Agent Pretreatment before Vitrectomy for Complicated Proliferative Diabetic Retinopathy. *J Clin Med.* 2019;8(11).AN 1960, doi: 10.3390/jcm8111960
 98. Cui J, Chen H, Lu H, et al. Efficacy and Safety of Intravitreal Conbercept, Ranibizumab, and Triamcinolone on 23-Gauge Vitrectomy for Patients with Proliferative Diabetic Retinopathy. *J Ophthalmol.* 2018;2018:4927259.
 99. Klein BE, Moss SE, Klein R. Effect of pregnancy on progression of diabetic retinopathy. *Diabetes Care.* 1990;13(1):34-40.
 100. Chew EY, Mills JL, Metzger BE, et al. Metabolic control and progression of retinopathy. The Diabetes in Early Pregnancy Study. National Institute of Child Health and Human Development Diabetes in Early Pregnancy Study. *Diabetes Care.* 1995;18(5):631-637.
 101. Effect of pregnancy on microvascular complications in the diabetes control and complications trial. The Diabetes Control and Complications Trial Research Group. *Diabetes Care.* 2000;23(8):1084-1091.
 102. Chandrasekaran PR, Madanagopalan VG, Narayanan R. Diabetic retinopathy in pregnancy - A review. *Indian J Ophthalmol.* 2021;69(11):3015-3025.
 103. Haddad NM, Sun JK, Abujaber S, Schlossman DK, Silva PS. Cataract surgery and its complications in diabetic patients. *Semin Ophthalmol.* 2014;29(5-6):329-337.
 104. Shah AS, Chen SH. Cataract surgery and diabetes. *Curr Opin Ophthalmol.* 2010;21(1):4-9.