

RETROSPECTIVE ANALYSIS OF THE PRESENCE OF CHOROIDAL NEOVASCULARISATION USING OPTICAL COHERENCE TOMOGRAPHY ANGIOGRAPHY IN THE TREATMENT OF CHRONIC CENTRAL SEROUS CHORIORETINOPATHY WITH THE AID OF PHOTODYNAMIC THERAPY

Myslík Manethová K.^{1,2}, Ernest J.¹

¹Department of Ophthalmology, Military University Hospital, Prague, Czech Republic

²Department of Ophthalmology, Thomayer University Hospital, Prague, Czech Republic

The authors of the study declare that no conflict of interests exists in the compilation, theme and subsequent publication of this professional communication, and that it is not supported by any pharmaceuticals company. The study has not been submitted to any other journal or printed elsewhere, with the exception of congress abstracts and recommended procedures.

Presentation: Treatment of chronic central serous chorioretinopathy with the aid of photodynamic therapy – structural prognostic factors (Manethová K., Ernest J., Hrevuš M., Románek J.), 19th Congress of Czech Vitreoretinal Association, 29.–30.11.2019, Mikulov.

Received: 18 January 2021

Accepted: 8 March 2021

Available on-line: 15 June 2021



MUDr. Kateřina Myslík Manethová, FEBO
Fakultní Thomayerova nemocnice
Videňská 800
140 00 Praha 4 – Krč
E-mail: katerina.manethova@ftn.cz

SUMMARY

Purpose: Analysis of the presence of choroidal neovascularization (CNV) by optical coherence tomography angiography (OCTA) in eyes treated with photodynamic therapy in a reduced dosing regimen (HD-PDT, half dose of verteporfin) for the chronic form of central serous chorioretinopathy (cCSC).
Materials and methods: Retrospective evaluation of OCTA findings in 54 eyes of 52 patients treated for cCSC with HD-PDT. OCTA was performed on Angioplex Zeiss Cirrus 5000 (Carl Zeiss Meditec, Dublin, CA, USA) 1 year after HD-PDT to verify changes typical of cCSC. By analyzing the results of this examination, we evaluated in particular the presence or absence of concomitant CNV and the correlation of the present CNV with the average resulting best corrected visual acuity (BCVA).

Results: We analyzed the OCTA findings of 54 eyes (52 patients), in which we demonstrated the presence of concomitant CNV in 35 eyes (35.2%). Revealed CNV occurred in 82% below the undulating hyperreflective RPE line. In eyes with CNV, the mean BCVA (72 letters ETDRS) was statistically significantly lower than in eyes without CNV (82.7 letters ETDRS) ($p = 0.0179$).

Conclusion: In our retrospective evaluation of a group of patients who underwent HD-PDT for cCSC, we demonstrated with OCTA the presence of CNV in 35.2% eyes 1 year after the treatment. We believe that the presence of type I CNV is a complication of the chronic disease itself rather than an adverse effect of HD-PDT.

Key words: chronic central serous chorioretinopathy, half-dose photodynamic therapy, optical coherence tomography angiography, choroidal neovascularization

Čes. a slov. Oftal., 77, 2021, No.3, p. 122–131

INTRODUCTION

Central serous chorioretinopathy (CSC) is a pathology of the posterior segment of the eye, characterised by serous detachment of the neuroretina, which may be accompanied by ablation of the retinal pigment epithelium

(RPE) [1]. The course of the pathology may be of various characters: acute, recurrent, chronic [2]. CSC most often affects younger men but may be diagnosed also in older patients of both sexes. Photodynamic therapy in a reduced dosing regimen appears to be a safe and effective method of treating the chronic form of central serous

chorioretinopathy (cCSC) [3,4,5]. The main diagnostic tools include optical coherence tomography (OCT), fluorescein angiography (FAG) and indocyanine green angiography (ICG). The finding on fluorescein angiography shows typical leakage; in the case of acute form of CSC, FAG most often shows an image of focal leakage via a breached RPE (of the type of “smokestacks” or “inkblot”), and chronic stages are typified rather by broad deposits of hyperfluorescence, often of the character of diffuse retinal pigment epitheliopathy (DRPE) [1,6]. ICG examination usually detects dilation and increased permeability of the choroidal vessels, with multiple diffuse deposits of hyperfluorescence [7]. OCT, in particular “enhanced-deep imaging” (EDI), shows the presence of subretinal fluid, the character of detachment of the RPE and increased choroidal thickness [8]. CSC may be complicated by the onset of CNV [9]. CNV ranks among the main causes of deterioration of visual functions in patients with CSC [10]. However, in the case of CSC this complication is unfortunately very difficult to detect by means of the regular examinations (OCT, FAG and ICG). Furthermore, cCSC and occult type CNV especially share several common features on FAG and OCT. Optical coherence tomography angiography (OCTA) is a modern, fast, non-invasive method with a high-resolution capacity, which appears to be an ideal supplementary examination technique for patients with CSC. The essence of OCTA is detection of changes in blood flow of the retinal and choroidal vascular bed (in an otherwise static eye), without the necessity to use a contrast substance [11]. OCTA images can be studied by isolated segmentation in different vascular layers, which enables detailed analysis of the vascular structure, without distortion as a consequence of pooling or leakage of dye [12,13]. It ensues from recent clinical trials that although CNV is not entirely demonstrable in standard examinations with the aid of OCT/FAG/ICG, it may be detected in CSC precisely thanks to this entirely new and revolutionary diagnostic method [12,14]. The aim of this study is to analyse OCTA findings produced 1 year after photodynamic therapy with a half dose of verteporfin (HD-PDT) in patients treated for cCSC.

The main aim of this study is to conduct a retrospective analysis of the presence of CNV with the aid of OCTA in 52 patients (54 eyes) treated for cCSC with HD-PDT at the Department of Ophthalmology, 1st Faculty of Medicine, Charles University and Central Military Hospital – Military University Hospital in Prague in the period of 2014–2018.

MATERIAL AND METHOD

HD-PDT (Visudyne; Novartis AG, Bülach, Switzerland, dose 3 mg/m²) was indicated as the primary treatment for symptomatic forms of CSC persisting for longer than 3 months, in which a spontaneous resorption of subretinal fluid (SRT) did not take place, or in the case of insufficient effect of conservative therapy. An OCTA examina-

tion was conducted 12 months after the performance of HD-PDT and was a part of the final examination at the end of the observation period in patients who had undergone treatment with the aid of HD-PDT for cCSC.

Before the performance of reduced HD-PDT, all the patients met the following entry criteria: patient age above 18 years; on OCT presence of SRT or ablation of RPE for a minimum period of 3 months; presence of active hyperfluorescence on FAG typical of cCSC; presence of choroidal vascular hyperpermeability and abnormally dilated choroidal vessels on ICG. At the same time, before the performance of HD-PDT the following exclusion criteria were absent: signs of CNV on baseline imaging methods; signs of other macular pathology (age-related macular degeneration, angioid streaks, polypoidal choroidal vasculopathy, pathological myopia, tilted disk etc.); non-transparent optic media preventing quality performance of all examinations; previous performance of HD-PDT, laser treatment or intravitreal application of anti-VEGF 3 months before performance of HD-PDT.

Before the performance of HD-PDT, the following examinations were performed: BCVA on ETDRS optotypes, measurement of intraocular tension, slit lamp examination and biomicroscopy, examination using HRA+OCT Spectralis machine (Heidelberg Engineering, Heidelberg, Germany): SD-OCT protocol – scan width 20° x 20°, 49 high resolution horizontal linear volume scans centred on fovea, FAG/ICG protocol – 30° high resolution images focused on macular area. On the basis of these examinations, cCSC was confirmed, defined as a diffuse region of hyperfluorescence in the macular area with serous detachment of the RPE and/or neuroepithelium, or as a spot of hyperfluorescence localised within an area of up to 500 µm from the centre of the fovea, contraindicated for lesion laser photocoagulation, in which spontaneous resorption of SRT did not occur. The patients were subsequently indicated for the performance of HD-PDT, which we implemented at the latest within 30 days of the baseline examinations. They were then observed and examined 1, 3, 6 and 12 months after the performance of HD-PDT. At the end of the observation period (12 months after HD-PDT) the following examinations were performed: follow-up examination of BCVA, intraocular tension and the anterior and posterior segment of the eye (biomicroscopically), OCT examination in “follow-up” format and also examination with the aid of OCTA. OCTA scans of the macula with a size of 3 x 3 mm were performed on the instrument Angioplex Zeiss Cirrus 5000 (Carl Zeiss Meditec, Inc., Dublin, OH, USA) for verification of changes typical of cCSC. In order to obtain images that could be well evaluated, only quality OCTA examinations with a signal strength of 7 out of 10 were included in the evaluation. In the OCTA images 2 independent evaluators (KM, JE) analysed abnormal flow through the retinochoroidal vascular bed, the character of the retinal layers and the presence or absence of concomitant CNV. We also performed a stati-

stical correlation of present CNV with average resulting BCVA at the end of the observation period. The patients were evaluated with OCTA retrospectively, because at the time of initiation of the clinical evaluation we did not have the device available at our centre.

The retrospective analysis for the presence of CNV using the OCTA method covered an evaluation of 54 of 52 patients (40 men, 12 women) with an average age of 50.1 years (median 49.5, range 30–75 years), who were treated with HD-PDT for a diagnosis of cCSC at the Department of Ophthalmology of the 1st Faculty of Medicine of Charles University and the Central Military Hospital-University Military Hospital in Prague. The patients were indicated for HD-PDT on the basis of baseline examinations at which the diagnosis was determined as fundamental pathology of cCSC with a

minimum duration of 3 months. The average length of duration of the pathology at the time of treatment was 11.5 months (range 3–120 months). Based on the baseline OCT/FAG/ICG examinations we determined the point source of leakage in 6 eyes (11.1%), diffuse area of hyperfluorescence in 48 eyes (88.9%), and we did not register the presence of CNV in any case in the baseline examinations. The average value of baseline BCVA before treatment was 68.91±10.5 ETDRS letters (median 71; in an interval from 35 to 85 ETDRS letters) and the average value of baseline CRT was 385.6±118.5 µm (median 367.5 µm; within range of 245 µm to 1000 µm). Table 1.

Statistical analysis of data

For a comparison of the incidence of CNV in eyes with signs of undulating RPE and signs of RPE atrophy, a chi-

Table 1. Baseline demographic characteristics, overview of parameters of 54 eyes affected by chronic central serous chorioretinopathy before and 12 months after treatment with half-dose photodynamic therapy, OCT and OCTA analysis 12 months after treatment

Baseline demographic characteristics		P value
number of treated eyes (n)	54	
male (n)	40	
female (n)	12	
mean age ± SD (years)	50.1±10.4	
mean duration of disease (months)	11.5	
mean number of HD-PDT sessions (n)	1.07	
mean size of HD-PDT spot ± SD (µm)	1352±421	
Parameters before and 12 months after HD-PDT		
BCVA at baseline ± SD (ETDRS letters)	68.9±10.5	
BCVA 12 months after HD-PDT ± SD (ETDRS letters)	79.0±11.0	p<0.0001
CRT at baseline ± SD ± SD (µm)	385.3±118.5	
CRT 12 months after HD-PDT ± SD (µm)	263.5±52	p<0.0001
OCT and OCTA analysis 12 months after HD-PDT		
undulating RPE (n, %)	17 (31.5%)	
diffuse retinal pigment epithelopathy (n, %)	24 (44.4%)	
CNV (n, %)	19 (35.2%)	
type I (n)	19	
type II (n)	0	
presence of CNV under undulating RPE (n, %)	14 (82%)	p<0.0001
presence of CNV under RPE atrophy (n, %)	14 (59%)	p = 0.0008
BCVA of patients without CNV ± SD (ETDRS letters)	82.7±7.2	
BCVA of patients with CNV ± SD (ETDRS letters)	72.0±13.4	p = 0.0179
mean age of patients with CNV ± SD (years)	59±6.3	

SD – standard deviation, HD-PDT – half-dose photodynamic therapy, BCVA – best corrected visual acuity, CRT – central retinal thickness, OCT – optical coherence tomography, OCTA – optical coherence tomography angiography, CNV – choroidal neovascularisation, RPE – retinal pigment epithelium, ETDRS – Early Treatment Diabetic Retinopathy Study

-quadrat test of dependency was used in a contingency table. A non-parametric t-test was used for comparison of the differences in measured values of BCVA (in 12M) in the groups given by the presence and absence of CNV. The non-parametric t-tests were selected for the reason of breach of the expectation of normality. A bilateral alternative hypothesis and a 5% level of significance was selected for the statistical testing. The stated P values were adjusted by Benjamini-Hochberg correction for multiple testing.

RESULTS

Our evaluation included 54 eyes of 52 patients, in whom a diagnosis of cCSC was determined on the basis of a comprehensive examination (Fig. 1 A, B and 2 A, B). The development of best corrected visual acuity and the change of central retinal thickness in this cohort of pa-

tients were the subject of already previously published study [4]. We achieved an improvement of BCVA from a baseline value of 68.9 ± 10.5 ETDRS letters (median 71, range 35–85) to a value of 79 ± 11 ETDRS letters (median 82, range 38–93) at the end of the observation period. This represented a statistically significant improvement of BCVA ($p < 0.0001$). There was an analogous reduction of the average baseline value of CRT from 385.3 ± 118.5 μm (median 367.5 μm ; range from 245 μm to 1000 μm) to a value of 263.5 ± 52 μm (median 258.5 μm ; range 162–404 μm) at the end of the observation period. The reduction of CRT 12 months after treatment was also statistically significant ($p < 0.0001$).

The average number of HD-PDT sessions in this cohort was 1.07 (range 1–2). The average size of the used laser beam was 1352 μm (within an interval of 800 μm to 2800 μm). We performed irradiation by a single spot in 45 eyes (83.3%), in the remaining 9 eyes (16.7%) we

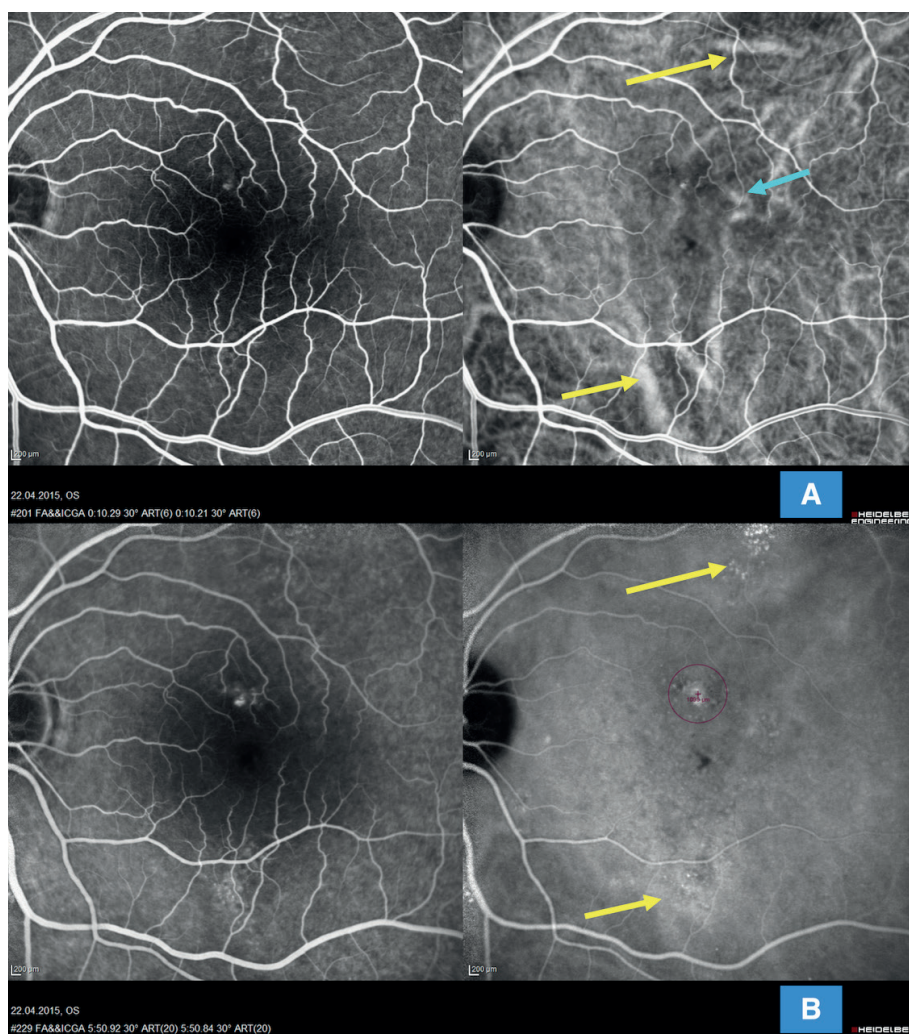


Fig. 1. Multimodal imaging of chronic form of central serous chorioretinopathy in 52-year-old patient with extrafoveolar lesions (HRA-OCT Spectralis Heidelberg). (A) Simultaneous image of fluorescein and indocyanine green angiography showing early arteriovenous phase with marked dilatation of choroidal vessels extrafoveolarly (yellow arrows) and perifoveolarly (blue arrow); diffuse disruption of choriocapillaris in central area is evident, image does not show presence of choroidal neovascularisation. (B) Simultaneous image of fluorescein and indocyanine green angiography showing late venous phase of angiogram with marked diffusion hyperfluorescence foci especially in indocyanine imaging (yellow arrows) and marked spot for reduced photodynamic therapy at site of diffuse active foci (purple circle)

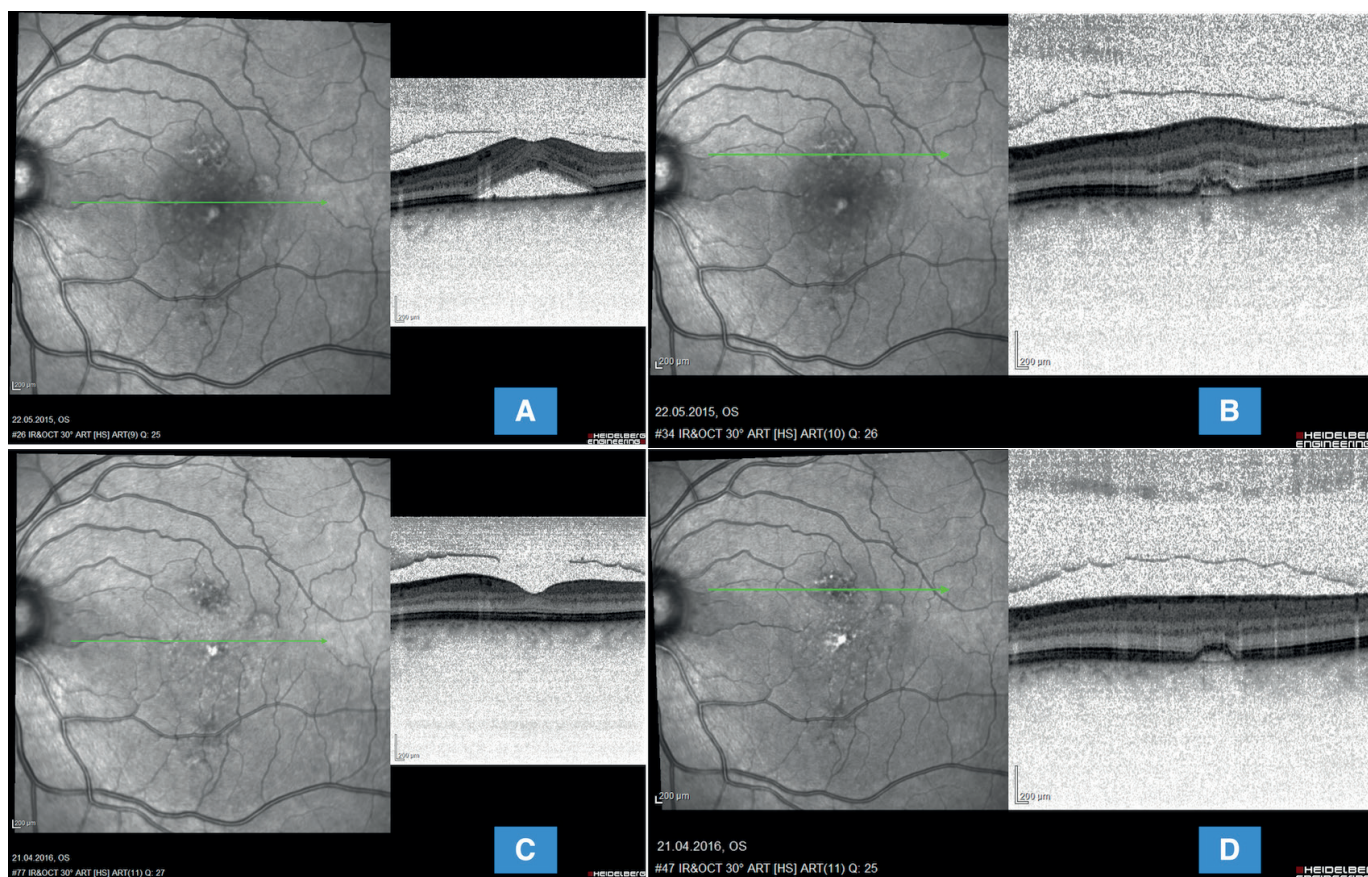


Fig. 2. Optical coherence tomography of same patient (HRA-OCT Spectralis Heidelberg). (A) shows a transfoveal linear scan of high serous detachment of neuroretina with already dystrophically altered photoreceptors (but relatively well preserved individual retinal layers). (B) shows a transretinal linear scan of an active leaking lesion of undulating retinal pigment epithelium with mild exudative activity before performing reduced photodynamic therapy. (C) 1 year after performing reduced photodynamic therapy the image shows complete absorption of subretinal fluid, restoration of interdigitation zone and distinct regular retinal pigment epithelium subfoveolarly and (D) irregular undulating retinal pigment layer remains in place of original active lesion without signs of activity

irradiated multiple active areas with 2 laser spots in one session. In 43 eyes (79.6%) we achieved complete resorption of SRT after the actual performance of HD-PDT (Fig. 2 C,D). We recorded incomplete resorption of SRT in the remaining 11 eyes (20.4%), in which after a time interval additional therapy was chosen, specifically the application of an anti-VEGF injection into the vitreous space in 7 cases, in 1 eye HD-PDT was repeated after an interval of 3 and more months, and in 3 cases a combined approach was chosen, namely repetition of HD-PDT after an interval of 3 and more months with application of an anti-VEGF into the vitreous space. At the end of the observation period, we achieved a satisfactory result without exudative activity in 49 eyes (90.7%).

From our cohort of 54 eyes with cCSC treated with the aid of HD-PDT, in 2 cases we detected the onset of complicating CNV within one month of the performance of the procedure in the place of irradiation of the CSC lesion, the activity of which we demonstrated by angiography at the baseline examination. We evaluate these 2 cases as a complication of treatment. In both cases this concerned subfoveal or juxtafoveal

small (but highly active) type II CNV (according to the older nomenclature designated as classic CNV). Patients with developed secondary CNV were treated with anti-VEGF therapy (aflibercept); in one case anatomical adjustment practically ad integrum occurred, with regression of the classic portion of the neovascular complex, in the second case a small inactive fibrovascular juxtafoveal scar formed.

Results of OCTA examination

At the end of the observation period, thus 12 months after the performance of HD-PDT, we examined all 54 eyes using an OCTA machine. Both independent evaluators concurred on demonstration of concomitant CNV in 19 eyes (35.2%). The average age in patients with demonstrated CNV was 59 years (range 45–75).

Through a sub-analysis of the character of the retinal layers on OCT B-scans and their correlation with regard to the presence of CNV demonstrated on OCTA as abnormal flow in the individual retinochoroidal layers, we came to the following conclusions:

- correlation of incidence of CNV in eyes with signs of undulating hyperreflective RPE (Fig. 3): in patients

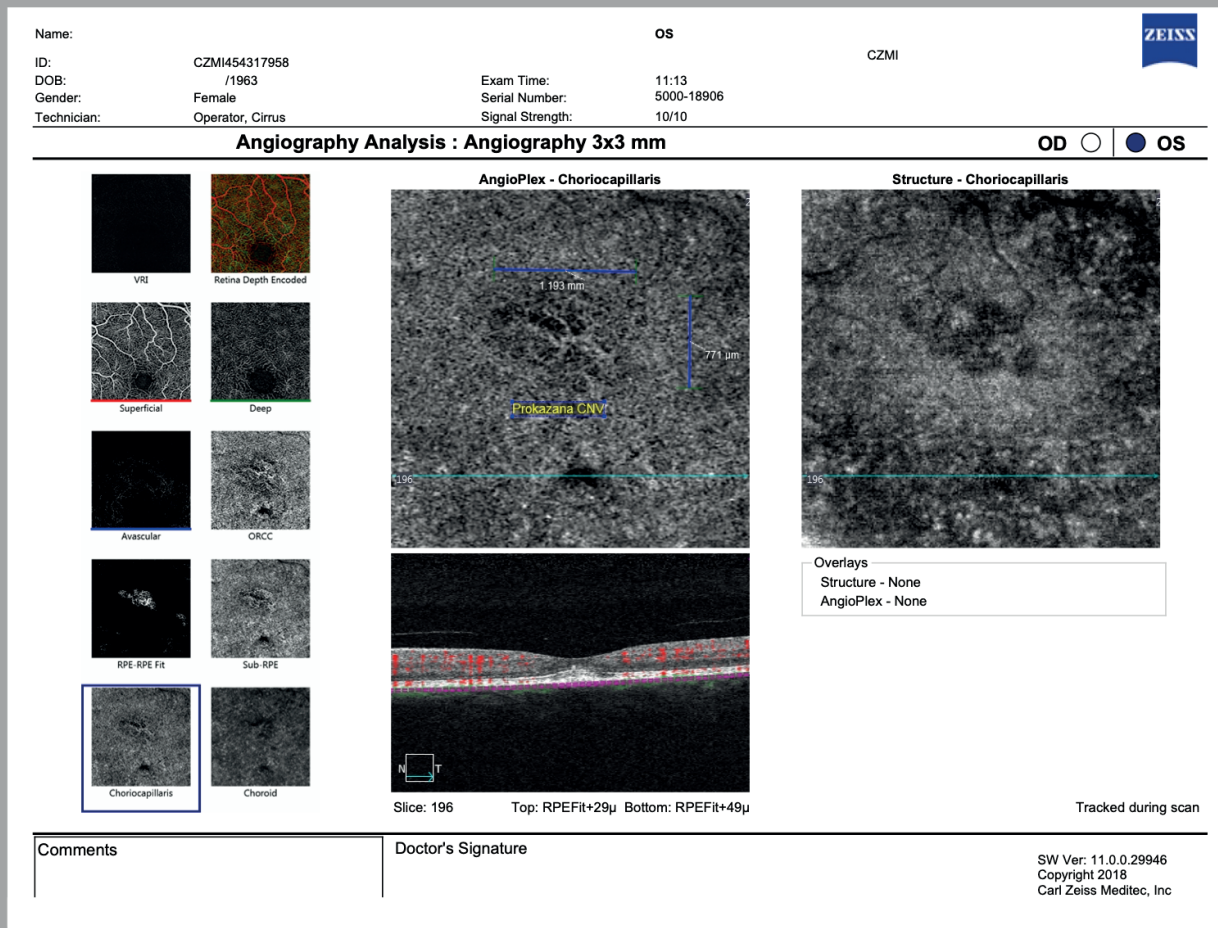


Fig. 3. Optical coherence tomography angiography of same patient 1 year after reduced photodynamic therapy (AngioPlex Zeiss Cirrus 5000, Carl Zeiss Meditec): inactive choroidal neovascularisation is clearly visible at original active site under undulating retinal pigment epithelium in choriocapillaris zone (yellow arrow)

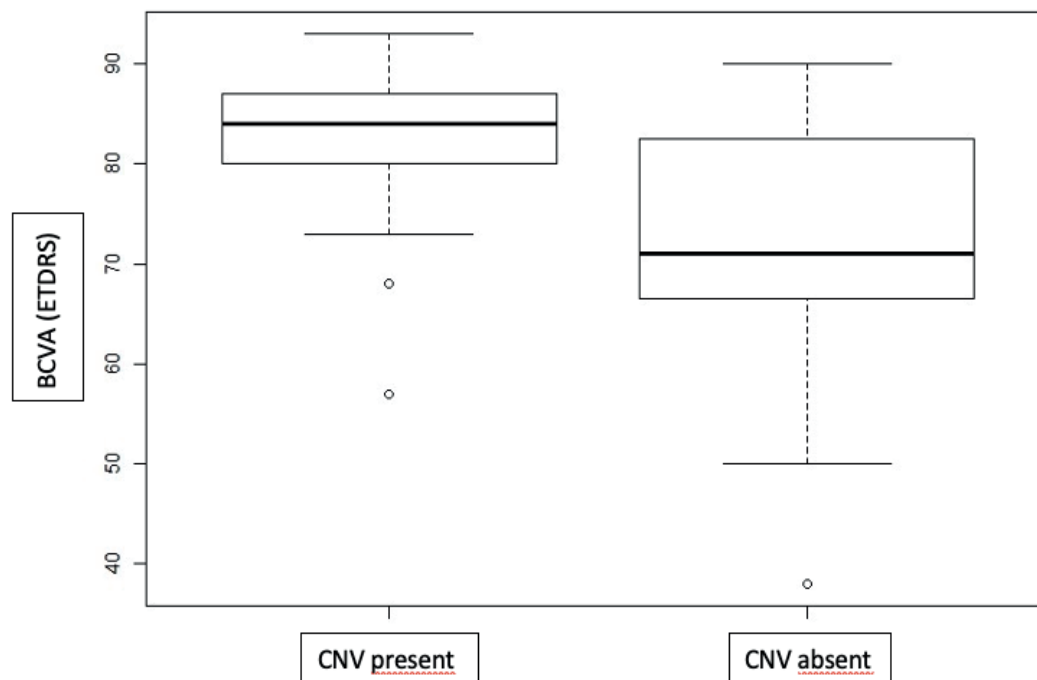
with a finding of undulating hyperreflective RPE a line with CNV appears to a very high degree (82%) in comparison with patients in whom undulating RPE was not observed on OCT images (14%). This difference is statistically significant ($p < 0.0001$).

- correlation of incidence of CNV in eyes with signs of RPE atrophy: in patients with RPE atrophy, CNV appears to a high degree (59%) in comparison with patients without RPE atrophy (11 %). This difference is statistically significant ($p = 0.0008$).
- correlation of present CNV to average resulting BCVA: in patients with appearance of CNV, average BCVA at the end of the observation period is 72 ETDRS letters; this value is statistically significantly lower ($p = 0.0179$) than in patients without CNV, in whom average BCVA at the end of the observation period is 82.7 ETDRS letters (Graph 1).

DISCUSSION

Chronic form of CSC is linked with persistent subretinal exudation, progressive irreversible changes of the

retina, and corresponding long-term deterioration of central visual acuity. Chronic or recurrent CSC may be a protracted illness, and as a consequence of long-term persistent separation of the neuroretina leads to functional changes accompanied by dysfunction of the RPE cells, subretinal exudates and fibrosis [15], cystoid macular degeneration [16], and complicating CNV [12,17]. The precise cause of the occurrence of CSC remains unclear. It is assumed that abnormal choroidal vessels play a key role in the pathogenesis of this disease [18,19]. Increased choroidal thickness, visible on EDI-OCT [8], and increased choroidal permeability, demonstrated on ICG, have led a series of authors to the hypothesis that treatment targeted precisely at these areas of pathologically altered choroidal vessels may be effective in the therapy of CSC [20,21]. Even despite convincing results of several prospective clinical trials, at present no gold standard of treatment of this pathology yet exists. Opinions of experts differ on the speed of commencement of treatment, how radical it should be and the choice of the most appropriate therapeutic procedure. It is a question for discussion as to whether treatment should



Graph 1. Box plot showing difference between values of best corrected visual acuity in patients without demonstrated choroidal neovascularisation and in patients in whom presence of choroidal neovascularisation was demonstrated by optical coherent tomography angiography

BCVA – best corrected visual acuity, ETDRS – Early Treatment Diabetic Retinopathy Study, CNV – choroidal neovascularisation

be commenced earlier than after 3 months, when we await spontaneous healing. The results of our study show a high percentage of complications of the disease, above all the presence of CNV, either due to primary or secondary causes. We expect that timely commencement of treatment can help prevent these complications with a higher degree of effectiveness.

Photodynamic therapy in a standard dosing regimen was the first method of choice in the treatment of cCSC; although the anatomical and functional results are satisfactory in many international publications [21,22,23], the use of conventional PDT may lead to more frequent occurrence of complications – RPE atrophy, choriocapillaris hypoperfusion, early hypoxia of chorioretinal tissue and onset of secondary CNV [22]. Some authors believe that the use of PDT in a more sparing regimen (reduced-dose, reduced-fluence or mutual combination thereof, rPDT) brings similar anatomical and functional results, but with a better safety profile and minimum of the aforementioned adverse effects [24,25,26]. They view the principle of effect of rPDT as consisting in the remodelling of the choroidal channel, with reduction of infiltration of the choroidal vessels, rather than in their occlusion [27].

However, photodynamic therapy may have potential side effects such as RPE atrophy, RPE crack, sub-RPE haemorrhage, choroidal ischemia or secondary CNV [22,27,28]. The majority of patients in whom these complications were described were treated by PDT in a standard dosing regimen [29]. With regard to the fact that the anatomical and functional results

are comparable between standard and HD-PDT, it appears that HD-PDT is a safer method [25,30]. Fujita et al. did not observe any cases of complicating CNV in a cohort of 204 eyes treated with HD-PDT [25], similarly to Karakus et al., who treated 27 eyes by the same method [31]. By contrast with these authors, Tseng describes the occurrence of complicating CNV in connection with HD-PDT in 2 out of 56 eyes (3.6%) [32]. In our study also, manifestly demonstrated complicating CNV developed in 2 eyes (3.7%) within one month of the performance of treatment, in both cases this concerned type II CNV (i.e. small classic CNV) in the place of radiation with PDT spot. The development of secondary CNV in cCSC has been described especially in connection with standard PDT or laser photocoagulation, but CNV may be a complication of cCSC itself [2,22,33]. On the assumption that our study included only patients in whom the baseline examination (OCT/FAG/ICG) did not demonstrate the presence of CNV, we consider the occurrence of CNV within 1 month of the performance of HD-PDT in our cohort of patients to represent a complication of this treatment. A further matter that convinces us of this conclusion is the fact that CNV occurring upon a background of long-term cCSC is as a rule type I neovascularisation, namely occult CNV [12].

In recent years the association between CNV and cCSC has been a central theme of several clinical evaluations. CNV may develop upon a background of recurrent or chronic CSC – chronic alterations of the Bruch's membrane and RPE are the main causes

of the occurrence of CNV. Up to 2015, the published incidence of CNV in cCSC was in 2–9%, in which more than 80 % of CNV occurred in persons older than 50 years [10,33]. Until now, diagnosis of CNV upon a background of CSC has been difficult due to the accompanying clinical symptoms (RPE ablation, subretinal or intraretinal fluid, dens RPE changes, RPE atrophy), causing obscuring or a window effect in standard FAG/ICG/OCT examinations [12,30]. The recent advance in multimodal imaging, especially the revolutionary technique of OCT angiography (OCTA), eases the identification of type I CNV located above areas of pronouncedly thickened choroidea (visible on EDI-OCT) and zones of increased permeability of the choroidal vessels (visible on ICG) [9]. Bonini-Filho declared high sensitivity and 100% identification of CNV using OCTA [12]. Authors who have used OCTA for demonstration of CNV upon a background of cCSC have identified the presence of complicating CNV with a far higher frequency than upon the use of standard examination methods [13,34,35]. Costanzo demonstrated secondary CNV upon a background of cCSC with the aid of OCTA in 8 out of 32 eyes (24.2 %) [34]. Quaranta-El Maftouhi even identified presence of CNV in 58 % of patients with cCSC, in whom a chorioneovascular network was clearly manifest on OCTA, although no signs of CNV were visible on FAG or ICG [13].

On the basis of the new observations, we decided to conduct a retrospective evaluation of our cohort of 54 eyes treated for cCSC using the HD-PDT method at the end of the observation period (12 months after treatment) with the aid of OCTA. In 19 out of 54 eyes (35.2%), the 2 independent evaluators concurred on the presence of an abnormal plexus with a different flow, which manifested signs of CNV type I, in which 82% of such demonstrated abnormal choroidal vessels were located beneath a hyperreflective undulating layer of RPE. In the literature available to date, an irregular undulating hyperreflective RPE in CSC is considered of high risk for the demonstration of an underlying type I CNV [14,36]. However, maximum caution should be exercised in the interpretation of a finding of abnormal choroidal vessels as CNV, because the pathology itself is characterised by changes of the choroidal vessels. We believe that an irregular pattern of choroidal vessels and pathological choroidal vasculature may correspond both to abnormally dilated vessels, and to CNV. From our cohort of patients, we exactly recorded a choroidal abundantly branching and anastomosing vascular network in 19 patients, in whom the finding was then evaluated as type I CNV. The presence of CNV is a negative prognostic factor for the final functional result of treatment [23]. In our cohort also, patients with demonstrated CNV had significantly lower BCVA at the end of the observation period.

However, a question still remains as to whether CNV in these patients appeared as a result of long-term il-

ness or as a complication of performed HD-PDT therapy. In his study, Costanzo compared the presence of secondary CNV in treatment-naive patients and in already treated patients; among these groups he did not record a significant difference relating to the demonstration of CNV [34]. Rabiolo focused on functional-structural changes before and after HF-PDT therapy, demonstrated with multimodal imaging techniques. Very surprisingly, no significant change was recorded on OCTA following HF-PDT on the level of the choroicapillaris, Sattler's or Haller's layer [37]. These results indicate that in comparison with standard PDT, reduced performance of PDT is effective, without causing significant damage to the choroidal vascular architecture or risking subsequent post-laser hypoxia. For this reason, we believe that also in the case of our 19 patients, the presence of CNV is more probably a complication of the chronic disease itself rather than an adverse effect of treatment. An exception relates to the above 2 cases, in which type II CNV occurred in direct connection (within 1 month) with HD-PDT. However, even in these two eyes, at the end of the observation period, after complete pacification of the finding without exudative activity, a wider lesion of type I CNV was demonstrated, on the basis of which complicating type II CNV had evidently occurred immediately following HD-PDT. For this reason, we believe that demonstration of CNV upon a background of CSC becomes especially important before planned PDT treatment with regard to the fact that PDT may potentially initiate hypoxia, and thereby also greater expression of VEGFs, and thus activate clinically hitherto passive neovascularisation. The presence of secondary CNV upon a background of CSC may thus lead to an adjustment of therapeutic strategy. In our cohort of patients, due to the unsatisfactory effect of HD-PDT alone, an anti-VEGF injection was applied intravitreally to 10 eyes, with a positive anatomical and functional effect. Through a retrospective evaluation of the OCTA findings in these eyes, in 8 out of 10 cases (80 %) we demonstrated the presence of type I CNV, which corresponds with the results published by Pichi [36].

CSC itself is not linked with a higher level of VEGF in the vitreous body, and no overall effect of anti-VEGF preparations has been demonstrated in CSC without the presence of CNV [38]. However, the situation may be different in complicated cases of secondary CNV as a complication of long-term chronic CSC. Previous clinical trials have demonstrated an anatomical and functional effect of bevacizumab, ranibizumab and aflibercept in the treatment of CNV associated with CSC [39,40,41]. Data demonstrating the safety and efficacy of combined PDT and anti-VEGF therapy is very limited. Asahi demonstrated positive results of combined therapy of HD-PDT + aflibercept in patients who did not respond to conventional treatment (laser photocoagulation, PDT monotherapy, anti-VE-

GF monotherapy). He recorded greater success in eyes with complicating CNV [42].

We consider the advantages of our evaluation to be the complete one-year observation period in all patients, statistically assessable data, and the relatively

large and consistent cohort of patients treated and observed by 1 examiner. Limiting factors of this study include retrospective evaluation, OCTA examination only at the end of the observation period and the absence of a control group.

LITERATURE

1. Maumenee AE. Macular diseases: clinical manifestations. *Trans Am Acad Ophthalmol Otolaryngol.* 1965;69:605-613.
2. Daruich A, Matet A, Dirani A, et al. Central serous chorioretinopathy: recent findings and new physiopathology hypothesis. *Prog Retin Eye Res.* 2015;48:82-118.
3. Lai TY, Chan WM, Li H, Lai RY, Liu DT, Lam DS. Safety enhanced photodynamic therapy with half dose verteporfin for chronic central serous chorioretinopathy: a short term pilot study. *Br J Ophthalmol.* 2006;90:869-874.
4. Manethová K, Ernest J, Hrevuš M, Jirásková N. Assessment of the efficacy of photodynamic therapy in patients with chronic central serous chorioretinopathy. *Cesk Slov Oftalmol.* 2020;75(6):298-308. doi:10.31348/2019/62
5. Nicoló M, Eandi CM, Alovisei C, et al. Half-fluence versus half-dose photodynamic therapy in chronic central serous chorioretinopathy. *Am J Ophthalmol.* 2014;157(5):1033-1037.
6. Gass JDM. Pathogenesis of disciform detachment of the neuroepithelium. *Am J Ophthalmol.* 1967;63(3):Suppl:1-139.
7. Uyama M, Matsunaga T, Matsubara I, Fukushima I, Takahashi K, Nishimura T. Indocyanine green angiography and pathophysiology of multifocal posterior pigment epitheliopathy. *Retina.* 1999;19(1):12-21.
8. Imamura Y, Fujiwara T, Margolis R, Spaide RF. Enhanced depth imaging optical coherence tomography of the choroid in central serous chorioretinopathy. *Retina.* 2009;29(10):1469-1473.
9. Fung AT, Yannuzzi LA, Freund KB. Type 1 (sub-retinal pigment epithelial) neovascularization in central serous chorioretinopathy masquerading as neovascular age-related macular degeneration. *Retina.* 2012;32(9):1829-1837.
10. Loo RH, Scott IU, Flynn HW Jr, et al. Factors associated with reduced visual acuity during long-term follow-up of patients with idiopathic central serous chorioretinopathy. *Retina.* 2002;22(1):19-24.
11. Spaide RF, Klancnik JM, Cooney MJ. Retinal vascular layers imaged by fluorescein angiography and optical coherence tomography angiography. *JAMA Ophthalmol.* 2015;133(1):45-50.
12. Bonini Filho MA, de Carlo TE, Ferrara D, et al. Association of Choroidal Neovascularization and Central Serous Chorioretinopathy With Optical Coherence Tomography Angiography. *JAMA Ophthalmol.* 2015;133(8):899-906.
13. Quaranta-El Maftouhi M, El Maftouhi A, Eandi CM. Chronic central serous chorioretinopathy imaged by optical coherence tomographic angiography. *Am J Ophthalmol.* 2015;160(3):581-587.
14. Bousquet E, Bonnin S, Mrejen S, Krivosic V, Tadayoni R, Gaudric A. Optical Coherence Tomography Angiography of Flat Irregular Pigment Epithelium Detachment in Chronic Central Serous Chorioretinopathy. *Retina.* 2018;38(3):629-638.
15. Le D, Yannuzzi LA, Spaide RF, Rabb MF, Blair NP, Daily MJ. Subretinal exudative deposits in central serous chorioretinopathy. *Br J Ophthalmol.* 1993;77(6):349-353.
16. Iida T, Yannuzzi LA, Spaide RF, Borodoker N, Carvalho CA, Negro S. Cystoid macular degeneration in chronic central serous chorioretinopathy. *Retina.* 2003;23(1):1-7.
17. Manayath GJ, Shah VS, Saravanan VR, Narendran V. Polypoidal choroidal vasculopathy associated with central serous chorioretinopathy: Pachychoroid Spectrum of Diseases. *Retina.* 2018;38(6):1195-1204.
18. Nicholson B, Noble J, Forooghian F, Meyerle C. Central serous chorioretinopathy: update on pathophysiology and treatment. *Surv Ophthalmol.* 2013;58(2):103-126.
19. Prunte C, Flammer J. Choroidal capillary and venous congestion in central serous chorioretinopathy. *Am J Ophthalmol.* 1996;121(1):26-34.
20. Maruko I, Iida T, Sekiryu T, Saito M. Morphologic changes in the outer layer of the detached retina in rhegmatogenous retinal detachment and central serous chorioretinopathy. *Am J Ophthalmol.* 2009;147(3):489-494.e1.
21. Yannuzzi LA, Slakter JS, Gross NE, et al. Indocyanine green angiography-guided photodynamic therapy for treatment of chronic central serous chorioretinopathy: a pilot study. *Retina.* 2003;23(3):288-298.
22. Cardillo Piccolino F, Eandi CM, Ventre L, Rigault de la Longrais RC, Grignolo FM. Photodynamic therapy for chronic central serous chorioretinopathy. *Retina.* 2003;23(6):752-763.
23. Moon JW, Yu HG, Kim TW, Kim HC, Chung H. Prognostic factors related to photodynamic therapy for central serous chorioretinopathy. *Graefes Arch Clin Exp Ophthalmol.* 2009;247(10):1315-1323.
24. Alkin Z, Perente I, Ozkaya A, et al. Comparison of efficacy between low-fluence and half-dose verteporfin photodynamic therapy for chronic central serous chorioretinopathy. *Clin Ophthalmol.* 2014;5(8):685-690.
25. Fujita K, Imamura Y, Shinoda K, et al. One-year outcomes with half-dose verteporfin photodynamic therapy for chronic central serous chorioretinopathy. *Ophthalmology.* 2015;122(3):555-561.
26. Kim YK, Ryoo NK, Woo SJ, Park KH. Comparison of visual and anatomical outcomes of half-fluence and half-dose photodynamic therapy in eyes with chronic central serous chorioretinopathy. *Graefes Arch Clin Exp Ophthalmol.* 2015;253(12):2063-2073.
27. Chan WM, Lam DS, Lai TY, Tam BS, Liu DT, Chan CK. Choroidal vascular remodelling in central serous chorioretinopathy after indocyanine green guided photodynamic therapy with verteporfin: a novel treatment at the primary disease level. *Br J Ophthalmol.* 2003;87(12):1453-1458.
28. Colucciello M. Choroidal neovascularization complicating photodynamic therapy for central serous retinopathy. *Retina.* 2006;26(2):239-242.
29. Lim JI, Glassman AR, Aiello LP, Chakravarthy U, Flaxel CJ, Spaide RF. Collaborative retrospective macula society study of photodynamic therapy for chronic central serous chorioretinopathy. *Ophthalmology.* 2014;121(5):1073-1078.
30. Dansingani KK, Balaratnasingam C, Klufas MA, Sarraf D, Freund KB. Optical Coherence Tomography Angiography of Shallow Irregular Pigment Epithelial Detachments In Pachychoroid Spectrum Disease. *Am J Ophthalmol.* 2015;160(6):1243-1254.e2.
31. Karakus SH, Basarir B, Pinarci EY, Kirandi EU, Demirok A. Long-term results of half-dose photodynamic therapy for chronic central serous chorioretinopathy with contrast sensitivity changes. *Eye (Lond).* 2013;27(5):612-620.
32. Tseng CC, Chen SN. Long-term efficacy of half-dose photodynamic therapy on chronic central serous chorioretinopathy. *Br J Ophthalmol.* 2015;99(8):1070-1077.
33. Spaide RF, Campeas L, Haas A, et al. Central serous chorioretinopathy in younger and older adults. *Ophthalmology.* 1996;103(12):2070-2079.
34. Costanzo E, Cohen SY, Miere A, et al. Optical Coherence Tomography Angiography in Central Serous Chorioretinopathy. *J Ophthalmol.* 2015;2015:134783. doi:10.1155/2015/134783
35. Teussink MM, Breukink MB, van Grinsven MJ, et al. OCT Angiography Compared to Fluorescein and Indocyanine Green Angiography in Chronic Central Serous Chorioretinopathy. *Invest Ophthalmol Vis Sci.* 2015;56(9):5229-5237.
36. Pichi F, Morara M, Veronese C, Ciardella AP. The overlapping spectrum of flat irregular pigment epithelial detachment investigated by optical coherence tomography angiography. *Int Ophthalmol.* 2018;38(3):975-983.
37. Rabiolo A, Zucchiatti I, Marchese A, et al. Multimodal retinal imaging in central serous chorioretinopathy treated with oral eplerenone or photodynamic therapy. *Eye (Lond).* 2018;32(1):55-66.
38. Lim JW, Kim MU, Shin MC. Aqueous humor and plasma levels of vas-

- cular endothelial growth factor and interleukin-8 in patients with central serous chorioretinopathy. *Retina*. 2010;30(9):1465-1471.
39. Broadhead GK, Chang A. Intravitreal aflibercept for choroidal neovascularisation complicating chronic central serous chorioretinopathy. *Graefes Arch Clin Exp Ophthalmol*. 2015;253(6):979-981.
40. Chan WM, Lai TY, Liu DT, Lam DS. Intravitreal bevacizumab (avastin) for choroidal neovascularization secondary to central serous chorioretinopathy, secondary to punctate inner choroidopathy, or of idiopathic origin. *Am J Ophthalmol*. 2007;143(6):977-983.
41. Konstantinidis L, Mantel I, Zografos L, Ambresin A. Intravitreal ranibizumab in the treatment of choroidal neovascularization associated with idiopathic central serous chorioretinopathy. *Eur J Ophthalmol*. 2010;20(5):955-958.
42. Asahi MG, Chon AT, Gallemore E, Gallemore RP. Photodynamic therapy combined with antivascular endothelial growth factor treatment for recalcitrant chronic central serous chorioretinopathy. *Clin Ophthalmol*. 2017;11:2051-2056.