

# CYCLOCRYOCOAGULATION IN SECONDARY NEOVASCULAR GLAUCOMA AND OUR RESULTS

Tarková A.<sup>1</sup>, Hejsek L.<sup>3</sup>, Jirásková N.<sup>1</sup>, Studnička J.<sup>1,2</sup>

<sup>1</sup>Department of Ophthalmology, Faculty of Medicine, Charles University and University Hospital Hradec Králové, Czech Republic

<sup>2</sup>VISUS, s.r.o., Police nad Metují, Czech Republic

<sup>3</sup>European Eye Clinic Lexum, Czech Republic

*The authors of the study hereby declare that no conflict of interests exists in the compilation, theme and subsequent publication of this professional article, and that it is not supported by any pharmaceuticals company. The article has not been submitted to any other journal or printed elsewhere.*

Received: 24 November 2020

Accepted: 7 February 2021

Available on-line: 15 June 2021



MUDr. Anna Tarková  
Oční klinika Fakultní nemocnice  
Hradec Králové  
Sokolská 581  
500 05 Hradec Králové  
E-mail: anna.tarkova@gmail.com

## SUMMARY

**Purpose:** To retrospectively evaluate the use of cyclocryocoagulation (CCC) in secondary neovascular glaucomas performed at the Department of Ophthalmology, Faculty of Medicine, Charles University and University Hospital Hradec Králové in the years 2016–2019.

**Material and methods:** In a retrospective study, 30 procedures of 26 eyes of 24 patients were evaluated. All patients underwent CCC surgery. The main entry criteria were the presence of secondary neovascular glaucoma in diabetes or on the basis of occlusion of the retinal artery or vein and subsequent dispensarization of the patient in the 1st and 6th month after the operation. The parameters evaluated were: the best-corrected visual acuity (BCVA), intraocular pressure value (IOP), data of pain and change in the number of active substances of antiglaucoma therapy.

**Results:** The mean age of patients at the time of the procedure was 62 years (range 22–85 years). The average number of procedures per eye was 1.15 out of a total of 30 procedures, 26 eyes were performed on 24 patients. The most common indication for CCC in secondary glaucoma-vascular complications in diabetes were in 21 procedures, vascular complications – after occlusion of the retinal vein or artery were in 9 cases. Two patients had both eyes operated on within one year. Three patients underwent two procedures on the same eye during the study period. One of them had two procedures on both eyes. The average value of the number of active substances of antiglaucoma drugs decreased from 3.10 to 2.87 after the 1st month ( $p = 0.318$ ) and after 6 months it was 2.6 ( $p < 0.05$ ). The average IOP value decreased from 34.67 mmHg to 18.43 mmHg after the 1st month ( $p < 0.05$ ) and after 6 months to 17.90 mmHg ( $p < 0.05$ ). The mean value of BCVA increased from 0.135 to 0.138 after the 1st month ( $p = 0.444$ ) and after 6 months it decreased to 0.096 ( $p = 0.170$ ). One month from the procedure, the average value of pain remained the same as the pre-surgery average value of the pain. No patients reported pain 6 months after the procedure.

**Conclusion:** Our results correspond to the results of large clinical studies. We showed a statistically significant difference in the reduction of the number of active substances of antiglaucoma drugs and the reduction of intraocular pressure after 6 months after the procedure. All patients stopped reporting pain after the procedure.

**Key words:** secondary neovascular glaucoma, cyclocryocoagulation, intraocular pressure, vision, pain, antiglaucoma therapy

Čes. a slov. Oftal., 77, 2021, No.3, p 138–143

## INTRODUCTION

Secondary glaucoma is the term used to designate any form of glaucoma in which the cause can be identified as increased intraocular pressure, which leads to damage to the optic nerve and loss of sight. Glaucoma may develop several years after the onset of an acquired disorder, which may primarily affect the eye or be a part of a systemic pathology. As a result, it is important to be aware of these relationships. The mechanisms leading to glaucoma are generally similar to those which occur in congenital conditions, and more than one mechanism may contribute to the development or progression of glaucoma.

As in primary glaucoma, secondary glaucoma also may be in open-angle or angle-closure form and may appear in one eye or bilaterally [1].

Neovascular glaucoma is a serious ocular pathology, which is classified as secondary glaucoma. It is caused by a number of ocular and systemic conditions which share a common element of retinal ischemia or hypoxia, which initiates a subsequent release of angiogenic factors. It is characterised by increased ocular pressure as a consequence of neovascularisation occurring in the iridocorneal angle and the iris. The most common causes of neovascular glaucoma are diabetic retinopathy and occlusion of the central retinal vein, carotid artery and central retinal artery.

In rarer cases it may be upon a background of ocular tumours, traumas and uveitis. It is important to ensure timely diagnosis and treatment of this pathology [2,3]. The type of treatment depends on the fundamental cause, but usually incorporates conservative therapy, laser or conventional surgery.

Cyclodestructive methods are traditionally used in glaucomas which are unresponsive to pharmaceutical and surgical therapy [4]. They lead to a reduction of intraocular pressure (IOP) by reducing the production of intraocular fluid by the ciliary body. There are three basic approaches to cyclodestruction: cyclocryocoagulation (CCC), trans-scleral laser cycloablation and endoscopic laser cycloablation. All three techniques have the common goal of reducing the quantity of intraocular fluid, and all share the potential side effects of inflammation (including possible sympathetic ophthalmia), ineffective treatment or excessive treatment resulting in hypotonia and even phthisis bulbi. Although there is no uniform consensus, the majority of surgeons reserve cycloablation procedures for cases of refractory glaucomas, or in cases which are unsuitable for procedures that improve the drainage of intraocular fluid, such as angle surgery, glaucoma drainage implants and trabeculectomy [5].

The first surgical methods for reducing the production of intraocular fluid triggered by damage to the ciliary body are dated to the beginning of the twentieth century. In 1950, Bietti described cyclocryotherapy on the reduction of IOP. However, this procedure was linked with severe pain. Nevertheless, the mechanism of freezing did not become popular until 1968, when Roethth demonstrated the success of CCC on patients with uncontrollable IOP. It subsequently became an accepted and widely used method [6,7,8]. However, until recently cyclodestructive procedures (e.g., CCC, trans-scleral photocoagulation by diode laser and endoscopic laser cycloablation) were reserved for patients with refractory glaucoma, who had low visual acuity. Advancing technological innovations led to the development of promising, safer and less destructive techniques such as micropulse diode cyclophotocoagulation, endoscopic cyclophotocoagulation and ultrasound cyclodestruction. These newer methods were soon used on patients with less severe glaucoma and good visual potential [9].

CCC incorporates the freezing of the ciliary body from an external approach. During repeated cyclocryotherapy sessions, it is necessary to ensure that at least one quadrant is treated, because upon excessive therapy chronic hypotonia or phthisis bulbi may result [5]. The aim of the study is to evaluate our own results of the treatment of refractory secondary glaucomas by cyclocryocoagulation.

## MATERIAL AND METHOD

A retrospective study evaluated 30 procedures on 26 eyes of 24 patients. Of these 8 were women (33.3%) and 16 were men (66.7%). Two patients had both eyes operated on during the course of one year. Three patients had

two operations during the course of the observation period, on the same eye for the same reason. One of them had two operations on each eye. During the stipulated observation period, the CCC procedure was performed a total of 116 times at our centre. We had to exclude a total number of 86 procedures from the cohort. Patients were excluded if they did not have a diagnosis of secondary neovascular glaucoma, or if they did not attend regular follow-up eye examinations at our clinic. All the patients underwent a CCC procedure at the Department of Ophthalmology at the University Hospital in Hradec Králové in the period of 2016–2019.

The main entry criteria for inclusion in the cohort were the presence of secondary neovascular glaucoma in diabetes or upon a background of retinal artery or vein occlusion, and subsequent follow-up examination of the patient 1 and 6 months after surgery. The evaluated parameters were retrospective, specifically: best-corrected visual acuity (BCVA), IOP value, data on pain and change of antiglaucoma therapy. Informed consent was obtained from each patient.

BCVA was evaluated by a Snellen chart, and for a better statistical readout was converted according to the Freiburg classification [10].

Subjectively evaluated pain was within the range of 0–4 (0 – none, 1 – mild, 2 – medium, 3 – severe and 4 – unbearable pain).

Intraocular pressure was measured using a noncontact method, in the case of discrepancies by applanation.

The CCC procedure was performed using the instrument CRYO-S Classic (model: OFTAL, manufacturer Metrum CryoFlex). The procedure was performed by different operating surgeons in retrobulbar anaesthesia, at the temperature stated by the manufacturer, i.e., -72 °C. The time of freezing was 60 seconds. The location of the procedure was the same in 20 cases – 6 cryopoints in the lower half. Four procedures had 6 cryopoints in both temporal quadrants, two procedures had 6 cryopoints in the nasal half, one procedure had 7 cryopoints in the temporal and lower quadrant, one procedure had 4 cryopoints in the lower half, one procedure had 7 cryopoints in both lower quadrants, and in one procedure 8 cryopoints were applied between numbers 2 and 10.

The results were statistically evaluated by the following method: the normality of the data was tested with the aid of a Shapiro-Wilk test. Change of therapy, BCVA and IOP before the procedure and subsequently 1 and 6 months after the procedure were assessed with the aid of a two-sample paired Wilcoxon test and a Sign test. Only in one case, 1 month after surgery, did the data on IOP have a normal distribution, and a T test was used. All the tests were processed on a level of significance of  $p = 0.05$ .

## RESULTS

The average age of the patients at the time of performance of the procedure was 61 years (within the range of 22–85 years). The procedure was performed 20 times

on the right eye and 10 times on the left eye out of a total number of 30 procedures on 26 eyes of 24 patients.

The most frequent indication for performance of CCC in secondary glaucoma was vascular complications in diabetes in 21 procedures, and vascular complications of the retinal vein or artery in 9 cases.

In addition to CCC, a total of 23 patients also underwent laser treatment of the retina. One patient subsequently had laser treatment of the retina in both eyes. One patient had CCC in both eyes, but underwent laser treatment only in one eye.

The average value of the number of active substances of antiglaucoma drugs decreased from the value of 3.10 to 2.87 after 1 month ( $p = 0.318$ ), and after 6 months

was 2.6 ( $p < 0.05$ ). After 1 month, two patients remained without therapy, and after 6 months three patients were without therapy.

The average IOP value decreased from 34.67 mmHg to 18.43 mmHg after 1 month ( $p < 0.05$ ) and after 6 months to 17.90 mmHg ( $p < 0.05$ ) (Table 1, Graph 1).

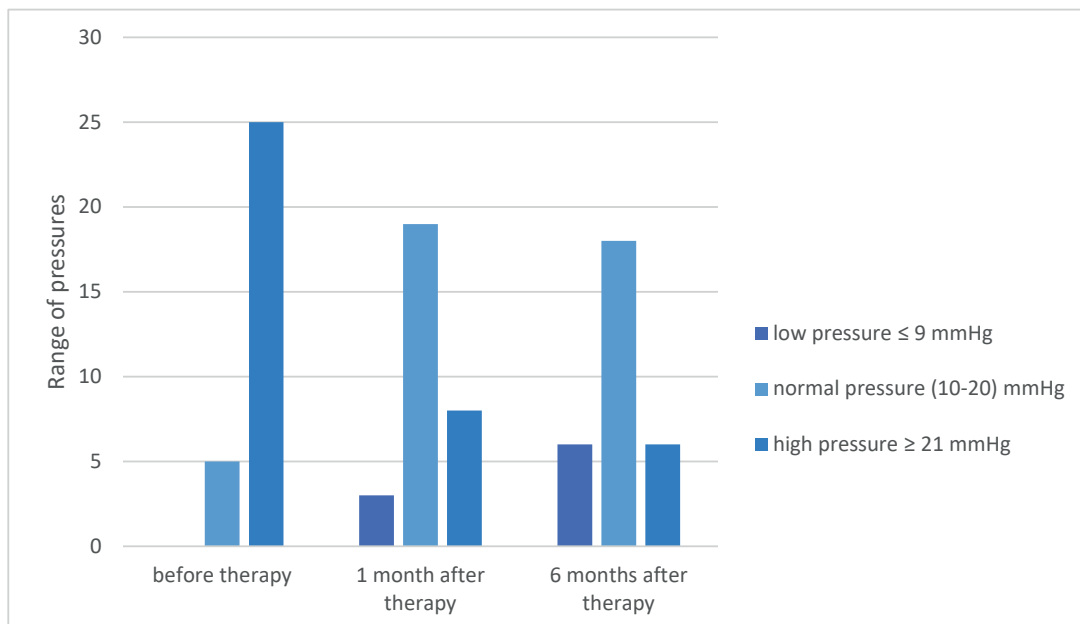
The average BCVA value increased from 0.135 to 0.138 after 1 month ( $p = 0.444$ ) and after 6 months decreased to 0.096 ( $p = 0.170$ ). The maximum value increased from 0.500 to 0.800 after 1 month, and was unchanged after 6 months. A patient who underwent a procedure for a blind, dolorous eyeball had unchanged vision throughout the course of the observation period (Table 1, Graph 2).

One month after the procedure, the average value of

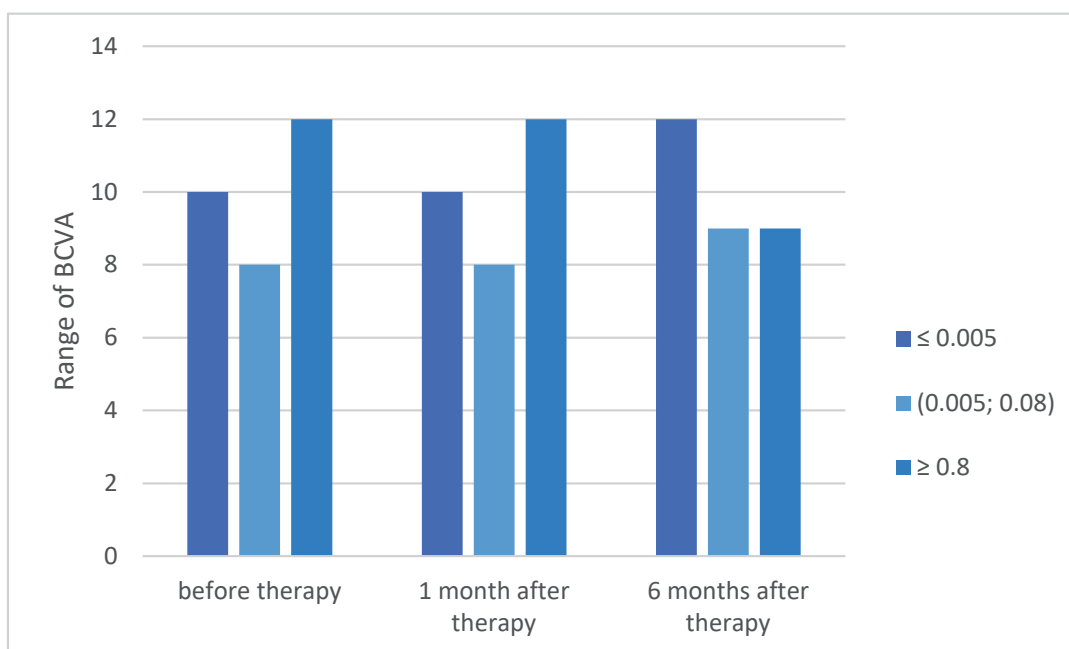
**Table 1.** Data on best-corrected visual acuity and intraocular pressure before surgery and during postoperative follow-ups, which we then statistically processed

Patient	BCVA before	IOP before	BCVA after 1 month	IOP after 1 month	BCVA after 6 month	IOP after 6 month
1.	0.030	30	0.167	27	0.160	18
2.	0.005	56	0.005	28	0.005	24
3.	0.500	20	0.400	14	0.005	19
4.	0.004	32	0.004	19	0.014	13
5.	0	18	0	16	0	13
6.	0.100	38	0.014	20	0.020	44
7.	0.005	58	0.030	9	0.050	10
8.	0.030	32	0.020	15	0.015	15
9.	0.500	32	0.800	26	0.167	20
10.	0.250	28	0.250	14	0.317	14
11.	0.167	32	0.313	22	0.500	25
12.	0.005	11	0.005	5	0.003	6
13.	0.014	34	0.005	18	0.005	6
14.	0.500	33	0.500	25	0.500	16
15.	0.250	30	0.167	18	0.317	20
16.	0.040	26	0.030	20	0.003	15
17.	0.060	59	0.400	20	0.050	12
18.	0.400	55	0.050	15	0.060	8
19.	0.160	30	0.120	17	0.120	3
20.	0.400	16	0.320	25	0.320	20
21.	0.003	28	0.005	9	0.003	33
22.	0.200	35	0.150	20	0.160	36
23.	0.014	48	0.020	11	0.014	7
24.	0.003	55	0.003	32	0.003	40
25.	0.050	23	0.040	20	0.030	10
26.	0.004	33	0.005	20	0.003	24
27.	0.003	40	0.003	10	0.003	18
28.	0.003	42	0.003	21	0.003	21
29.	0.020	50	0.020	22	0.020	19
30.	0.333	16	0.300	15	0.005	8

BCVA - best-corrected visual acuity  
IOP - intraocular pressure



**Graph 1.** Distribution of frequency of number of measured pressure values before therapy and during postoperative examinations



**Graph 2.** Distribution of frequency of number of measured best-corrected visual acuity before operation and during postoperative examinations

pain was identical to that before the procedure (0.23). The maximum pain score before the procedure was 2 in 2 patients, and 1 in 3 patients. The minimum pain score before the procedure was 0. After 1 month, 5 patients had a pain score of 1 and 1 patient had a score of 2. Six months after the procedure, none of the patients stated any pain.

## DISCUSSION

Secondary glaucomas are a relatively common cause of blindness. Timely diagnosis and quick commencement of treatment are essential in order to prevent irreversible

loss of sight as a consequence of secondary glaucoma [11]. In our cohort of patients, no statistically significant changes of visual acuity were achieved over the course of the observation period. The slight deterioration of BCVA after six months was statistically insignificant.

CCC represents a good method of treatment of advanced, inadequately controlled glaucomas with subjective symptoms (pain in eyes or head), when other methods have failed. With correct timing the procedure is capable of preventing the onset of serious complications. Despite the fact that cyclocryotherapy is not always effective, it is an outpatient surgical technique that is easy to apply, non-invasive, cost-effective, and can also

be repeated in the case of resistant chronic glaucoma [12,13,14,15]. For our sample we selected patients in whom compensation of IOP had been unsuccessful using the maximum possible local and general therapy with subjective symptoms of pain. Six months after the procedure, none of the patients stated eye pain.

In the case of failure of CCC itself, it is possible to achieve compensation of IOP by supplementing transscleral panretinal photocoagulation (TPRP) [16]. The method of TPRP in combination with CCC produces better results than CCC alone [17]. Laser treatment of the retina subsequent to CCC was performed 29 times in our cohort, on 25 eyes of 23 patients.

Herde et al. documented that cyclocryotherapy brought about a statistically significant reduction of IOP with primary or secondary glaucoma [18]. A similar, statistically significant result was produced also in our cohort of patients, in whom we achieved a reduction of IOP after 6 months to 17.90 mmHg ( $p < 0.05$ ).

We only included in our cohort patients with secondary neovascular glaucomas on a background of complications in diabetes or vascular complications – following retinal vein or artery occlusion. Fili et al. published a study on the effectiveness of a combination of CCC and intravitreal application of bevacizumab in the treatment of decompensated neovascular glaucoma with low visual acuity and painful eyeball [19]. In our study, the CCC procedure alone was sufficient, by which we succeeded in reducing IOP values after 6 months to 17.90 mmHg ( $p < 0.05$ ), and the number of active substances of antiglaucoma therapy after 6 months was 2.6 ( $p < 0.05$ ). Our results are confirmed by Heuring et al., who state that cyclocryosurgery is an effective method for reducing IOP in advanced, refractory glaucoma, when other methods have failed (including surgical). In their cohort of 76 eyes of 75 patients, preoperative IOP values of  $44.7 \pm 2.6$  mmHg were reduced to values of  $15.6 \pm 6.5$  mmHg after 12–36 months [20]. Kovacic et al. published 6 monthly results for patients who had undergone a CCC procedure. The authors demonstrated that IOP and eyeball pain were significantly lower than before the procedure. Their sample included 70 patients who were resistant to treatment and surgical interventions and had subsequently undergone a CCC procedure. Before the procedure, average IOP was 44.8 mmHg, afterwards a decreasing tendency of IOP could be observed to a final value of 19.9 mmHg 180 days after the procedure. The procedure has no effect on improving BCVA [21]. The ratio of risk to success

appears to be acceptable. This is also the conclusion of an article by Benson and Nelson, in which their results demonstrate that cyclocryotherapy provides good relief from pain while maintaining good regulation of pressure in various different types of glaucomas. Even though a manifestly high degree of complications exists, loss of sight and phthisis bulbi cannot be directly attributed to the procedure, because this concerns eyes with a poor prognosis [22]. We also reached the same conclusion upon processing the results of our cohort. None of the patients stated pain 6 months after the procedure, the number of active substances of antiglaucoma therapy was reduced to 2.6 ( $p < 0.05$ ), in which we succeeded in reducing the values of IOP in the majority of cases.

Recently cyclophotocoagulation has come to the forefront in the treatment of secondary glaucomas. Tzamalīs et al. compared the results of reduction of IOP and effectiveness of treatment in patients. It was demonstrated that diode laser cyclophotocoagulation and cyclocryotherapy are safe and effective methods for reducing IOP in patients with refractory glaucoma [23].

## CONCLUSION

In our retrospective study, we evaluated the effect of cyclocryocoagulation in secondary neovascular glaucomas in procedures performed at our department over the period of 2016–2019, with a focus on pain, IOP, BCVA and changes of the number of active substances of antiglaucoma drugs. Our results correspond with the results of foreign authors, although these results are limited by their retrospective observation and the small cohort of patients. Another factor which complicates the gathering of data was the fact that the intervals between follow-up examinations of patients were not always regular, and sometimes the patients did not report to our clinic for a follow-up examination after the performance of the procedure. As a result of this, we subsequently excluded these patients from the cohort, and out of a total number of 116 procedures we were left with only 30 procedures that we were subsequently able to process. Our results demonstrate that cyclocryocoagulation remains an effective technique for reducing IOP in secondary neovascular glaucoma that is unresponsive to conservative therapy. This technique has the potential to remove pain but is not capable of improving visual functions. We thereby confirmed the results of previously published studies.

## LITERATURE

1. Edmunds B, Loh AR, Fenerty C, Papadopoulos M. Secondary Glaucoma: Glaucoma Associated with Acquired Conditions. American Academy of Ophthalmology [online]. 12.11.2015 [cit. 16.7.2020]. Available from: <https://www.aao.org/disease-review/secondary-glaucoma-glaucoma-associated-with-acquir>
2. Konareva-Kostianeva M. Neovascular glaucoma. Folia Med (Plovdiv). 2005;47:5-11.

3. Barac IR, Pop MD, Gheorghe AI, Taban C. Neovascular Secondary Glaucoma, Etiology and Pathogenesis. *Rom J Ophthalmol*. 2015;59:24-28.
4. Huang G, Lin SC. When should we give up filtration surgery: indications, techniques and results of cyclodestruction. *Dev Ophthalmol*. 2012;50:173-183.
5. Bitrian E, Freedman SF. Glaucoma: Cyclodestruction. *American Academy of Ophthalmology* [online]. 08.11.2015 [cit. 15-7-2020]. Available from: <https://www.aao.org/disease-review/glaucoma-cyclodestruction>
6. Bietti G. Surgical Intervention on the Ciliary Body; New Trends for the Relief of Glaucoma. *J Am Med Assoc*. 1950;142:889-897.
7. Leffler CT. *The History of Glaucoma*. Wayenborgh Publishing, 2020. s. 538. ISBN: 978-90-6299-467-0.
8. Roeth A. Cryosurgery for the treatment of advanced chronic simple glaucoma. *Trans Am Ophthalmol Soc*. 1968;66:45-61.
9. Dastiridou AI, Katsanos A, Denis P, et al. Cyclodestructive Procedures in Glaucoma: A Review of Current and Emerging Options. *Adv Ther*. 2018;35:2103-2127.
10. Schulze-Bolsen K, Feltgen N, Burau H, Hansen L, Bach M. Visual Acutities "Hand Motion" and "Counting Fingers" Can Be Quantified with the Freiburg Visual Acuity Test. *Investigative Ophthalmology & Visual Science*. 2006;47:1236-1240.
11. Dubey S, Jain K, Mukherjee S, et al. Current Profile of Secondary Glaucoma in a Northern India Tertiary Eye Care Hospital. *Ophthalmic Epidemiol*. 2019;26:200-207.
12. Kim BS, Kim YJ, Seo SW, Yoo JM, Kim SJ. Long-term Results from Cyclocryotherapy Applied to the 3O'clock and 9O'clock Positions in Blind Refractory Glaucoma Patients. *Korean J Ophthalmol*. 2015;29:47-52.
13. Klemm M, Harbeck W, Kohlhass M. Cyclocryocoagulation in treatment of special types of glaucoma. *Ophthalmologe*. 1995;92:556-559.
14. Meyer JH, Soriano JM, Janknecht P, Funk J. Results of cyclocryocoagulation. *Klin Monbl Augenheilkd*. 1994;205:14-18.
15. Nicaeus T, Derse M, Schlote T, Erb C, Rohrbach JM, Thiel HJ. Cyclocryocoagulation in Treatment of Therapy Refractory Glaucoma: A Retrospective Analysis of 185 Cryocoagulation Procedures. *Klin Monbl Augenheilkd*. 1999;214:224-230.
16. Řehák J, Vymazal M. Naše pětileté zkušenosti v léčbě neovaskulárního glaukomu kryokoagulací. I. Vývoj nitroočního tlaku. [5 years' experience in the treatment of neovascular glaucoma using cryocoagulation. I. Development of intraocular pressure]. *Cesk Oftalmol*. 1992;48:281-285. Czech.
17. Rehak J, Vymazal M. Neovascular Glaucoma with Closed Anterior Chamber Angle Treated With Cryotherapy. *Klin Monbl Augenheilkd* 1994;204:20-23.
18. Herde J. Relevance of Long-Term Follow-Up of Cyclocryocoagulation. *Ophthalmologe*. 1999;96:772-776.
19. Fili S, Kohlhaas M, Schilling H, Ligges U, Zelo I. Surgical treatment of neovascular glaucoma. *Klin Monbl Augenheilkd*. 2014;231:1230-1238.
20. Heuring AH, Hütz WW, Hoffmann PC, Eckhardt HB. Cyclocryotherapy in neovascular glaucoma and non-neovascular glaucoma. *Klin Monbl Augenheilkd*. 1998;213:213-219.
21. Kovacic Z, Ivanisević M, Rogosić V, Plavec A, Karelović D. Cyclocryocoagulation in treatment of neovascular glaucoma. *Lijec Vjesn*. 2004;126:240-242.
22. Benson MT, Nelson ME. Cyclocryotherapy: A Review of Cases Over a 10-year Period. *Br J Ophthalmol*. 1990;74:103-105.
23. Tzamalīs A, Pham DT, Wirbelauer C. Diode Laser Cyclophotocoagulation Versus Cyclocryotherapy in the Treatment of Refractory Glaucoma. *Eur J Ophthalmol*. 2011;21:589-596.