

UVEAL MELANOMA IN A 15-YEAR-OLD GIRL. CASE REPORT

Žajdlíková B.¹, Autrata R.¹, Krejčířová I.¹, Lazarčíková V.¹,
Heissigerová J.², Diblík P.², Glezgová J.², Vysloužilová D.³, Ježová
M.⁴, Šach J.⁵, Autrata D.³

¹Department of Paediatric Ophthalmology, Faculty of Medicine,
Masaryk University and University Hospital, Brno

²Department of Ophthalmology, 1st Faculty of Medicine, Charles
University and Military University Hospital, Prague

³Department of Ophthalmology, Faculty of Medicine, Masaryk
University and University Hospital, Brno

⁴Department of Pathology, University Hospital, Brno

⁵Department of Pathology, 3rd Faculty of Medicine and Královské
Vinohrady University Hospital, Prague

The authors of the study declare that no conflict of interests exists in the compilation, theme and subsequent publication of this professional communication, and that it is not supported by any pharmaceuticals company. The study has not been submitted to any other journal or printed elsewhere, with the exception of congress abstracts and recommended procedures.

Received: 16 October 2020

Accepted: 25 January 2021

Available on-line: 1 May 2021



MUDr. Barbora Žajdlíková
Dětská oční klinika LF MU a FN
Brno
Černopolní 9
62500 Brno
E-mail: zajdlikova.barbora@
fnbrno.cz

SUMMARY

Uveal melanoma is the most common intraocular tumour in adults, it is a form of cancer that affects mostly older adults, as the average age at detection of this tumour is 60 years, but it can occur in any age group with no significant gender difference. However, uveal melanoma is very rare in children compared to the adult population, accounting for 1 % of all cases. In pediatric patients, malignant uveal melanoma is more frequently manifested during puberty, leading to speculation of an association between uveal melanoma and growth hormone levels. Prognostic factors for uveal melanoma include tumour histology, chromosomal abnormalities, tumour size, extrascleral spread and tumour location. Risk factors for uveal melanoma include melanocytosis, neurofibromatosis type 1 and dysplastic naevus syndrome. Some studies point to a significantly lower risk of developing metastases in younger patients, but the prognosis of uveal melanoma in children is not yet fully known. Clinical signs and treatment options for malignant uveal melanoma in children are still under discussion. Differential diagnosis of uveal lesions in children can sometimes be very difficult, as evidenced by following case report in which authors describe a case of choroidal melanoma in a 15-year-old girl.

Key words: choroidal melanoma, children, enucleation, metastasis

Čes. a slov. Oftal., 77, 2021, No. 2, p. 94–100

INTRODUCTION

Uveal melanoma may appear in any age group but occurs far more frequently in adults than in children [1]. Malignant uveal melanoma is the most common primary intraocular melanoma worldwide. It is usually manifested in the 5th-6th decade of life, but a number of rare cases of this pathology have been recorded in children. Despite the fact that the clinical appearance and prognosis of these lesions is considered similar as in adults, certain studies demonstrate a more favourable prognosis in children [2]. Shields et al. examined clinical manifestations and determined that uveal melanomas in children are more frequently localised on the iris, are smaller, less pigmented, and manifest extraocular growth less frequently [3]. The options for treatment of uveal melanoma ensue from

the size of the tumour, localisation, age of the patient and a number of other factors. In the case report we present the case of a 15-year-old female patient who was diagnosed with choroidal melanoma of mixed type, in whom enucleation of the affected eyeball was indicated due to the size of the tumour and unfavourable prognosis.

CASE REPORT

The subject of our case report is a 15-year-old girl, who stated a malfunction of vision in the right eye progressing over the course of approximately one month, which was objectively confirmed at an examination with a paediatrician. The patient was immediately sent to the Department of Paediatric Ophthalmology at the University Hospital in Brno for a specialist ophthalmological examination due to

intrabulbar expansion in the right eye.

The patient was being treated for atopic eczema and an allergy. Her grandmother had died from a pancreatic tumour, otherwise her family medical history was not significant. Upon admittance to hospital, the patient upon first appearance clearly manifested right sided leukocoria. The patient stated only light perception in her right eye, vision in the left eye was not affected. Intraocular pressure was bilaterally within a physiological range (right eye 17, left eye 14 mmHg). Upon examination of the anterior segment of the right eye, we determined a 1 mm wider pupil, with retarded reaction to light exposure, otherwise the anterior segment was bilaterally intact.

A basic examination was conducted – examination of ocular fundus in mydriasis, photo of ocular fundus and

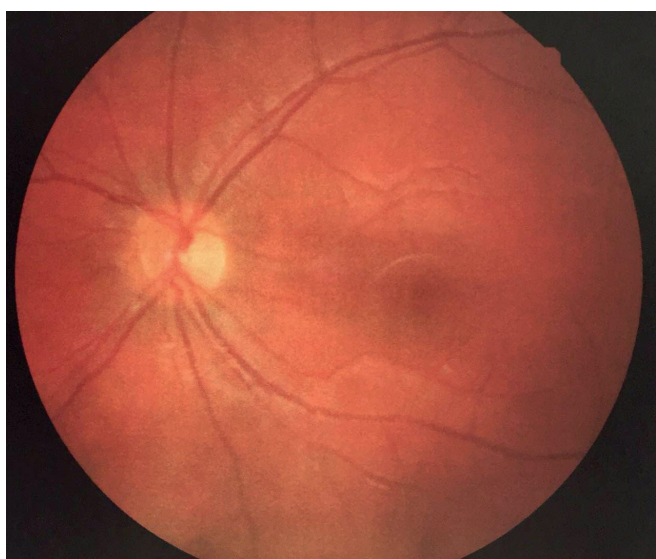


Fig. 1. Fundus photograph of left eye – normal fundus

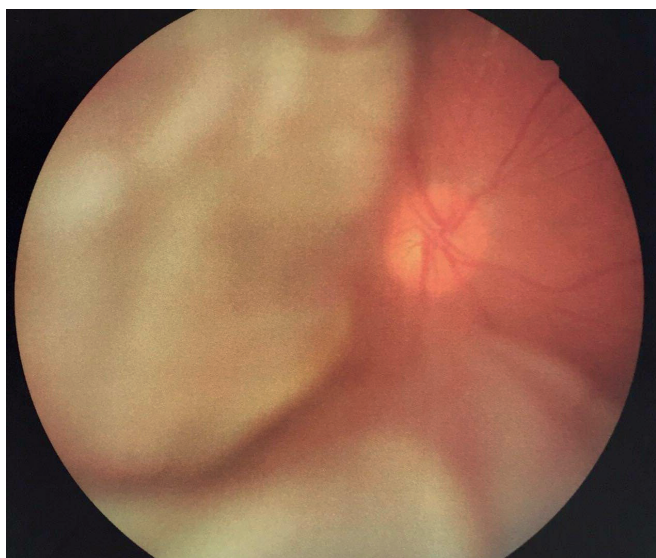


Fig. 2. Fundus photograph of right eye – pale optic nerve papilla with clearly delineated margins, temporal margin slightly raised, tumorous mass between 7-11 o'clock, secondary retinal detachment at bottom, retina lying in periphery of upper nasal quadrant

ultrasound of eyeballs. On the photograph of the left eye there is a physiological finding on the ocular fundus (Fig. 1), in the right eye the papilla is paler, clearly delineated, slightly temporally projecting, between 7 o'clock - 11 o'clock tumorous mass, secondary retinal detachment at bottom, retina lying in the periphery of the upper nasal quadrant (Fig. 2). An ultrasound image of the right eyeball confirmed almost total retinal detachment (except for a small area at the top), in the temporal periphery there was a solid lesion with a smooth surface, with low internal reflectivity (Fig. 3). Magnetic resonance of the head was indicated immediately, which demonstrated pathological matter in the vitreous body of the right eyeball, with secondary retinal detachment, without signs of extrabulbar expansion (Fig. 4). After all the examinations, in differential diagnostics we considered the possibility of exophytic retinoblastoma, choroidal melanoma or other haemorrhagic tumour. Due to the ambiguous finding and progression of the condition, the patient was sent to another centre for a control ultrasound examination, which confirmed an extensive projecting lesion in both temporal quadrants, with low homogeneous echogenicity, without calcifications (Fig. 5), and for fluorescence angiography, which did not confirm vascularity or other vascular abnormalities.

Newly considered was a diagnosis of chorioretinal granuloma of suspected toxocariasis etiology. We therefore took complete blood samples from the patient, in which worthy of mention are increased levels of IgE antibodies, which is nevertheless normal in sufferers of allergies. Complete samples were also taken for anthro-pozoonosis, which were negative, and further examinations for lung X-ray and ultrasound of the abdomen were indicated, also with a physiological result.

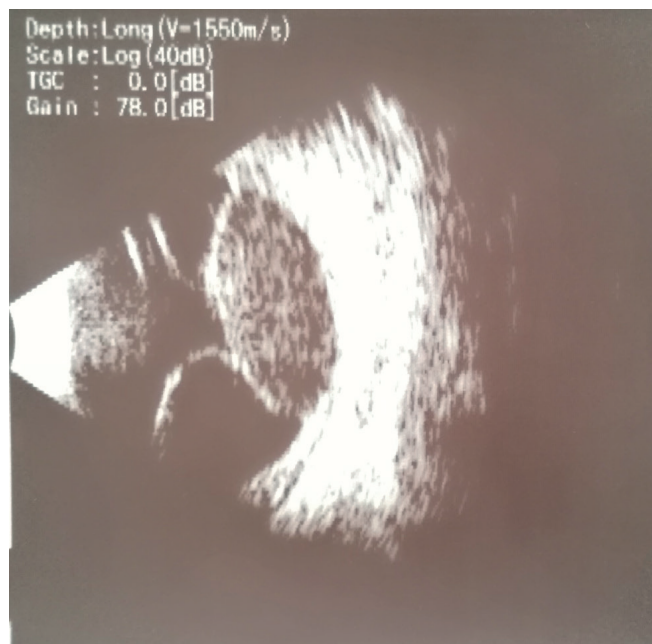

Figure 3. Ultrasound of right eyeball – nearly total retinal detachment (apart from small area above), solid lesion with smooth surface with low internal reflectivity in temporal periphery

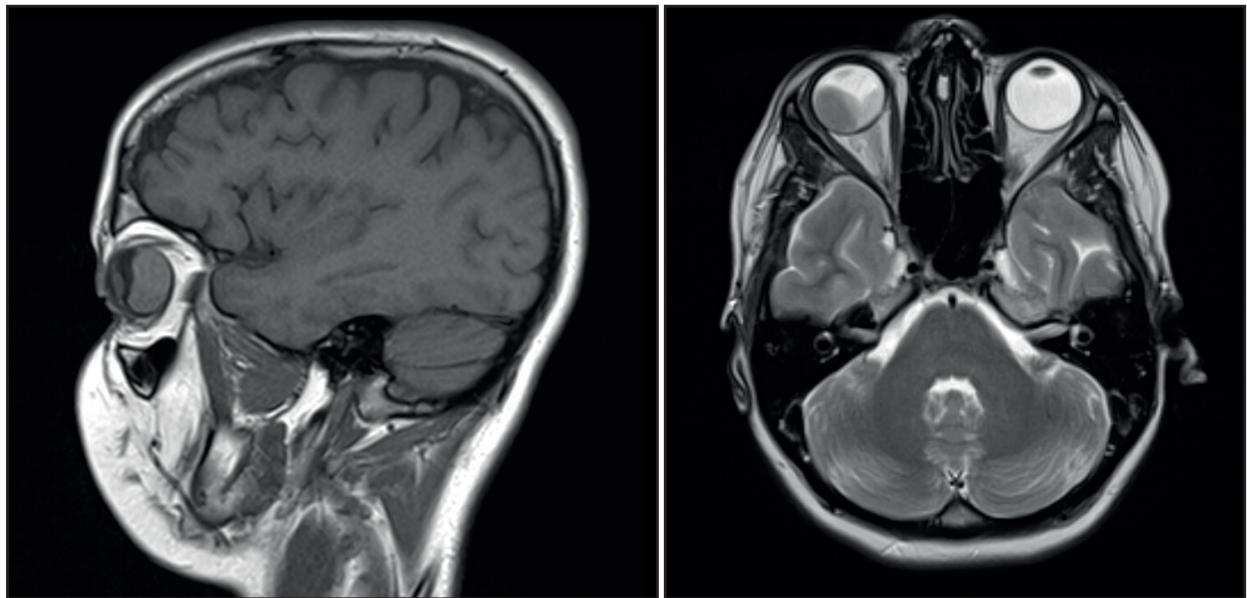


Figure 4. Magnetic resonance sagittal (A) and transversal (B) image – in right part of right eyeball solid lentil-shaped soft-tissue lesion with heavy post-contrast saturation, left and caudal portion of eyeball filled with subretinal haematoma, no calcifications

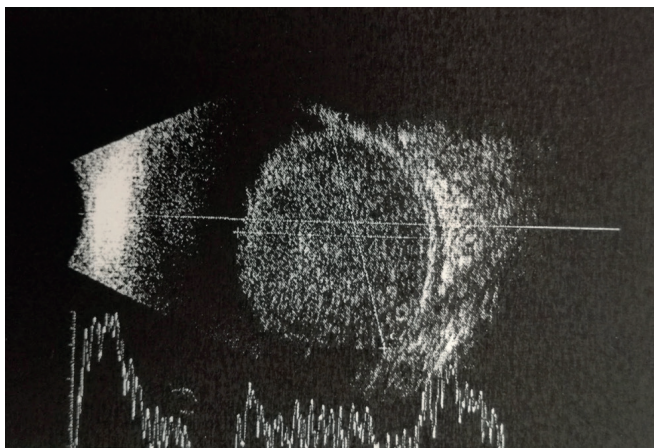


Figure 5. Control ultrasound – large projecting lesion in both temporal quadrants with low homogeneous echogenicity, no calcifications

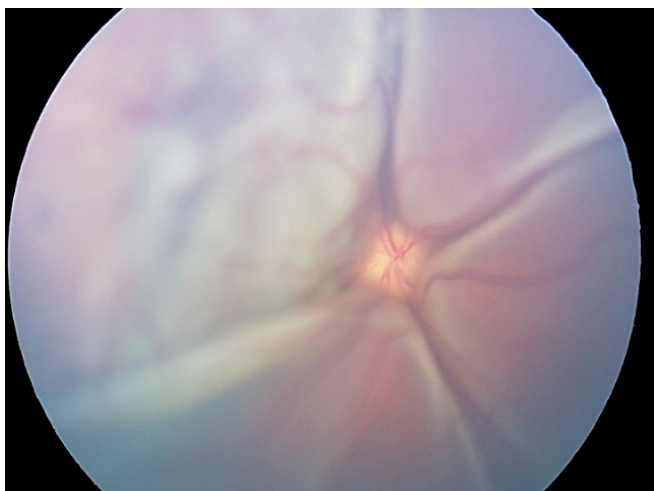


Figure 6. Retinal camera image – exudative retinal detachment from optic nerve papilla in its entirety

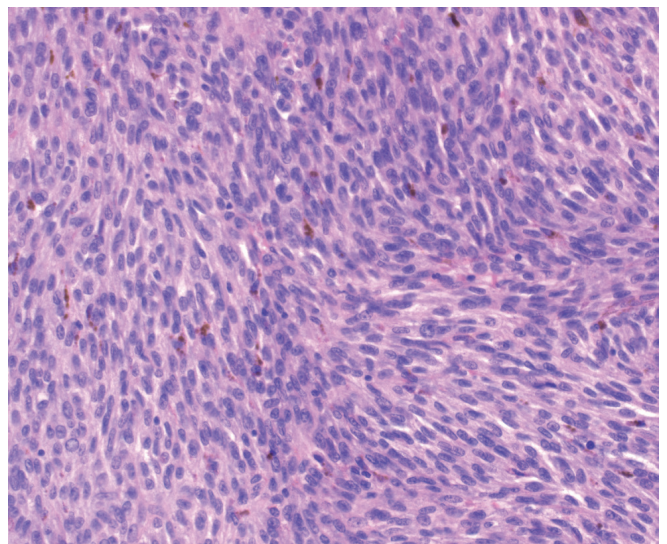


Figure 7. Microscopic image after haematoxylin and eosin staining – spindle tumour cells with brown melanin pigment granules

However, a progression of the finding gradually took place, which is visible on images from a retinal camera – exudative retinal detachment from the optic nerve papilla in its entire scope (Fig. 6). After an inter-disciplinary consultation, a decision was taken on a therapeutic intervention, namely Solumedrol boluses intravenously. We administered the patient 5 boluses of Solumedrol in a dose of 15 mg/kg, after which transition to Prednisone 50 mg per os was indicated, in a reducing dose over a period of 12 days, as well as the antihelminthic drug Zentel 400 mg per os, which was administered to the patient over a period of 8 days.

Due to the further progression of the finding and zero response to the therapy, we decided to send the patient to the Department of Ophthalmology at the 1st Fa-

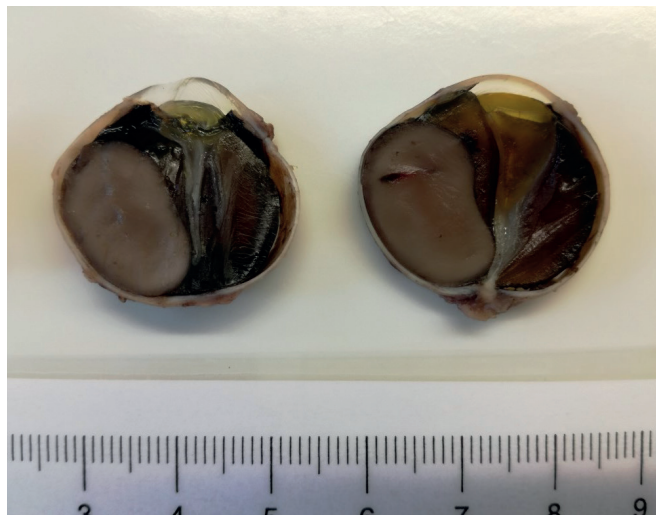


Figure 8. Macroscopic image of enucleated eyeball – tumorous mass size 17-11 mm with shallow scleral invasion, no angioinvasion, no invasion of optic nerve, no necrosis

culty of Medicine of Charles University and the General University Hospital in Prague, where she underwent a thin-needle puncture biopsy of the intraocular tumour. Following haematoxylin and eosin staining, spindle shaped tumour cells with brown melanin pigment granules were visible in the aspirate (Fig. 7). The result of the biopsy was mixed type uveal melanoma. Enucleation of the affected eyeball was immediately indicated, with an intraorbital silicone implant. The macroscopic image of the enucleated eyeball detected a tumorous mass of the size of 17 x 11 mm, with shallow invasion into the sclera, without angioinvasion, without invasion into the optic nerve, and without necroses (Fig. 8).

The patient underwent a complete examination by oncologists, initial staging of the pathology took place, a control magnetic resonance examination was conducted – without evidence of residue or recurrence of the tumour, and an examination by positron emission tomography (PET/CT) was conducted, also with a physio-

Table 1. Clinical data from published studies on choroidal melanoma in childhood in the last 10 years

Authors	Fry et al. [9]	Al Jamal et al. [10]	Yousef et al. [14]	Shields et al. [6]	Singh et al. [11]
Publication source/ year	JAMA 2019	Ophthalmology 2016	Cell Ther 2015	Saudi J. Ophthalmol 2013	Arch Ophthalmol 2000
Number of patients	18	114/185	13	122	63
% women	55	57/63	46	57	60
Age range (years)	4.4-20.8	2.7-17.9/18.0-24.9	0 (0-19 months)	3.0-20.0	3.0-20.0
Average age at time of diagnosis (years)	16.6	15.1/21.9	0 (7 months)	15	16
% choroidal melanoma	100	N/A	46	67	54
Average tumour diameter/thickness (mm)	12.7/7.2	12.0/6.0	N/A	9.8/5.0	N/A
Average follow-up time (months)	90	79.2/61.2	25	64	51
% patients with metastasis	44.4	8.0/17.0	15	N/A	N/A
% death from metastasis	44.4	7.0/15.0	8	N/A	6.3
Post-treatment mean survival (months)	142.8	N/A	N/A	N/A	N/A
Comment	Patients with choroidal melanoma - 78 % of patients were already more than 15 years after diagnosis. Median survival from metastasis diagnosis was 2.3 months.	Patients with ciliary body and choroidal melanoma. Survival rate in children versus young adults was 97 % versus 90 % at 5 years, and 92 % versus 80 % at 10 years.	N/A	Analysis Kaliki 2013 - 25 % iris melanoma, incidence of metastases at 10 years 8.8 %, at 20 years 36 %, rather smaller tumours, prepubescent age.	Short-term survival rate (5 years) more favourable than general adult population, long-term survival rate (15 years) comparable.

Abbreviation: N/A not applicable

logical result, with no signs of activity in the area of malignancy. As a result, adjuvant oncological therapy was not indicated, and a strategy of close wait and watch was chosen. The patient is now in a good condition, the cosmetic effect of the mobile prosthesis is satisfactory, and the patient undergoes regular and detailed outpatient monitoring.

DISCUSSION

Choroidal melanoma in children is very rare [4]. In the Czech Republic and Slovakia, the problem of uveal melanoma, especially in adult patients, is the focus of professor Furdová et al. [5,6,7,8]. The majority of practical ophthalmologists never encounter a case of paediatric uveal melanoma throughout the entire course of their career. There are enormous differences in the incidence of uveal melanoma in children and adults [1,4]. The incidence of uveal melanoma per million of the population in children aged 0-4 years is 0, 10-14 years 0.2% and 15-20 years 0.4%. It then increases further with age: 14.9 per million of the population between the ages of 60-69 years and 24.5 per million between 70-79 years [4]. Another significant difference is in the fact that in younger patients melanoma of the iris occurs more frequently in comparison with the older population, which is affected more often by choroidal melanoma [3,9,10]. Choroidal melanoma in young patients is therefore even rarer [4]. A number of studies have demonstrated that choroidal melanoma appears only in 1% of cases up to the age of 21 years [3,4,11,12,13].

It appears that choroidal melanoma in paediatric patients occurs especially during or after puberty (at the age of 13 to 20 years) [11,12,13]. This observation has led a number of authors to speculate that in paediatric cases there is an association between choroidal melanoma and increased levels of growth hormone. Al Jamal et al. [12,14] analysed the prevalence of uveal melanoma in children (aged 3-17 years) in comparison with young adults (aged 18-24 years), and document that the frequency of diagnosed cases fundamentally increases between the ages of 11 and 17 years from 0.8% annually to 8.8% annually [14]. In this study, 90% of choroidal melanomas were diagnosed during adolescence [14]. This supports a potential correlation between pubescent changes and the incidence of choroidal melanoma in paediatric patients. In our patient also, choroidal melanoma was manifested within this age range.

Studies evaluating cases of choroidal melanomas in young individuals have recorded a slight gender difference, with a small predominance of women (55%) [4]. However, no study in the age category of up to 21 years states a statistical correlation relating to sex [11,12,14,15]. The sum of clinical data from several studies focusing on uveal melanoma in childhood age over the last 10 years is presented in table 1 [4].

In differential diagnostics, the authors state medulloepithelioma, haemangioma, haematoma and inflammatory affliction [9]. Toxocariasis haemorrhagic granuloma ranks among

the main differential diagnostic units considered in our case report. In paediatric patients it is important also to exclude the possibility of retinoblastoma, which we also considered in our patient, since at our centre we have previously recorded rare cases of retinoblastoma at this unusual age.

The selected treatment for uveal melanoma depends on the size of the tumour, its location, patient age and other factors. Brachytherapy is the most frequently used therapy for localised uveal melanomas [1]. With regard to the size of the tumour in our patient, the extensive retinal detachment and zero prognosis *quad visum*, the indication for enucleation was unequivocal.

The histopathological or molecular pathological stages of uveal melanoma in children did not manifest any difference from their adult counterparts [14]. After the taking of a sample by thin-needle puncture biopsy, our patient was diagnosed with mixed type uveal melanoma, which generally has a better prognosis. The prognosis of choroidal melanoma in paediatric patients is not completely known [4]. Several authors have documented a more favourable prognosis of uveal melanoma in paediatric patients [9,11,12,16]. However, other recent studies have rather refused these previous opinions [4,13,14]. Despite the fact that a certain awareness exists within the field of ocular oncology that younger patients with a diagnosis of uveal melanoma have a better prognosis for survival, it is necessary to take into consideration the following important information, which may distort this general view: 1) the great majority of these tumours are limited to the iris (and many are without affliction of the chamber angle), 2) young patients (on the assumption that they are otherwise healthy) have less risk factors of mortality in comparison with older individuals, and probably are also better able to tolerate more aggressive therapy [4].

A recent study of the population of young patients recorded a similar, if not higher death rate in connection with choroidal melanoma in comparison with the regular older population [13]. Fry et al. [13], on the basis of a Kaplan-Meier analysis, for a group of young patients (aged 0-20 years) document estimates of the incidence of metastases in connection with a tumour after 5, 10 and 15 years at 36.6%, 60.8% and 60.8% respectively. These numbers therefore far exceed the metastatic prognoses of choroidal melanomas in paediatric and adult patients stated in previous studies by other authors [9,11,12]. Shields et al. [9] presented prognostically far more favourable numbers: a Kaplan-Meier estimator evaluated the incidence of metastases of choroidal melanoma at 3, 5 and 10 years at 2%, 11% and 18% respectively in a group of children aged up to 20 years, at 9%, 14% and 21% respectively up to 60 years and at 9%, 34% and 33% in individuals aged over 60 years. The authors explain the discrepancy between the results concerning the survival rate especially by means of the longer observation period in comparison with older data available in the current literature [9,11]. The results of recent studies confirm that the incidence of metastases in paediatric patients with choroidal melanoma appears later than in the general (older) population [4,13]. It is therefore important to

be aware that in certain young patients it has been demonstrated that metastases of choroidal melanoma appear even as long as 10 to 20 years after treatment [11,17]. This could explain why studies which have an average observation period of 5 years show a better prognosis in younger patients [3,9,11,18,19]. A similar opinion is stated by Singh et al. [15], who point to the fact that while the 5-year survival of young patients with uveal melanoma is better than in the regular population of patients, their long-term survival (15 years) is actually similar as in adults [15,20].

Virtually no data exists relating to genome and cytogenic aberrations of choroidal melanoma in young patients. Preliminary data published recently showed that monosomy on the 8th arm of the 3rd chromosome represents a higher risk of metastasis of the tumour, and disomy of the 3rd chromosome corresponds to a lower risk of occurrence of metastases [14,21], similarly as in the general population of patients with uveal melanoma [22,23,24,25]. The authors of a recent study which examined chromosomal mutations in young patients aged up to 32 years with choroidal melanoma state that 64% of choroidal melanomas recorded disomy 3 ($n = 16$), which would correlate with a good survival rate [26]. These results could explain why younger patients have a tendency to have a better prognosis than the general population. With regard to the limited available information, it shall be necessary to conduct further studies in order to examine and determine the metastatic risk in young patients with diagnosed uveal melanoma, and these studies should incorporate a mutation analysis of these tumours [27,28,29]. Further valuable information would be provided by multicentric prognostic studies with genome testing, and these studies would also produce further observations to contribute to the present debate, in which there is a lack of consensus concerning the prognosis of choroidal melanoma within the current literature. The creation of a complex multicentric database for gathering data on uveal melanoma in young patients would provide a more thorough understanding of the influence of age on the result of treatment and the rate of survival in patients with uveal melanoma, in whom the pathology was diagnosed in childhood age. The result of a mutation analysis of our patient was the positive mutation

of GNAQ, which is typical of uveal melanoma and occurs in as many as 50% of cases, as well as negative mutations of KRAS, NRAS, BRAF, TP53, CDKN2A, GNA11.

A known risk factor of uveal melanoma is ocular melanocytosis [30]. If choroidal melanoma occurs in these patients, in this group there is a significantly increased risk of the incidence of metastases. Studies examining the overall proportion of uveal melanoma in eyes with ocular melanocytosis in the ordinary population and among younger patients demonstrated similar results (approximately 3%) [14]. Uveal melanomas in young patients may be linked not only to melanocytosis, but also to neurofibromatosis type 1 and dysplastic nevus syndrome [31]. None of these predisposing factors appeared in our patient, and all of these diagnostic units were eliminated by careful examination. In the literature a correlation has been demonstrated with the incidence of melanoma and the mutation of gene BRCA-1 associated protein 1 (BAP1) [1]. This testing has not yet been performed on our patient.

The degree of death rate in connection with a diagnosis of uveal melanoma is generally linked with a large basal diameter of the tumour and epithelioid cellular type [20]. With regard to the large size of the choroidal melanoma in our patient, which increases the risk of metastases, long-term routine observation of its occurrence is appropriate. Even after enucleation of the eyeball, the occurrence of metastases is a lifelong risk, and patients must be monitored regularly [32].

CONCLUSION

In differential diagnostics of intrabulbar expansions, especially of those that are unresponsive to treatment, it is necessary to consider also rare and often far more serious diagnoses. Using the example of this case report, we wished to point to the fact that even despite the rare incidence of uveal malignancies in children, this diagnosis should be considered also upon atypical manifestations. Examination by ultrasound and magnetic resonance imaging is the method of choice in these cases for determining the nature and extent of uveal lesions, though the results are not always unambiguous.

LITERATURE

1. Sivalingam MD, Hasanreisoglu M, Shields CL. Choroidal Melanoma in Children: Be Aware of Risks. *J Pediatr Ophthalmol Strabismus*. 2014;51 Online:e85-e88.
2. Jensen OA. Malignant melanoms of the human uvea: 25-year follow-up of cases in Denmark, 1943-1952. *Acta Ophthalmol*. 1982;60(2):161-182.
3. Shields CL, Kaliki S, Furuta M, Mashayekhi A, Shields JA. Clinical spectrum and prognosis of uveal melanoma based on age at presentation in 8,033 cases. *Retina*. 2012;32(7):1363-1372.
4. Fry MV, Augsburger JJ, Hall J, Corrêa ZM. Posterior uveal melanoma in adolescents and children: current perspectives. *Clin Ophthalmol*. 2018;12:2205-2212.
5. Furdová A, Juhas J, Šramka M, Králík G. Ciliary body melanoma treatment by stereotactic radiosurgery. *Cesk Slov Oftalmol*. 2018;73(5-6):204-210. Available from: <https://www.cs-ophtalmology.cz/cs/journal/articles/31>
6. Furdova A, Babal P, Kobzova D, et al. Uveal melanoma survival rates after single dose stereotactic radiosurgery. *Neoplasma*. 2018;65(6):965-971.
7. Furdova A, Sramka M, Chorvath M, Kralik G, Furda R, Gregus M. Clinical experience of stereotactic radiosurgery at a linear accelerator for intraocular melanoma. *Melanoma Res*. 2017;27(5):463-468.
8. Furdová A, et al. Melanómy oka a očných adnexov. 1st ed. Bratislava: Veda; 2020. 320.
9. Shields CL, Kaliki S, Arepalli S, et al. Uveal melanoma in children and teenagers. *Saudi J Ophthalmol*. 2013;27(3):197-201.
10. Griščíková L, Autrata R, Pramuková K, Mlčák P, Marešová K. Melanom duhovky u dětského pacienta [Iris melanoma in a child]. *Cesk Slov Oftalmol*. 2016;72(5):191-194. Czech.
11. Kaliki S, Shields CL, Mashayekhi A, Ganesh A, Furuta M, Shields JA. Influence of age on prognosis of young patients with uveal melanoma: a matched retrospective cohort study. *Eur J Ophthalmol*.

- 2013;23(2):208-216.
12. Al-Jamal RT, Kivelä T. Uveal melanoma among Finnish children and young adults. *J Aapos*. 2014;18(1):61-66.
13. Fry MV, Augsburger JJ, Correa ZM. Clinical features, metastasis and survival in patients younger than 21 years with posterior uveal melanoma. *JAMA Ophthalmol*. 2019;137(1):75-81.
14. Al-Jamal RT, Cassoux N, Desjardins L, et al. The Pediatric Choroidal and Ciliary Body Melanoma Study: A Survey by the European Ophthalmic Oncology Group. *Ophthalmology*. 2016;123(4):898-907.
15. Singh AD, Shields CL, Shields JA, Sato T. Uveal melanoma in young patients. *Arch Ophthalmol*. 2000;118(7):918-923.
16. Kaliki S, Shields C, Shields J. Uveal melanoma: Estimating prognosis. *Indian J Ophthalmol*. 2015;63(2):93-102.
17. Kolandjian NA, Wei C, Patel SP, et al. Delayed Systemic Recurrence of Uveal Melanoma. *Am J Clin Oncol*. 2013;36(5):443-449.
18. Yousef YA, Alkilany M. Characterization, treatment, and outcome of uveal melanoma in the first two years of life. *Hematol Oncol Stem Cell Ther*. 2015;8(1):1-5.
19. Andreoli MT, Mieler WF, Leiderman YI, William M. Epidemiological trends in uveal melanoma. *Br J Ophthalmol*. 2015;99(11):1550-1553.
20. Singh AD, Turell ME, Topham AK. Uveal melanoma: trends in incidence, treatment and survival. *Ophthalmology*. 2011;118(9):1881-1885.
21. Soltysova A, Sedlackova T, Dvorska D, et al. Monosomy 3 Influences Epithelial-Mesenchymal Transition Gene Expression in Uveal Melanoma Patients; Consequences for Liquid Biopsy. *Int J Mol Sci*. 2020 Dec 17;21(24):9651.
22. Damato B, Dopierala JA, Coupland SE. Genotypic Profiling of 452 Choroidal Melanomas with Multiplex Ligation-Dependent Probe Amplification. *Clin Cancer Res*. 2010;16(24):6083-6092.
23. Cassoux N, Rodrigues MJ, Plancher C, et al. Genome-wide profiling is a clinically relevant and affordable prognostic test in posterior uveal melanoma. *Br J Ophthalmol*. 2014;98(6):769-774.
24. Van Beek JG, Koopmans AE, Vaarwater J, et al. The prognostic value of extraocular extension in relation to monosomy 3 and gain of chromosome 8q in uveal melanoma. *Invest Ophthalmol Vis Sci*. 2014;55(3):1284-1291.
25. Versluis M, de Lange MJ, van Pelt SI, et al. Digital PCR Validates 8q Dosage as Prognostic Tool in Uveal Melanoma. *PLoS One*. 2015;10(3):e0116371.
26. Heyer LJ, Metz C, Flühs D, Heyer CM, Bornfeld N. Uveal and iridociliary melanomas in young patients: A retrospective analysis of 57 cases. *Ophthalmologie*. 2016;113(12):1046-1050.
27. Corrêa ZM, Augsburger JJ. Independent Prognostic Significance of Gene Expression Profile Class and Largest Basal Diameter of Posterior Uveal Melanomas. *Am J Ophthalmol*. 2016;162:20-27.
28. Onken MD, Worley LA, Char DH, et al. Collaborative Ocular Oncology Group Report Number 1: Prospective Validation of a Multi-Gene Prognostic Assay in Uveal Melanoma. *Ophthalmology*. 2012;119(8):1596-1603.
29. Decatur CL, Ong E, Garg N, et al. Driver Mutations in Uveal Melanoma: Associations With Gene Expression Profile and Patient Outcomes. *JAMA Ophthalmol*. 2016;134(7):728-733.
30. Krantz BA, Dave N, Komatsubara KM, Marr BP, Carvajal RD. Uveal melanoma: epidemiology, etiology, and treatment of primary disease. *Clin Ophthalmol*. 2017;11:279-289.
31. Fong A, Lee L, Glasson W. Pediatric choroidal melanoma in a 13-year-old girl-a clinical masquerade. *J AAPOS*. 2011;15(3):305-307.
32. Marko M, Leško P, Jurenová D, Furda R, Greguš M. Importance of PET/CT examination in patients with malignant uveal melanoma. *Cesk Slov Oftalmol*. 2020;76(1):37-44. doi: 10.31348/2020/5