

BLOW-IN FRACTURE OF ORBITAL ROOF. A CASE REPORT

Lubojacký J.¹, Masárová M.¹, Plášek, M.^{1,2}, Benda F.^{2,3},
Komínek, P.^{1,2}, Matoušek, P.^{1,2}

¹ Department of Otorinolaryngology and Head and Neck Surgery,
University Hospital Ostrava

² Department of Craniofacial Surgery, Faculty of Medicine,
University of Ostrava

³ Department of Ophthalmology, University Hospital Ostrava

Declaration on conflict of interests:

I hereby declare that no conflict of interest exists in the compilation, theme and subsequent publication of this article, and that it has not been supported by any pharmaceuticals company. This declaration relates also to all the co-authors.

The study was conducted with the support of the project for Institutional Support of the Ministry of Health of the Czech Republic, RVO – FNOs/2019

Sworn declaration:

The authors declare that no conflict of interest exists in the compilation, theme and subsequent publication of this article, and that it is not supported by any pharmaceuticals company. The study has not been submitted to any other journal or printed elsewhere.

Received: 9 July 2020

Accepted: 23 November 2020

Available on-line: 11 March 2021



MUDr. Jakub Lubojacký
Klinika otorinolaryngologie
a chirurgie hlavy a krku,
Fakultní nemocnice Ostrava
17. listopadu 1790
708 52 Ostrava
jakub.lubojacky@fno.cz

SUMMARY

Orbital fractures may be accompanied with severe damage of the eye bulb and other intraorbital tissues. Early clinical findings can be very mild, therefore it is vital to actively seek not only for any damage done to the soft tissues of the orbit, but also for extraorbital complications such as liquorrhea or meningitis. We report a relatively rare case of blow-in fracture of orbital roof in eleven years old boy. Patient was admitted to the emergency care after falling off a bicycle without impaired consciousness. During admission ophthalmologist evaluated the condition as severe contusion of the left bulb, with hemophthalmia and retinal comotosis. Due to significant swelling of eye lids and periorbital hematoma, it was not possible to perform specific tests to objectify possible oculomotor disorder and diplopia. CT scan findings show dislocated fracture of orbital roof with fragments reaching into the musculus rectus superior. For high risk of bulbus penetration and muscle damage a surgical intervention with bone fragments removal was performed using endoscopic assisted frontal orbitotomy. After operation patient had no signs of functional eye disorder.

Key words: Orbital fracture, blow-in fracture, orbital roof fracture, facial trauma, endoscopic assisted frontal orbitotomy

Čes. a slov. Oftal., 77, 2021, No. 1, p. 45–49

INTRODUCTION

Fractures affecting the central third of the facial skeleton may be accompanied by serious injuries to associated soft-tissue structures. In the case of orbital fractures, this especially concerns the risk of damage to the eyeball, the optic nerve and oculomotor muscles [1]. The degree of injury and clinical symptoms depends on the affected region, the direction of the acting force, or the presence of any applicable intraorbital or retrobulbar haemorrhage.

Orbital fractures are most often a part of more extensive

traumas, while isolated blow-in fractures of the orbit are a rare finding [1]. However, for this reason their diagnosis may often be inadequate as a result of a meagre and non-specific clinical finding, with fatal consequences for the patient's sight [1,2,4].

CASE REPORT

An eleven year old boy was admitted to the accident and emergency department of the University Hospital in Ostrava after falling off his bicycle. He did not remember the cir-

cumstances of the injury, subjectively pains in the left eye and head predominated. Upon admittance the boy was conscious, rhinoscopy determined the presence of traces of epistaxis, without signs of liquorrhea. Locally there was present severe contusion of the eyelids, emphysema and periorbital haematoma in the left eye, due to which it was not possible to objectify in detail any potential oculomotor disorder and diplopia. Upon an ocular examination, the eyeball was toned, without a pathological finding on the anterior segment, pupil reactions were within the norm. Ophthalmoscopy determined partial hemophthalmia, with retinal comotosis and retinal haemorrhages in the upper quadrants.

A computer tomography (CT) examination detected a blow-in fracture of the orbital roof on the left side, with a bone fragment reaching intraorbitally into the musculus rectus superior, and extraorbital haemorrhage above the upper rectus muscle (Fig. 1, 2). There was also a present fissure of the posterior wall of the frontal sinus, of the roof of anterior ethmoids bilaterally, and subdural pneumocephalus (Fig. 3).

The bone fragment was in close contact with the eyeball behind the equator, embedded in the musculus rectus superior. It was not possible to exclude the possibility of injury to the sclera. Due to the risk of further damage to the soft tissues of the orbit by bone fragments upon movement of the eye, a surgical procedure was indicated. No passive duction test was performed preoperatively, due to fears of penetration of the eyeball by the bone fragment.

An endoscopic assisted frontal upper orbitotomy was performed under general anaesthesia, with the use of navigation. Perioperatively two caudally inwardly projecting fragments were identified in the central part of the roof (Fig. 4). No defect of the dura mater was observed,

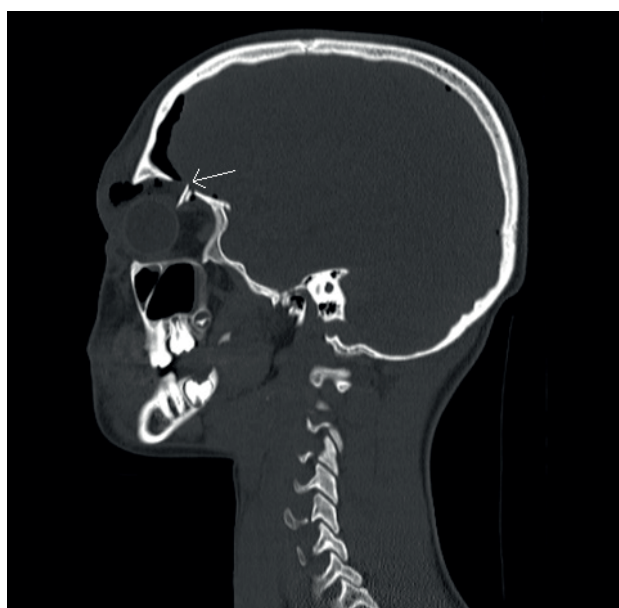


Fig. 1. Blow-in fracture of orbital roof with dislocated fragment reaching into the musculus rectus superior (arrow), CT examination, sagittal section

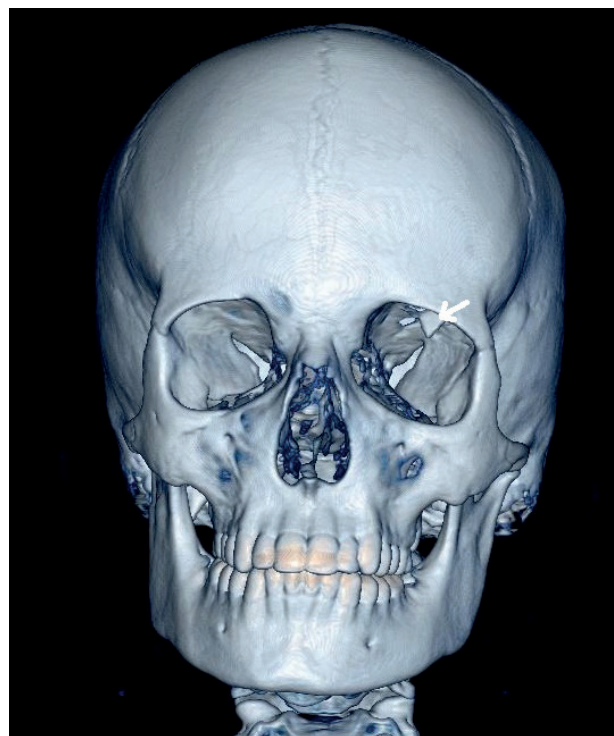

Fig. 2. Blow-in fracture of roof of left orbit with dislocated fragment reaching into the orbit (arrow), CT examination, 3D reconstruction

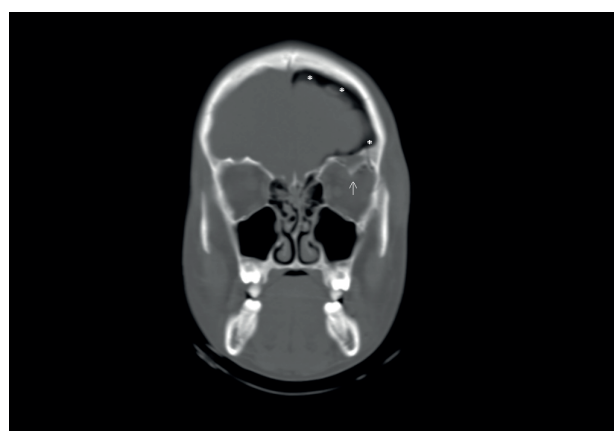


Fig. 3. Blow-in fracture of orbital roof with dislocated fragment (white arrow), pneumocephalus (star), CT examination, coronary section

the retina by number 10. The crack was treated by laser photocoagulation of the retina. At a follow-up examination 2 years after surgery, the boy was without subjective complaints, complete resorption of hemophthalmia had taken place, and the finding on the anterior and posterior segment was stable.

DISCUSSION

Orbital fractures are divided according to mechanism into "blow-in" and "blow-out" fractures. Blow-out fractures

occur upon direct blunt trauma to the region of the orbital opening (tennis ball, knee). The subsequent increase of orbital pressure leads to a blow-out fracture, most frequently of the medial wall or floor of the orbit, and prolapse of the content into the jaw cavity or ethmoid sinuses, while contusion of the eyeball need not necessa-

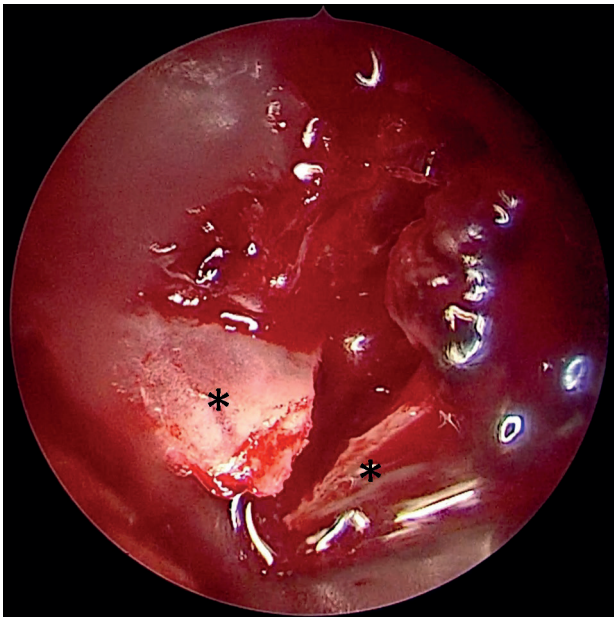


Fig. 4. View of dislocated fragments of orbital roof (stars), access from endoscopic assisted frontal upper orbitotomy, endoscopic view

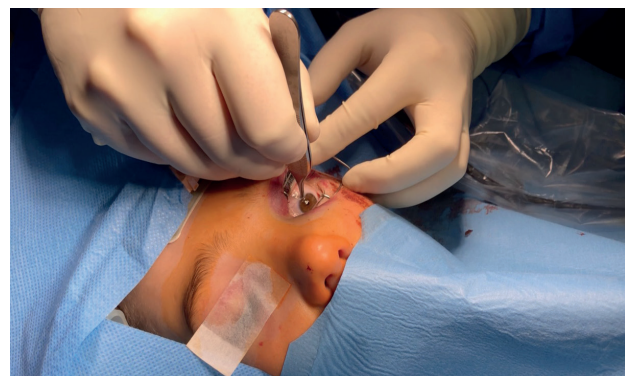
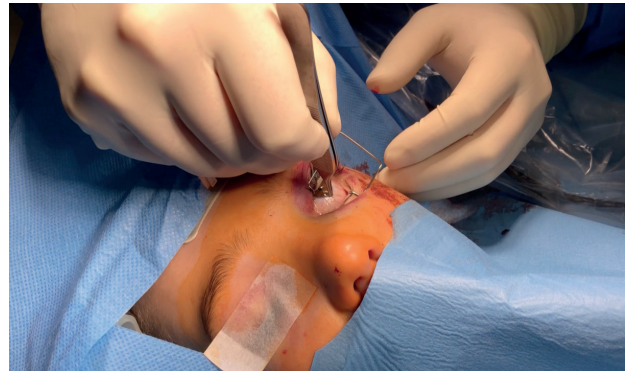
Fig. 5. (A) Test of passive motility of eyeball, upward gaze without limitation, perioperative image (B) Test of passive motility of eyeball, downward gaze without limitation, perioperative image

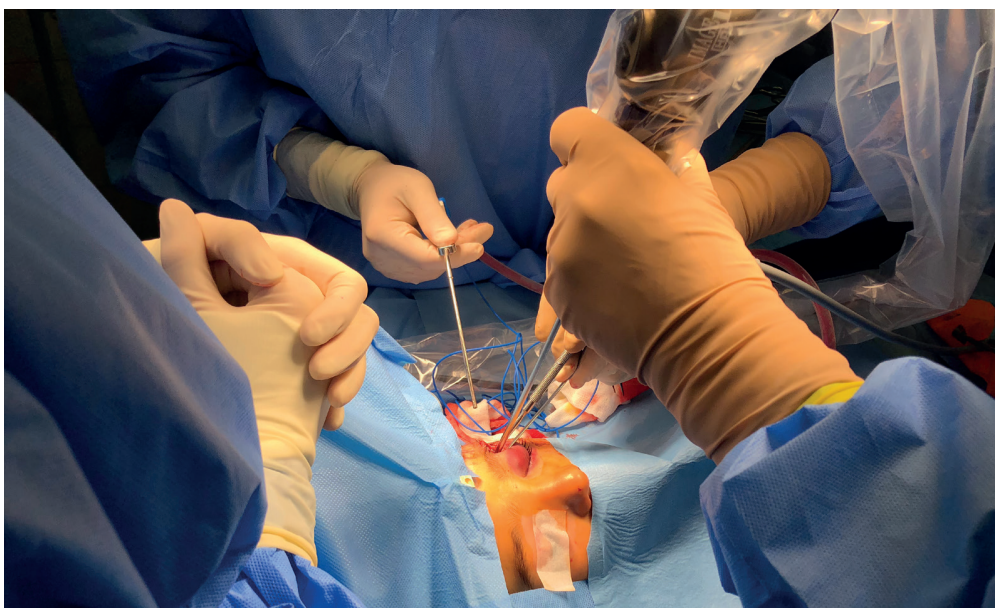

Fig. 6. Access to orbit by means of upper frontal orbitotomy, perioperative image

rily be large [3]. By contrast, smaller injuring objects (golf ball) mostly cause larger contusion, with a less pronounced increase of intraorbital pressure and a lower risk of fracture of the orbital wall.

Blow-in fractures are usually localised in the roof and lateral wall of the orbit. They are defined as dislocation of a fragment of the roof or lateral wall of the orbit in the direction of the soft tissues of the orbit [3,4]. They occur due to the effect of a blunt force on the skull bone, typically in the region of the forehead and temple. The reduction of the front-to-back dimensions of the orbital roof at the moment of impact causes a fracture, and projection of the fragment in the direction into the orbit, while the orbital margin may remain intact [3,4]. Blow-in fractures are linked with a higher risk of injury to the intraocular muscles, eyeball and optic nerve by bone fragments.

Isolated blow-in fractures are rare consequences of traumas to the face and head. Statistically only 1-9 % of fractures to the facial bones also incorporate damage to the orbital roof [5,6]. They most frequently occur at the age of between 20 and 40 years, with a predominance of as high as 90 % in men. In children they occur most frequently between the ages of 3 and 5 years, and are represented equally among boys and girls [5]. Isolated fractures of the orbital roof with dislocation of a fragment are a rare finding, and are more often a part of multi-systemic traumas and neurocranial injuries [1].

Blow-in fractures may be clinically manifested upon dislocation of a fragment into an oculomotor muscle in the form of disorder of motility of the eyeball and diplopia, but may also be entirely asymptomatic [6,7,10,11,12]. In the diagnosis of orbital fractures, it is of essential importance to fully assess the scope of the injury. With regard to the low incidence of isolated fractures of the orbital roof, it is always necessary to examine for the possibility of associated fractures of the facial bones and skull, to exclude the possibility of intracranial injury such as intracranial haemorrhage, haematoma, concussion, brain herniation, liquorrhea, and in the case of affliction of the orbit to assess damage to the intraorbital soft tissues, especially the oculomotor muscles, optic nerve and eyeball [6,7,12].

In our patient this concerned an isolated fracture of the upper orbital wall and dislocation of fragments caudally into the superior rectus oculomotor muscle and the soft tissues of the orbit. These dislocations are typical of blow-in fractures, causing a reduction of the volume of the orbit and directly threatening permanent damage to the patient's sight. The clinical picture in our case was very non-specific and masked by pronounced periorbital contusion and haematoma, due to which the patient could not be examined for diplopia and oculomotor disorders.

The dominant diagnostic method is CT examination with a section width of 0.6 mm. For evaluation of the soft tissues of the orbit (e.g. contusion in the region of the orbital apex) it is suitable to add magnetic resonance imaging (MRI) [6,7,8].

Both the decision on the therapeutic procedure and any applicable surgical intervention should be performed

by an interdisciplinary team comprising an ear, nose and throat specialist, ophthalmologist and neurosurgeon. Asymptomatic patients may be treated conservatively, even in the case of injury to the dura mater with temporary liquorrhea or signs of pneumocephalus, on the precondition that the clinical course is favourable and control CT demonstrates resorption of air and regression of pneumocephalus, and if liquorrhea disappears within 5-7 days [9]. The disadvantage of a conservative procedure is the risk of insufficient closure in the place of injury to the dura mater and the possibility of transmission of the infection, with the occurrence of meningitis.

Patients with persistent liquorrhea, disorder of vision or motility of the eyeball, or patients with an unequivocal finding of dislocated fragments into the soft orbital tissues on CT are indicated for a surgical solution. Operations may be performed from different approaches, in which the aim is to remove the dislocated bone fragments and a review or reconstruction of the orbital roof [6,9,10,11].

The most frequently used approach to the solution of pathologies of the anterior half of the orbit is frontal orbitotomy, in which the orbit is penetrated following the performance of a skin or conjunctival incision. According to the place of incision, we then differentiate between upper, lower, medial and lateral frontal orbitotomy [1,13]. The disadvantage of frontal orbitotomy is the very narrow room for manoeuvre between the orbital wall the eyeball, as a result of which it is necessary to push back the eyeball during operations. The risk of injury during these operations is substantial [1,13].

In our case, an endoscopic assisted approach was chosen by means of frontal upper orbitotomy (Fig. 7, 8). Unlike classic orbitotomy, the use of an endoscope offers better illumination and display of the operating field, using a less invasive approach from a smaller incision [1]. It also enables better accessibility of lesions localised in the orbital apex, which may be inaccessible by a classic open technique without the use of an endoscope.

An alternative to an approach from frontal orbitotomy is an approach via pterional craniotomy, the disadvantage of which is the necessity of retraction of the brain tissue and a markedly worse cosmetic effect in connection with the possibility of postoperative atrophy of the temporal muscle.

CONCLUSION

Blow-in fractures of the orbit occur due to the effect of blunt force on the region of the forehead or temple. They may result in damage to the intraorbital structures, with functional consequences. In diagnosis and decision on the therapeutic procedure, it is essential to thoroughly assess the condition of the surrounding facial bones, exclude the possibility of intracranial injury and damage to the soft tissues of the orbit. Treatment of dislocated fractures should take place under the guidance of an interdisciplinary team. In indicated cases, an appropriate surgical solution may be endoscopic assisted frontal upper orbitotomy, which is less invasive in comparison with classic open techniques.

LITERATURE

1. Matoušek P, Lipina R, Diblík P, et al. Chirurgie očníce. 1st ed. Havlíčkův brod (Česká republika): Tobíáš; 2020. Kapitola 24, Poranění očníce; 250–255.
2. Williams JL, Rowe NL. Rowe and Williams' maxillofacial injuries. 2nd ed. New York: Churchill Livingstone; 1994. 1014.
3. Jones AL, Jones KE. Orbital Roof "Blow-in" Fracture: A Case Report and Review. J Radiol Case Rep. 2009 Dec;3(12):25–30.
4. Karabekir HS, Gocmen-Mas N, Emel E, et al. Ocular and periocular injuries associated with an isolated orbital fracture depending on a blunt facial trauma. J Craniomaxillofac Surg. 2012 Oct;40(7):189–193.
5. Chapman VM, Fenton LZ, Gao D, Strain JD. Facial fractures in children: unique patterns of injury observed by computed tomography. J Comput Assist Tomogr. 2009 Jan;33(1):70–72.
6. Haug RH, Van Sickels JE, Jenkins WS. Demographics and treatment options for orbital roof fractures. Oral Surg Oral Med Oral Pathol Oral Radiol Endod. 2002 Mar; 93(3):238–246.
7. Lee H, Jilani M, Frohman L, Baker S. CT of orbital trauma. Emerg Radiol. 2004 Feb;10(4):168–172.
8. Hopper RA, Salemy S, Sze RW. Diagnosis of midface fractures with CT: what the surgeon needs to know. Radiographics. Jun 2006;26(3):783–793.
9. Losee JE, Afifi A, Jiang S, et al. Pediatric orbital fractures: classification, management, and early follow-up. Plast Reconstr Surg. 2008 Sep;122(3):886–897.
10. Cossman JP, Morrison CS, Taylor HO, et al. Traumatic orbital roof fractures: interdisciplinary evaluation and management. Plast Reconstr Surg. 2014 Mar;133(3):335–343.
11. Cook T. Ocular and periocular injuries from orbital fractures. J Am Coll Surg. 2002 Dec;195(6):831–834.
12. Somasundaram A, Laxton AW, Perrin RG. The clinical features of periorbital ecchymosis in a series of trauma patients. Injury. 2014 Jan;45(1):203–205.
13. Bartoňková K, Šlapák I. Transkonjunktivální přístup k blow-out frakturám očníce u dětí. Otorinolaryng a foniatrie Praha. 2011;60(4):218–222.