

# CHANGE OF CENTRAL AND PERIPHERAL VISION IN PATIENT WITH SYMPTOMATIC CYST OF RATHKE'S CLEFT FOLLOWING TRANSSPHEROIDAL RESECTION

## SUMMARY

A seventy-six-year-old female was acutely admitted to the Eye Clinic of the University Hospital in Martin with a 1 month history of impaired central and peripheral vision on the right eye. At the admission patient's right eye VA was fingers at 20 cm, the left eye had a central vision preserved. Magnetic resonance of the brain and orbits demonstrated cystic tumor expansion in the sellar region with compression of optic chiasm and optic nerves (more on the right side), in diff. dg. as cystic macroadenoma of the pituitary gland. Endocrinological examination found secondary hyperprolactinaemia from pituitary oppression, other hormonal parameters were without deviation. Consequently, the ENT examination recommended endoscopic resection via the transsphenoid approach. After resection of the lesion and histological examination of the sample, the finding was evaluated as a Rathke's cleft cyst. Symptomatic Rathke's cleft cysts of pituitary gland are rare, but the visual symptoms are typical findings due to chiasm proximity. On ophthalmological examination 3 weeks after surgery has central vision increased significantly (VOD 6/9) on the right eye and peripheral vision has partially adjusted on both eyes.

**Key words:** Rathke's cleft cyst, perimeter, central visual acuity, transsphenoidal endoscopic resection

Čes.a slov. Oftal., 74, 2018, No.2, p. 73-78

## INTRODUCTION

Rathke's cleft cyst is a benign lesion growing from the epithelial layers of the Rathke's pouch in the region of the sella turcica, and is most frequently located in the posterior part of the frontal lobe of the pituitary gland. It usually reaches a diameter of 10-20 mm [2]. Asymptomatic cysts are relatively common, during autopsies of patients they have been found in 12-33% of autopsies [18]. However, symptomatic cysts are a rare finding, 155 cases had been described in the literature up to 2017 [19]. They occur twice as frequently in women as in men. Symptomatic cysts are manifested by cephalgia, disorders of vision or endocrinological symptoms [11]. In certain cases an increased level of serum prolactin has been recorded in patients with a cyst of the Rathke's cleft. In total, they represent approximately 2% of all lesions of the sella turcica [21].

## CASE REPORT

A seventy-six year old female patient with a one-month anamnesis of disorder of vision in the right eye was admitted in acute condition at the Department of Ophthalmology at Martin University Hospital on 13 December 2017 for the purpose of comprehensive differential diagnostics. The patient was unable to determine whether the disorder had occurred gradually or suddenly, she stated deteriorated –

blurred both distance and near vision. She did not state any pain in the eye, including upon movement of the eye-balls, and also did not state any headache. She stated that there had been no injuries to the eyes, in childhood and youth she had not worn glasses, she saw equally in both eyes, according to the documentation she had amblyopia laevis o. utr.. In April 2016 she had undergone cataract surgery with the use of monofocal intraocular lenses Lentis L312 (Oculentis, Germany), postoperative vision with correction VOD 6/9, VOS 6/9. The objective finding on the anterior segment and fundus did not explain the change of vision, see ophthalmological finding and fig. 1.

From her personal anamnesis the patient was being treated for arterial hypertension, chronic ischaemic heart disease (NYHA II), hyperlipoproteinemia, rheumatic polymyalgia, multi-infarct encephalopathy and vertebrogenic algic syndrome. The patient chronically used trandolapril, acetylsalicylic acid, methylprednisolone, nimesulide, paracetamol, tramadol, atorvastatin, cholecalciferol and calcium.

On magnetic resonance of the brain a finding of lobed cystic tumorous expansion was described in the region of the sella turcica and optic chiasm, with post-contrast saturation only of the periphery of the cystic tumour with slight right-sided parasellar spreading and with

Halička J.<sup>1</sup>, Haličková T.<sup>2</sup>, Vargončíková L.<sup>1</sup>, Fedorová M.<sup>1</sup>, Kapitanová K.<sup>1</sup>, Sičák M.<sup>2</sup>, Kališ A.<sup>3</sup>, Žiak P.<sup>1</sup>

<sup>1</sup>Department of Ophthalmology, University Hospital Martin, Head Doctor MUDr. Peter Žiak, PhD.

<sup>2</sup>Department of ENT and head and neck surgery, Central Military Hospital Ružomberok, Head Doctor MUDr. Marián Sičák, PhD.

<sup>3</sup>Institute of Pathological Anatomy, Central Military Hospital Ružomberok, Head Doctor MUDr. Adrian Kališ, PhD.

*The authors of the study declare that no conflict of interest exists in the compilation, theme and subsequent publication of this professional communication, and that it is not supported by any pharmaceuticals company.*



MUDr. Juraj Halička, PhD.  
Očná klinika  
Univerzitná nemocnica Martin  
Kollárova 2  
036 59, Martin, SR  
euraay@gmail.com

suprasellar extension, see fig. 3. According to visual evoked potentials, the absolute values of latency were within the norm, in the right eye amplitude was borderline, with a conclusion of suspect axonal lesion of visual pathway in the right eye. An endocrinological examination was supplemented, with statement of secondary hyperprolactinaemia from compression of the pituitary gland, otherwise the hormonal parameters were without discrepancy.

#### Ophthalmological finding

##### A) Objective finding before surgery

**VOD:** natural fingers to 0.5 m, correction does not help

**VOS:** natural 6/18, cc.  $-1.75/75^\circ$  DCyl = 6/12

**IOP:** o.utr.: 15/15 torr

**Colour vision o.dx.:** -

**o.sin.:** colour vision correct

**Goldmann perimeter 4/III 12.12.2017:** constriction of visual field from periphery to  $30-50^\circ$  centrally

**Computer perimeter 21.12.2017** – see fig 2.

**O.utr.:** surrounding area of eye without pathological finding, eyeballs in direct position, without protrusion, oculomotor function within norm, lower tarsal conjunctiva pacific, concretions, on margin small quantity of frothy secretion, bulbar conjunctiva pacific, conjunctival sac clear, cornea smooth, Shagreen type keratopathy, anterior chamber deep, clear, pupil round, loose, isocoria, in right eye positive relative afferent pupillary defect, PC IOL in situ, reflex of fundus pink, vitreous body fibrous.

**OP o. utr.:** optic nerve papilla bordered, temporally discoloured, macular landscape and fundus tabled, capillaries with hypertonic-sclerotic changes, fundus without deposit changes.

**OCT Spectralis o.utr.:** incipient hyperreflective lines on surface of retina, without edema, without signs of subretinal fluid.

**OCT RNFL o.dx.:** NS borderline beneath norm

**o.sin.:** N borderline beneath norm

##### B) Objective finding 3 weeks after surgery

**VOD:** natural 6/12 cc.  $-0.75/100^\circ$  DCyl = 6/9

**VOS:** natural 6/12, cc.  $-1.75/75^\circ$  DCyl = 6/9

**IOP:** 15/10 torr

**Colour vision o.dx.:** correct

**o.sin.:** correct

**Computer perimeter o.dx.30°:** regression of finding from 21.12.2017, then perimeter on PO not feasible, at that time central part of visual field preserved with progressive significant reduction of visual field in direction of periphery

**o.sin. 30°:** regression of finding from 21.12.2017, preservation of central and pericentral visual field nasally to  $15^\circ$ , otherwise pronounced reduction of sensitivity

**o.utr.:** without change

**OP o. utr.:** without change

**OCT Spectralis o.utr.:** slight reduction of CRT by  $5\ \mu\text{m}$  in right eye, by  $4\ \mu\text{m}$  in left eye

**OCT RNFL o.utr.:** without change

##### Therapy:

The patient was sent for an ear, nose and throat conciliatory examination to the Central Military Hospital in Ružomberok, where an endoscopic resection via transsphenoidal approach was recommended. After the supplementing of the preoperative examinations, the patient was operated on at the ENT department of the Central Military Hospital via a transsphenoidal endoscopic approach, perioperatively there was a finding of compressed tissue of the pituitary gland on the periphery of the sella turcica by a cystic formation with partially intrasellar location, but in larger part suprasellar above the diaphragm of the pituitary gland, in which the cyst had ventrally forced out the optic chiasm (fig. 5). Duraplasty was performed due to perioperative liquorrhoea. On the 1st postoperative day the patient started a pronounced improvement of vision. The material formed by the mucous membrane covered by the squamous epithelium was histologically processed without dysplastic changes, the finding was assessed as a Rathke's cleft cyst

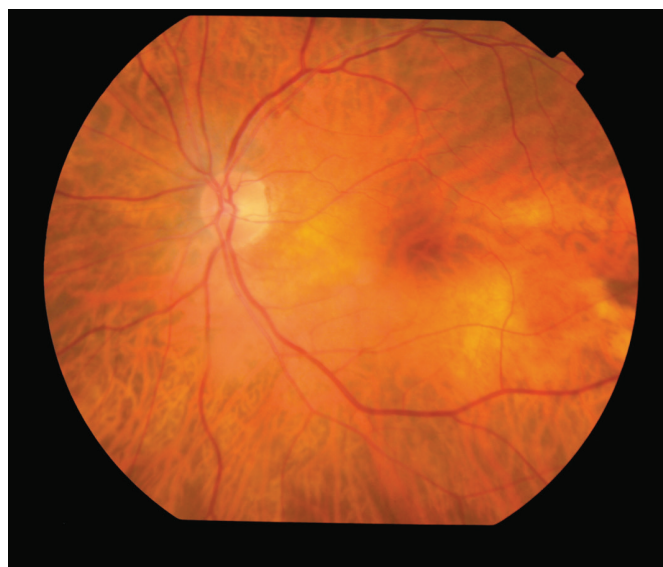
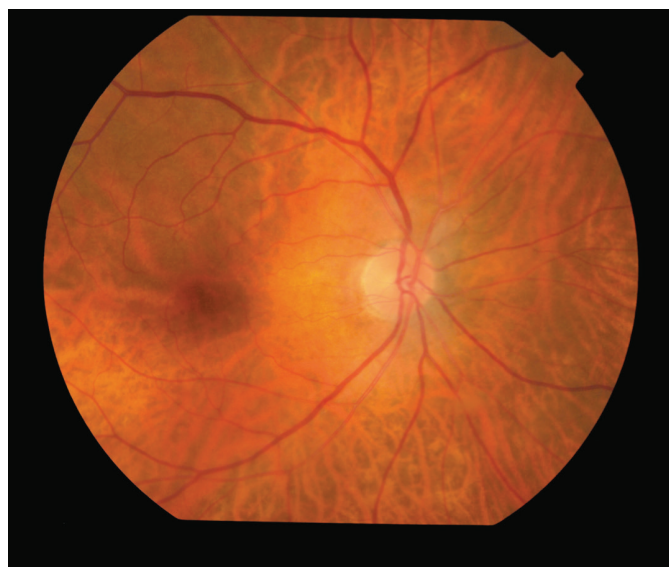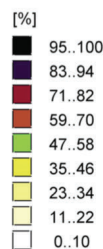
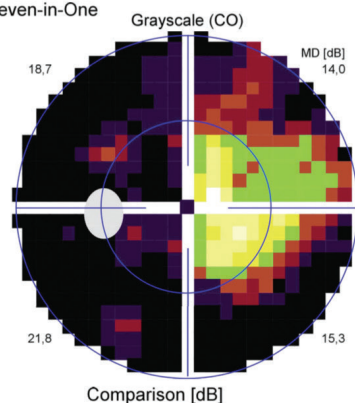


Fig. 1a, b: Fundoscopy – bilateral findings of temporally pale papilla of the optic nerve.

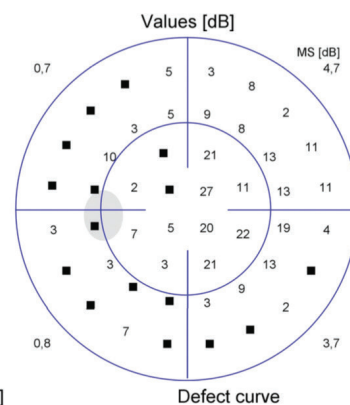
Fig. 2a, b, c: Perimeter 30° before and after surgery, note: it was not possible to preoperatively perform perimeter on the right eye - due to low CVA, patient was unable to fix. On the perimeter of the left eye, a significant increase is visible in the field of vision in 30° 3 weeks after resection of Rathke's cleft cyst.

#### Left eye (OS) / 21.12.2017 / 10:25:54

Seven-in-One

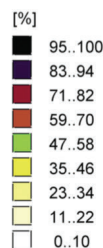
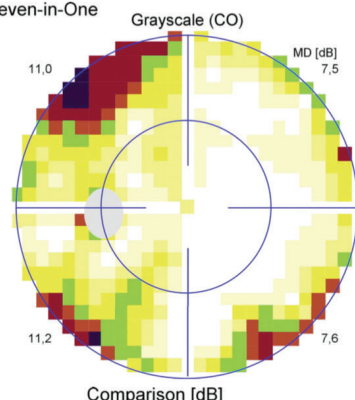


Corrected comparisons [dB]

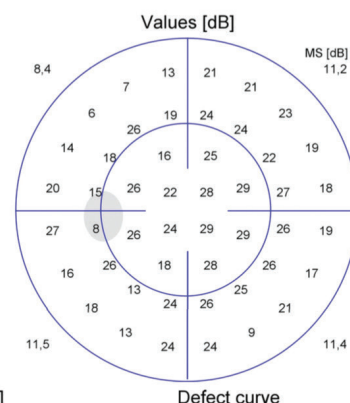


#### Left eye (OS) / 29.01.2018 / 08:08:48

Seven-in-One


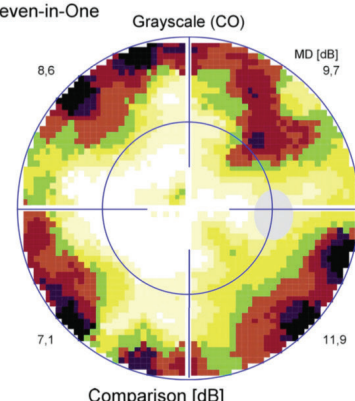


Corrected comparisons [dB]

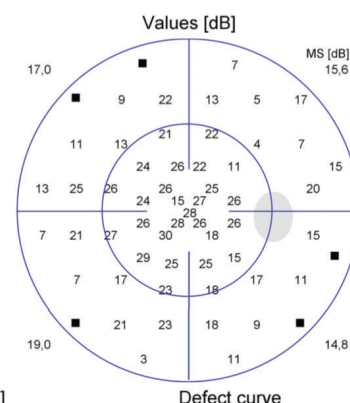


#### Right eye (OD) / 29.01.2018 / 08:43:55

Seven-in-One



Corrected comparisons [dB]



(fig. 4). The postoperative course was complicated by rhinoliquorrhoea, as a result of which revision duraplasty was performed. In the further postoperative period the patient was without complaints.

#### Differential diagnostics

Differential diagnostics for a Rathke's cleft cyst incorporate craniopharyngioma, cystic adenoma of the pituitary gland, arachnoid cyst and epidermoid cyst [13]. Upon the initial diagnosis patients with an arachnoid cyst are in most cases older than patients with a cyst of the Rathke's cleft or craniopharyngioma. Changes of vision and headaches are common in the case of all cystic lesions, a psychiatric deficit is typical of craniopharyngioma. Calcification or solid components in imaging examinations are also rather

typical of craniopharyngioma [17].

Craniopharyngiomas are benign, suprasellar tumours derived from the Rathke's cleft, which often originate in the proximity of the stalk of the pituitary gland, and are large and locally invasive. More than a half of all patients with craniopharyngiomas report for treatment before reaching the age of 20 years, usually with symptoms of increased intracranial pressure, headaches, vomiting, papilledema and hydrocephalus. In childhood age these tumours comprise approximately 56% of sellar and suprasellar tumours, but may in rare cases also appear in older individuals [9].

Cystic adenoma of the pituitary gland may resemble a cyst of the Rathke's cleft. Of importance in magnetic resonance



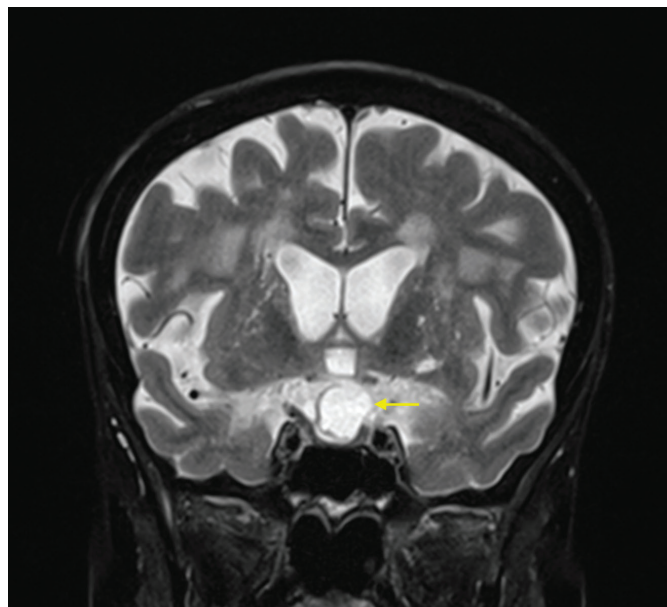
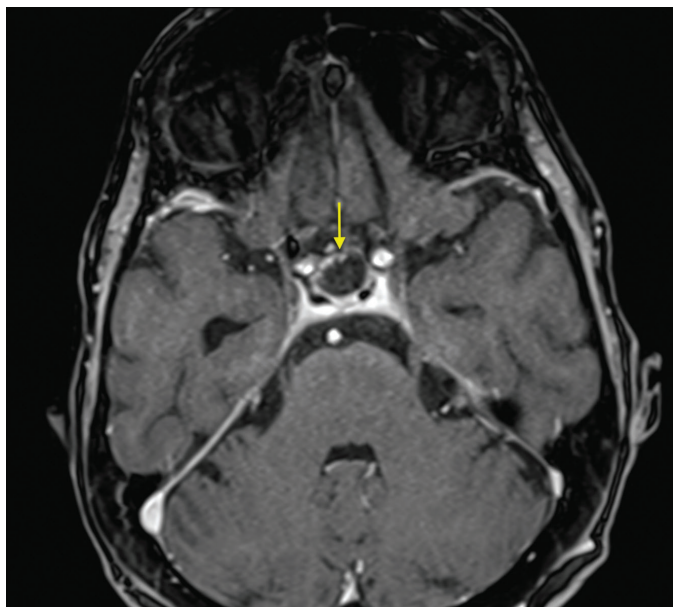


Fig. 3a, b: Magnetic Resonance Imaging: A) Axial section with hypo-intensive cystic structure in the pituitary region (T1WI), post-contrast increase in intensity only in the periphery of the cystic tumour with slight parasellar spreading and suprasellar extension on right side, indicated by arrow. B) In the coronal section (T2WI) with hyper-intensive signal in location of cyst, indicated by arrow.

imaging, from the perspective of differential diagnostics, are the presence of the level of fluid, sepsis, lateralisation of the cyst and presence of intracystic nodosity [14].

Arachnoid cysts are a common chance finding upon intracranial magnetic resonance imaging in all age groups. The majority have a benign course, they occur more frequently in men and the prevalence is approximately 1.4% [1].

Epidermoid cysts are lesions developed from the neuroectodermal epithelial cells. These are benign lesions, which in rare cases undergo malignant transformation, characterised by a white pearly capsule containing crystals of cholesterol and lamellar keratin [16]. Intracranial localisation of these lesions is unusual, which represents 1.5% of all epidermoid tumours and 0.3% - 1.8% of all intracranial tumours [8].

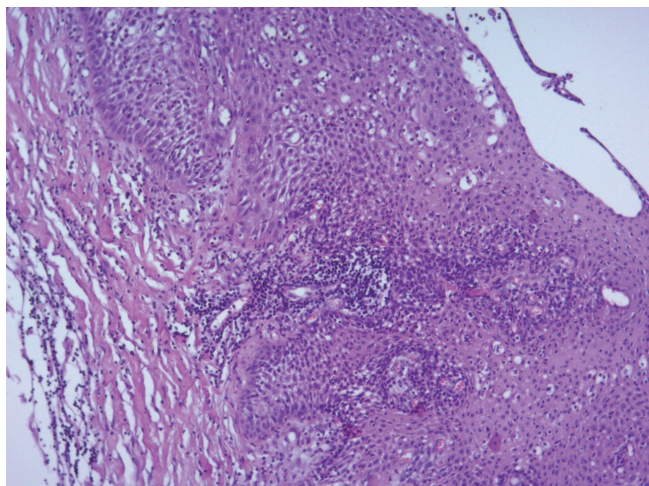


Fig. 4: Histological sample of the cyst (HE staining, magnification 100x) - mucosa covered with squamous epithelium, without dysplastic changes.

## DISCUSSION

Symptomatic Rathke's cysts are very rare, to date 155 cases have been published [19]. Visual symptoms need not always be present in the case of a symptomatic Rathke's cleft cyst. In a study with 11 symptomatic patients [15], 8 patients with visual symptoms were presented. In a further study visual symptoms occurred in 47% of patients [3], the symptoms included reduced visual acuity, atrophy of the optic nerve papilla and defects of the visual field.

Compression of the pituitary gland in the case of a Rathke's cleft cyst may very often cause a change in the flushing out of hypophyseal hormones. The most common endocrinological changes include diabetes insipidus, amenorrhoea and/or galactorrhoea, and sometimes even panhypopituitarism [3]. Hypopituitarism in early age may be connected with retardation of growth [20]. Other described symptoms are impotence or low libido as the most common endocrine abnormality in men, and hyperprolactinaemia in women [17].

A typical finding in imaging examinations is a non-calcified intrasellar and/or suprasellar cyst with an intracystic node. According to magnetic resonance, they are most often divided into a Rathke's cleft cyst with low intensity signal upon T1 weighting and high intensity signal upon T2 weighting, or with high intensity signal upon T1 weighting and fluctuating intensity signal upon T2 weighting [11].

Transsphenoidal resection is the most frequent surgical procedure upon treatment of a Rathke's cleft cyst [21]. In the case of a transsphenoidal approach, the entire cyst is removed (extirpated) via the sphenoid cavity, or it is opened and drained into the sphenoid cavity (marsupialised). This method is effective and helps preserve the function of the pituitary gland. Duraplasty is necessary if a leakage of cerebrospinal fluid is determined during the operation. In certain cases, when the cyst is not accessible

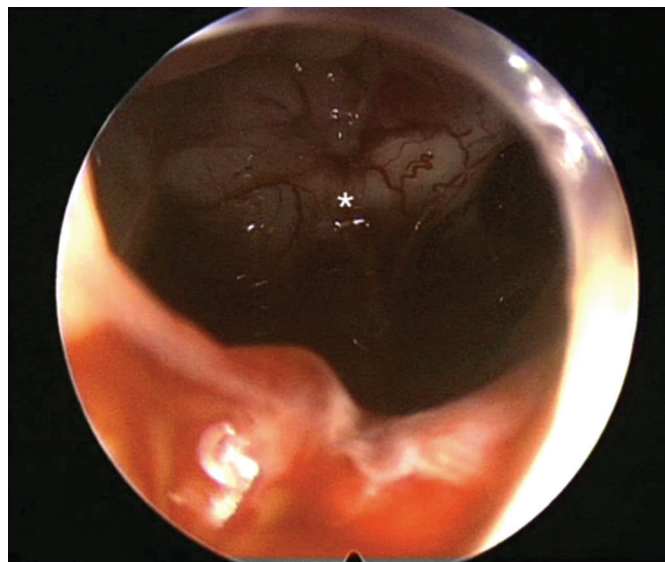
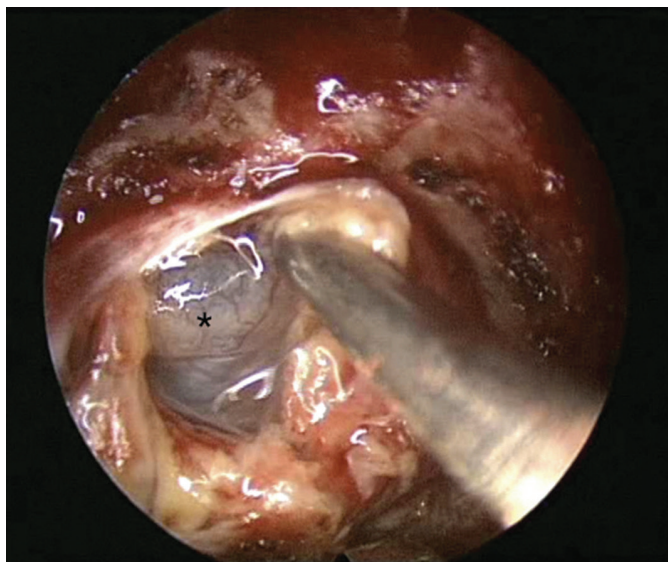


Fig. 5a, b: Surgery image: above) visible cyst on left side of probe, indicated with a \* mark, below) visible optic chiasma at the bottom after removal of the entire cyst, indicated with a \* mark.

by this surgical approach, it is necessary to perform craniotomy.

In our patient it was necessary to perform a surgical revision with duraplasty due to postoperative rhinoliquorrhoea, which is a relatively frequently described postoperative complication (7.1% of patients), further relatively commonly described postoperative complications are diabetes insipidus (3.6% of patients) and meningitis (3.6% of patients) [4].

According to the case report of a 68-year-old female patient, an improvement in the functionality of the occipital-visual cortex [7], corresponding to a functional change in peripheral vision, was demonstrated on functional magnetic resonance imaging 3

months after the surgical procedure for a Rathke's cleft cyst. As in our case, in the literature also information is available about a partial return of central and peripheral vision. Postoperative improvement of ophthalmological symptoms is described in 70% of patients, improvement of neurological symptoms in 71% of cases and endocrinological symptoms improved in more than 65% of patients [4].

Upon sudden deterioration of central vision in older age without a finding on the ocular fundus, it is necessary to consider also central causes. Following an adequate surgical procedure it is possible to achieve a partial improvement of central and peripheral vision.

## LITERATURA

1. **Al-Holou, WN., Terman, S., Kilburg, C. et al.:** Prevalence and natural history of arachnoid cysts in adults. *J Neurosurg*, 118; 2013: 222-31.
2. **Česák, T., Náhlavský, J., Látr, I. et al.:** Symptomatic cysts of Rathke's cleft. (Symptomatické cysty Rathkeho pouzdra). *Cesk Neurol Neurochir*, 68; 2005: 58-63.
3. **Eguchi, K., Uozumi, T., Arita, K. et al.:** Pituitary function in patients with Rathke's cleft cyst: significance of surgical management. *Endocr J*, 41; 1994: 535-40.
4. **el-Mahdy, W., Powell, M.:** Transsphenoidal management of 28 symptomatic Rathke's cleft cysts, with special reference to visual and hormonal recovery. *Neurosurgery*, 42; 1998: 7-16; discussion 16-7.
5. **Field GD., Gauthier, JL., Sher, A. et al.:** Functional connectivity in the retina at the resolution of photoreceptors. *Nature*, 467; 2010: 673-7.
6. **Frank, G., Sciarretta, V., Mazzatenta, D. et al.:** Transsphenoidal endoscopic approach in the treatment of Rathke's cleft cyst. *Neurosurgery*, 56; 2005: 124-8.
7. **Chouinard, PA., Striemer, CL., Ryu, WH. et al.:** Retinotopic organization of the visual cortex before and after decompression of the optic chiasm in a patient with pituitary macroadenoma. *J Neurosurg*, 117; 2012: 218-24.
8. **Iaconetta, G., Carvalho, GA., Vorkapic, P. et al.:** Intracerebral epidermoid tumor: a case report and review of the literature. *Surg Neurol*, 55; 2001: 218-222.
9. **Larkin, S., Karavitaki, N.:** Recent advances in molecular pathology of craniopharyngioma. *F1000Res*, 6; 2017: 1202.
10. **Mukherjee, JJ., Islam, N., Kaltsas, G. et al.:** Clinical, radiological and pathological features of patients with Rathke's cleft cysts: tumors that may recur. *J Clin Endocrinol Metab*, 7; 1997: 2357-62.
11. **Naik, VD., Thakore, NR.:** A case of symptomatic Rathke's cyst. *BMJ Case Rep*, 25; 2013: 2013.
12. **Nakasu, Y., Isozumi, T., Nakasu, S. et al.:** Rathke's cleft cyst: computed tomographic scan and magnetic resonance imaging. *Acta Neurochir (Wien)*, 103; 1990: 99-104.
13. **Neřůka, D., Masopust, V., Beneš, V.:** Pituitary adenoma therapy (Léčba adenomů hypofýzy). *Cesk Slov Neurol N*, 3; 2011: 240-253.
14. **Park, M., Lee, SK., Choi, J. et al.:** Differentiation between Cystic Pituitary Adenomas and Rathke Cleft Cysts: A Diagnostic Model Using MRI. *AJNR Am J Neuroradiol*, 10; 2015: 1866-73.
15. **Rao, GP., Blyth, CP., Jeffreys, RV.:**

- Ophthalmic manifestations of Rathke's cleft cysts. *Am J Ophthalmol*, 119; 1995: 86–91.
16. **Reddy, MP., Jiacheng, S., Xunning, H. et al.:** Intracranial epidermoid cyst: characteristics, appearance, diagnosis, treatment and prognosis. *Sci Lett*, 3; 2015: 102–110.
  17. **Shin, JL., Asa, SL., Woodhouse, LJ. et al.:** Cystic lesions of the pituitary: clinicopathological features distinguishing craniopharyngioma, Rathke's cleft cyst, and arachnoid cyst. *J Clin Endocrinol Metab*, 84; 1999: 3972–82.
  18. **Trifanescu, R., Ansorge, O., Wass, JA. et al.:** Rathke's cleft cysts. *Clin Endocrinol (Oxf)*, 76; 2012: 151–60.
  19. **Vivek, A., Deepak, P., Vernon, V. et al.:** Unusual site of Rathke's cleft cyst: A case report and review of literature. *Asian J Neurosurgery*, 1; 2017: 44–46.
  20. **Voelker, JL., Campbell, RL., Muller, J.:** Clinical, radiographic, and pathological features of symptomatic Rathke's cleft cysts. *J Neurosurg*, 74; 1991: 535–44.
  21. **Wenig, BM.:** Oral cavity, nasopharynx, oropharynx, and neck. In Wenig (2nd ed.): *Atlas of head and neck pathology*. Philadelphia, Saunders Elsevier, 2008, s. 186.