

TREATMENT OF KERATOCONUS BY ACCELERATED CROSS-LINKING

SUMMARY

This study evaluates the efficacy of treatment of progressive keratoconus using Accelerated Corneal Collagen cross-linking (ACXL) method. Patients underwent ACXL at the Dept. of Ophthalmology of University Hospital in Hradec Králové between 2012 - 2013. Uncorrected distance visual acuity, best corrected distance visual acuity, keratometry (K1, K2, Kmax), corneal astigmatism and corneal pachymetry were measured preoperatively and in 6 months, 1 year, 2 and 3 years after the surgery. The results were statistically analysed by non-parametric Wilcoxon test. There were found statistically significant changes in K2 values and values of corneal thickness postoperatively.

Key words: keratoconus, ectasia, accelerated corneal cross-linking

Čes. a slov. Oftal., 73, 2017, No. 4, p. 134–139

Veliká V., Rozsival P., Jirásková N., Raiskup F.

Department of Ophthalmology, Faculty of Medicine, Charles University and University Hospital Hradec Králové, Chief prof. MUDr. Naďa Jirásková, Ph.D., FEBO

The authors of the study declare that no conflict of interest exists in the compilation, theme and subsequent publication of this professional communication, and that it is not supported by any pharmaceuticals company.



MUDr. Věra Veliká
Oční klinika LFUK a FN
500 05 Hradec Králové,
e-mail: vera.velika@fnhk.cz

INTRODUCTION

Keratoconus is the most common form of ectatic pathology of the cornea. It is manifested by progressive thinning and conical bulging of the cornea. This process leads to a reduction of visual acuity, caused by the occurrence of irregular astigmatism, and in the advanced stage by scarring of the cornea (4). The etiopathogenesis of keratoconus is multifactorial. Current research on the level of molecular genetics presents a whole range of evidence concerning the influence of genetic factors on the development of this pathology (5, 15).

CXL is a type of photodynamic therapy, in which new chemical bonds are generated between collagen fibres of the anterior stroma of the cornea, enabling a reinforcement of the cornea and a restoration of its biochemical and biomechanical stability (23). To date it is the "standard method" (Dresden protocol), which is generally recognised with regard to the number of published studies demonstrating efficacy and safety also in long-term observation (14). The Dresden protocol incorporates the following procedure. Following removal of the corneal epithelium, 0.1% riboflavin solution is used as a photosensibilisator, which is applied to the cornea every 2 minutes over a period of 30 minutes. A surface with a diameter of 8.00 mm in the central section of the cornea is then irradiated with UVA radiation with a wavelength of 370 nm and an intensity of 3 mW/cm² for a period of 30 minutes. The endeavour to improve the conventional procedure of CXL was generated by the idea of the possibility of reducing the duration of the procedure whilst preserving the same total energy of radiation as in conventional therapy and improving the comfort of the patient during the course of the procedure (12).

One of the examined methods is accelerated CXL (ACXL). The Bunsen-Roscoe law of photochemical reciprocity dictates

that the same photochemical effect can be attained by preserving constant total energy with a lower irradiation interval while applying a higher intensity of radiation. Commercially available instruments therefore achieve accelerated cross-linking within a few minutes by increasing the UVA energy and reducing the time of exposure, whilst preserving the same total energy. This study engages in an evaluation of the results of therapy of progressive keratoconus with the aid of the method of accelerated cross-linking.

STUDY COHORT

The study cohort comprised 24 eyes of 21 patients who underwent ACXL at the Department of Ophthalmology at the University Hospital in Hradec Králové in the period of 2012-2013. The patients consisted of 13 men and 8 women. The average age was 33 years (18-47 years). The preoperative data was compared with the results obtained 6 months, 1, 2 and 3 years after the performance of the surgical procedure.

Upon entry an examination was performed which incorporated the following: recording of anamnesis, examination of uncorrected and best corrected distance and near visual acuity, measurement of intraocular pressure (non-contact tonometer NIDEK NT-530), refraction test (automatic refractometer, NIDEK AR 310A), biomicroscopy, corneal topography and pachymetry (Pentacam, Oculus, Inc.). We indicated patients who met the following indication criterion of progression of keratoconus for the CXL procedure: increase of value of maximum keratometry (Kmax) in the apex of keratoconus by 1D and more per year. The cohort contained 6 patients with a preoperative corneal thickness of 400-450 µm including the epithelium. We used hypotonic riboflavin solution for saturation of the cornea on these patients.

The exclusion criteria were as follows: scarring of the

central part of cornea, pachymetry less than 400 μm including epithelium, age <15 years and >50 years, ocular herpetic infection or infection of herpes virus in anamnesis, diabetes mellitus and pregnancy. A condition for selection of patients was consistent attendance of regular examinations following the CXL procedure.

Observed parameters:

UCVA – uncorrected visual acuity.

BCVA – best corrected visual acuity.

Corneal astigmatism.

K1 – average keratometry of anterior surface of cornea in flattest meridian (sagittal display).

K2 – average keratometry of anterior surface of cornea in steepest meridian (sagittal display).

Kmax – value of curvature of anterior surface of cornea in apex of keratoconus (sagittal display).

Pachymetry (thinnest point of cornea).

Course of procedure, postoperative care

The procedure was performed in outpatient care under sterile conditions in the operating theatre. Thirty minutes before the procedure, patients were administered painkilling and sedative drugs. Following the application of local anaesthesia (Benoxi 0.4 gtt, Unimed Pharma, Slovakia) we fitted an eyelid speculum and performed manual abrasion of the corneal epithelium with a diameter of 9.0 mm. As a photosensibilisator we used 0.1% riboflavin solution, which we applied to the cornea every 2 minutes over a period of 30 minutes (MEDIO CROSS® isotonic 3.0 ml: the standard solution for CXL, Avedro Inc., USA). In the case of corneal thickness of 400-450 μm including epithelium we applied hypotonic riboflavin solution (MEDIO CROSS® hypotonic 3.0 ml, Avedro Inc., USA).

A surface with a diameter of 8.0 mm in the central part of the cornea was subsequently irradiated with UVA radiation with a wavelength of 370 nm and an intensity of 9mW/cm² (instrument UV-X 2000, AccuTech Medical Technologies Inc., Canada). The course of irradiation of the cornea saturated with riboflavin with UVA radiation is illustrated by fig. 1. During the ten minute irradiation we further applied riboflavin in the form of drops every 5 minutes (according to the recommendation of the manufacturer) to the cornea. The patient fixed the central light diode of the probe. During the course

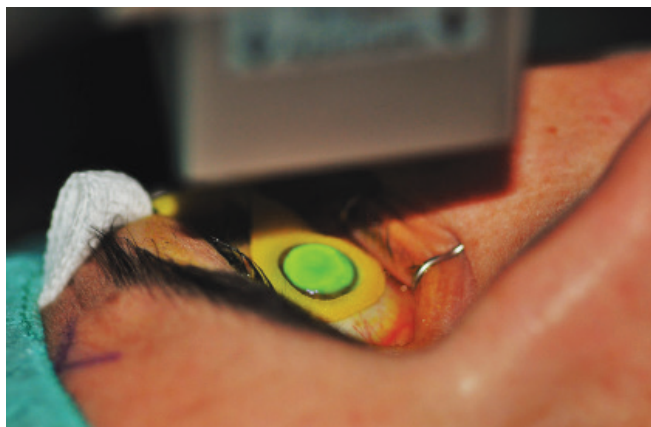


Fig. 1 Course of irradiation of cornea saturated with riboflavin

of the procedure the patient was under continuous control of centration of the illuminating beam of the radiation.

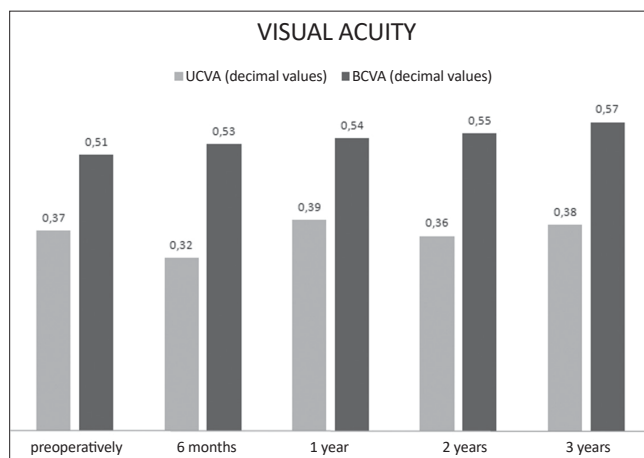
Postoperatively the patient received antibiotics in the form of drops (Gentamicin 0.3% gtt, Polfa), with administration of the application into the conjunctival sac every 2 hours with the exception of sleeping hours, for a total of 5 days, and epithelizantium (Solcoseryl gel) 5x per day. The eye was covered with a bandage for a period of 4 days. We instructed the patient with regard to postoperative pain and postoperative irritation. The first follow-up examination was conducted on the 4th day after surgery. After re-epithelisation of the cornea, most often on the 6th postoperative day, we applied corticoids locally (Flucon gtt, Alcon, Novartis company), with a frequency of application 4x per day for a period of 3 weeks. We conducted a further follow-up examination 1 month after surgery. In the case of satisfactory healing without signs of the occurrence of scarring, we instructed the patient with regard to the further procedure of treatment, which consisted in the application of corticoids 3x per day for 2 weeks, 2x per day for 2 weeks and 1x per day for 2 weeks into the conjunctival sac. A further follow-up examination was set at 3 months, 6 months, 1 year and each further year after surgery. The observed parameters were evaluated 6, 12, 24 and 36 months after the surgical procedure.

Statistical processing

For statistical processing we used a non-parametric Wilcoxon test, since the analysed quantities are not subject to normal distribution. Evaluation of statistical significance was evaluated on a level of significance of 0.05.

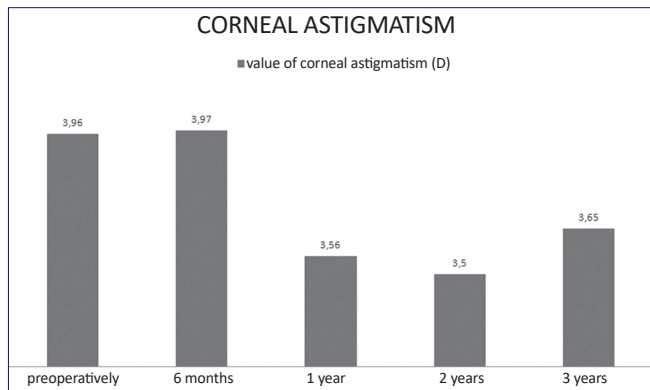
RESULTS

Before surgery average UCVA was 0.37 ± 0.31 (decimal values), 6 months after surgery there was a slight, insignificant deterioration to the value of 0.32 ± 0.28 . At the end of the

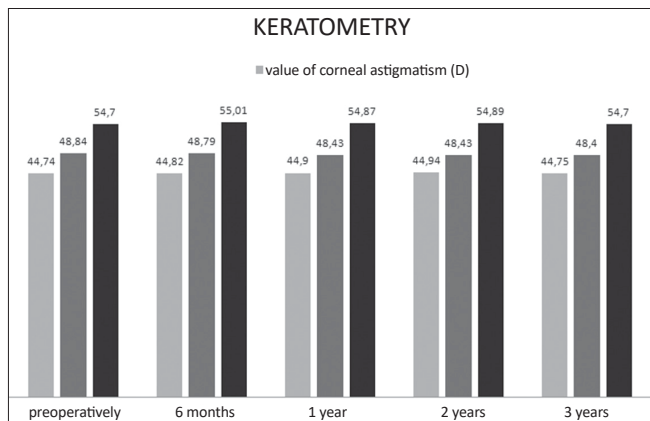


Graph 1 Development of uncorrected and best corrected visual acuity during the course of observation

key: UCVA: uncorrected visual acuity, BCVA: best corrected visual acuity



Graph 2 Average values of corneal astigmatism

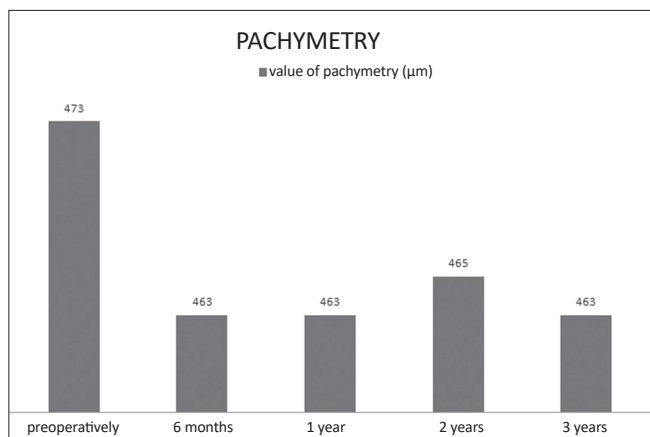


Graph 3 Average values of keratometry during the course of observation
key: K1 – average keratometry of anterior surface of cornea in flattest meridian (sagittal display)

K2 – average keratometry of anterior surface of cornea in steepest meridian (sagittal display)

Kmax – value of curvature of anterior surface of cornea in apex of keratometry (sagittal display)

period of monitoring the UCVA value improved in comparison to the pre-operative value to 0.38 ± 0.3 . This change of values was not statistically significant. Average UCVA (glasses correction) was preoperatively 0.51 ± 0.27 ; 3 years after surgery the average BCVA value had improved to 0.57 ± 0.26 . However, the change of this value was not statistically significant. At the



Graph 4 Average values of pachymetry during the course of observation

end of the observation period there was thus no statistically significant change of uncorrected or best corrected visual acuity in comparison with the preoperative value, as illustrated in graph 1.

Corneal astigmatism declined from the average preoperative value of 3.96 ± 2.38 D to a value of 3.65 ± 1.64 D at the end of the observation period. The reduction in the value however was not statistically significant. The development of the values of corneal astigmatism over time is illustrated in graph 2.

The average values of curvature in the place of the flattest and steepest meridian before surgery were as follows: K1: 44.74 ± 3.82 D; K2: 48.84 ± 3.98 D. 3 years after surgery the parameters reached the following values: K1: 44.75 ± 3.26 D; K2: 48.40 ± 3.80 D. At the end of the observation period we recorded a statistically significant reduction of the K2 value in comparison with the preoperative value. The average preoperative value of maximum corneal curvature was $K_{max}: 54.70 \pm 5.45$ D; after surgery it reached values of $K_{max}: 54.70 \pm 5.53$ D. During the course of observation there was no statistically significant change of the K_{max} value at the apex of keratocornus. The development of the keratometric values of the cornea during the course of observation is illustrated in graph 3.

The average value of pachymetry at the thinnest point on the cornea was 473.3 ± 30.95 μm preoperatively. 3 years after surgery corneal thickness was statistically significantly reduced to an average value of 463.3 ± 31.46 μm. The values of corneal thickness are illustrated in graph 4.

DISCUSSION

The results of studies of treatment of progressive keratoconus using the CXL method indicate that not only a stabilisation of keratectasia is achieved, but there is even an improvement of keratometric parameters and visual acuity (16, 26). The most extensive published series on this theme is covered by the work of the Dresden authors. This retrospective study observed 241 eyes in 130 patients with a diagnosis of keratoconus over a period of up to 6 years following the performance of standard CXL. The study confirmed a statistically significant improvement of best corrected visual acuity, astigmatism and maximum value of corneal curvature K_{max} (17).

Experimental studies using animal and human corneas demonstrate a comparable increase in corneal robustness following standard and accelerated CXL (2, 22). However, at the same time publications are available which demonstrate a reduction of the biomechanical effect upon the use of accelerated CXL in comparison with the standard protocol. CXL is a photo-oxidative reaction, requiring oxygen during the formation of covalent bonds. The insufficient effect of accelerated CXL is explained here with reference to the insufficient quantity of oxygen caused by the insufficient intrastromal diffusion capacity of oxygen, the increased consumption of oxygen upon the higher intensity, shorter duration of radiation and the thus reduced concentration of oxygen radicals (7, 18).

However, in connection with the above observations speculations may arise relating to the results of experimental studies on enucleated animal eyes, which therefore cannot be fully compared with the results obtained in vivo on patients

with keratoconus. Similarly, the course of the photochemical reaction may be different in a normal cornea and in a cornea with keratectasis (28).

The fundamental demonstrable effects of CXL include an increase of the biomechanical robustness of the cornea, increased rigidity and biomechanical stability of the cornea, increase in resistance to hydration, increase in the diameter of collagen lamellas, increase in the module of flexibility over time, increase in resistance to enzymatic degradation, reduction of permeability of the cornea and antimicrobial effects (11, 15, 24, 25, 29, 30, 31). In recent years studies have therefore appeared which describe the effect and results of ACXL in clinical practice. Among the main observed parameters are visual acuity, keratometric values, keratometric indexes, biomechanical properties and corneal thickness, depth of demarcation line, density of keratocytes of anterior corneal stroma, occurrence of haze and number of endothelial cells.

During the course of our observation no statistically significant change occurred in either uncorrected or best corrected visual acuity in comparison with the preoperative value. An improvement or stabilisation of BCVA took place after three years of observation in 79.2% of eyes. Corneal astigmatism was reduced from an average preoperative value of 3.96 ± 2.38 D to a value of 3.65 ± 1.64 D at the end of the observation period. However, the reduction of the value was not statistically significant.

In five eyes there was a deterioration of BCVA, in which mild corneal scarring occurred in three eyes, and in two eyes we recorded a progression in the Kmax value. The eyes in which we recorded an occurrence of corneal scarring after surgery had a preoperative value of corneal thickness in the thinnest point less than or equal to 460 μ m. In two eyes we used a hypotonic solution for corneal saturation due to the thin cornea. The preoperative value of maximum corneal curvature in these two eyes was 61 D and 48.8 D respectively. In both cases there was an improvement of this parameter to values of 60 D and 48.3 D respectively. A pronounced progression of the Kmax value occurred in one case, in which the value of maximum corneal curvature in the apex of keratoconus was 58.4 D at the end of the observation period, as against a preoperative value of 52 D. Corneal thickness in the apex of keratoconus was 494 μ m preoperatively, and as a result isotonic riboflavin solution was used for saturation of the cornea during the operation. This pronounced change in corneal curvature meant a reduction of best corrected visual acuity from 0.2 to 0.15 (decimal values), without subjective perception of deteriorated vision on the part of the patient. The condition can be explained on the basis of the fact that the apex of keratoconus was not localised in the axis of vision, and therefore the change of curvature in this point did not have a significant influence on the change of postoperative visual acuity.

The study conducted by Sadoughi et al. also failed to demonstrate any statistically significant changes in values of visual acuity (UCVA, BCVA) 1 year after the performance of the surgical procedure. This study compares the conventional method of CXL (3 mW/cm², radiation time 30 minutes) with accelerated CXL (9 mW/cm², radiation time 10 minutes) (20). Elbaz et al. observed 16 eyes of 14 patients who had under-

gone accelerated CXL (9 mW/cm², radiation time 10 minutes) one year after surgery. At the end of the observation period uncorrected visual acuity showed a slight improvement, best corrected visual acuity and keratometric values were stable (6). Kanellopoulos determined a different result, namely a significant improvement of visual acuity in four-year observation. He recorded an improvement of VA, BCVA, astigmatism and the Kmax value was reduced from 49.5 D to 46.1 D. The author used accelerated CXL (7 mW/cm², radiation time 15 minutes) with the use of removal of the epithelium using the PTK technique (phototherapeutic keratectomy) (9). The excellent effect of treatment attained can be explained on the basis of simultaneous removal of the Bowman's membrane during corneal de-epithelisation, and therefore by the occurrence of a polymerisation reaction also in the deeper layers of the stroma.

The aim of the CXL procedure is to prevent further progression of keratoconus and to stabilise ectasia. The primary aim of the method is not reduction of refraction of the eye. In the case of planned change of refraction in keratoconus, there are a number of ways by which to combine the CXL technique with correction of refraction of the eye (10, 19, 21).

Another assessed parameter was keratometric values, which attest to a change in corneal curvature after the performance of the procedure. At the end of the observation period we recorded a statistically significant reduction of the K2 value in comparison with the preoperative value. During the course of observation there was no statistically significant change of the K1 or Kmax values. An evaluation of the keratometric values in our cohort demonstrated stabilisation of keratoconus following the performance of accelerated CXL in three-year observation.

Demonstration of the stabilising effect of accelerated and standard CXL within short-term observation is presented by a range of studies. The study by the authors Ng et al. demonstrated a statistically significant improvement of Kmax and BCVA values in a cohort treated by the ACXL method (9 mW/cm², radiation time 10 minutes) and the standard method (3 mW/cm², radiation time 30 minutes) (13). The demarcation line was, however, located deeper in eyes following the performance of CXL using the standard technique. A deeper demarcation line means more new covalent bonds at a greater depth of the cornea, greater volume of the cross-linked corneal stroma and thus also its greater flattening.

A group of Japanese authors also compared the effect of treatment of progressive keratoconus using the method of accelerated CXL (15 minutes of saturation / 3 minutes of radiation 30 mW/cm²) with standard CXL (30 minutes of saturation / 30 minutes of radiation 3 mW/cm²). No statistically significant differences were found postoperatively in changes of uncorrected and best corrected visual acuity and in manifest refractive spherical equivalent in both groups. In keratometric values also, no statistically significant differences were recorded postoperatively (27).

Another large comparative study by the authors Hashemi-an et al. compared changes of morphological parameters and visual acuity in both methods. An interesting finding was a significant reduction of the density of keratocytes of the anterior corneal stroma and subbasal nerve plexus in both groups one

month after surgery. During the course of the observation, the authors demonstrated a significantly greater reduction of these parameters in the group with standard CXL. At the end of the observation period, however, there was no longer any significant difference in these parameters in both groups (8), but these morphological changes may be the cause of a change of corneal curvature and pachymetric values after surgery.

The average pachymetric value in the thinnest point of the cornea was statistically significantly lower at the end of the observation period in comparison with the preoperative value. Analogous results are also confirmed by the professional literature (28). The pachymetric values are a reflection of changes in the corneal stroma on an extracellular and cellular level. Thinning of the cornea following the procedure is accompanied by excessive apoptosis of keratocytes of the corneal stroma up to a depth of 270–390 μm . Cell death of keratocytes is most pronounced in the anterior corneal stroma. Cells beneath this “demarcation line” are not in any way damaged by radiation. Repopulation begins six weeks after CXL and is completed six months after CXL. However, the preoperative quantity of keratocytes does not appear even two years after surgery.

CXL is a technically simple and relatively safe procedure. However, abrasion of the epithelium may cause pronounced pain and deterioration of vision during the first few days after surgery, up to the time when the epithelium is completely restored. In connection with removal of the epithelium, infectious complications have been described in the literature such as bacterial keratitis, herpes simplex infection or acanthamoebous infection of the cornea. In our cohort we did not record any in-

fectious complications. The CXL method also involves the risk of the occurrence of haze, sterile infiltrates and the occurrence of central stromal scarring. High intensity of UVA radiation may damage the subbasal nerve plexus, and as a consequence impair the regulation of the sodium-potassium endothelial pump (1). A loss of density and hexagonality of the endothelial cells was also demonstrated following accelerated CXL (18 mW/cm², radiation time 5 minutes), the greatest changes were recorded on the 7th day after surgery, with return to the original values after 6 months (3). We did not record any serious postoperative complication in patients in the observed cohort. The main role in this was played by strict adherence to the entrance criteria, the therapeutic protocol and postoperative care. Thorough education of the patient is equally important.

CONCLUSION

The results of the study confirm that accelerated CXL, in addition to standard CXL, represents another alternative for the treatment of keratoconus, also in the case of less co-operative patients, leading to stabilisation of corneal ectasia and to stabilisation or even improvement of the keratometric values of the cornea. This technique has a low incidence of complications and adverse side effects, and improves the time comfort of the patient during the course of the procedure. In patients following accelerated corneal cross-linking, it shall be necessary to conduct long-term observation of the aforementioned parameters also with regard to the less deep demarcation line and the attendant effect of the procedure as confirmed by certain studies.

LITERATURE

1. Arita R., Arita M., Kawai M., et al.: Evaluation of corneal endothelial pump function with a cold stress test. *Cornea*, 2005 Jul; 24(5): 571–5.
2. Beshtawi IM., Akhtar R., Hillarby MC., et al.: Biomechanical properties of human corneas following low- and high-intensity collagen cross-linking determined with scanning acoustic microscopy. *Invest Ophthalmol Vis Sci*, 2013 Aug 7; 54(8): 5273–80.
3. Cingü AK., Sogutlu-Sari E., Cinar Y., et al.: Transient corneal endothelial changes following accelerated collagen cross-linking for the treatment of progressive keratoconus. *Cutan Ocul Toxicol*, 2014 Jun; 33(2): 127–31.
4. Davidson AE., Hayes S., Hardcastle AJ., et al.: The pathogenesis of keratoconus. *Eye (Lond)*, 2014 Feb; 28(2): 189–95.
5. Edwards M., McGhee CN., Dean S.: The genetics of keratoconus. *Clin Experiment Ophthalmol*, 2001 Dec; 29(6): 345–51.
6. Elbaz U., Shen C., Lichtinger A., et al.: Accelerated (9-mW/cm²) corneal collagen crosslinking for keratoconus –A 1-year follow-up. *Cornea*, 2014 Aug; 33(8): 769–73.
7. Hammer A., Richoz O., Arba Mosquera S., et al.: Corneal biomechanical properties at different corneal cross-linking (CXL) irradiances. *Invest Ophthalmol Vis Sci*, 2014 May 2; 55(5): 2881–4.
8. Hashemian H., Jabbarvand M., Khodaparast M., et al.: Evaluation of corneal changes after conventional versus accelerated corneal cross-linking: a randomized controlled trial. *J Refract Surg*, 2014 Dec; 30(12): 837–42.
9. Kanellopoulos AJ.: Long term results of a prospective randomized bilateral eye comparison trial of higher fluence, shorter duration ultraviolet A radiation, and riboflavin collagen cross linking for progressive keratoconus. *Clin Ophthalmol*, 2012; 6: 97–101.
10. Kanellopoulos AJ., Asimellis G.: Keratoconus management: long-term stability of topography-guided normalization combined with high-fluence CXL stabilization (the Athens Protocol). *J Refract Surg*, 2014 Feb; 30(2): 88–93.
11. Martins SA., Combs JC., Noguera G., et al.: Antimicrobial efficacy of riboflavin/UVA combination (365 nm) in vitro for bacterial and fungal isolates: a potential new treatment for infectious keratitis. *Invest Ophthalmol Vis Sci*, 2008 Aug; 49(8): 3402–8.
12. Meek KM., Hayes S.: Corneal cross-linking—a review. *Ophthalmic Physiol Opt*, 2013 Mar; 33(2): 78–93.
13. Ng AL., Chan TC., Cheng AC.: Conventional versus accelerated corneal collagen cross-linking in the treatment of keratoconus. *Clin Exp Ophthalmol*, 2016 Jan–Feb; 44(1): 8–14.
14. O’Brart DPS., Chan E., Samaras K., et al.: A randomised, prospective study to investigate the efficacy of riboflavin/ultraviolet A (370 nm) corneal collagen cross-linkage to halt the progression of keratoconus. *Br J Ophthalmol*, 2011; 95(11): 1519–1524.
15. Rabinovitz YS.: Keratokonus. *Surv. Ophthalmol*, 1998 Jan–Feb; 42(4): 297–319.
16. Raiskup F., Theuring A., Pillunat LE., et al.: Corneal collagen crosslinking with riboflavin and ultraviolet-A light in progressive keratoconus: ten-year results. *J Cataract Refract Surg*, 2015 Jan; 41(1): 41–6.

17. **Raiskup-Wolf F., Hoyer A., Spoerl E. et al.:** Collagen crosslinking with riboflavin and ultraviolet-A light in keratoconus: long-term results. *J Cataract Refract Surg*, 2008; 34(5): 796–801.
18. **Richoz O., Hammer A., Tabibian D., et al.:** The Biomechanical Effect of Corneal Collagen Cross-Linking (CXL) With Riboflavin and UV-A is Oxygen Dependent. *Transl Vis Sci Technol*, 2013 Nov; 2(7): 6.
19. **Rozsival, P. et al.:** Trendy soudobé oftalmologie, svazek 7, Praha, Galen, 2011: 50.
20. **Sadoughi MM., Einollahi B., Baradaran-Rafii A., et al.:** Accelerated versus conventional corneal collagen cross-linking in patients with keratoconus: an inpatient comparative study. *Int Ophthalmol*, 2016 Dec 29.
21. **Sakla H., Altroudi W., Munoz G., et al.:** Simultaneous Topography-Guided Photorefractive Keratectomy and Accelerated Corneal Collagen Cross-Linking for Keratoconus. *Cornea*, 2016 Jul; 35(7): 941–5.
22. **Schumacher S., Oeftiger L., Mrochen M.:** Equivalence of biomechanical changes induced by rapid and standard corneal cross-linking, using riboflavin and ultraviolet radiation. *Invest Ophthalmol Vis Sci*, 2011 Nov 25; 52(12): 9048–52.
23. **Spoerl E., Huhle M., Seiler T.:** Induction of cross-links in corneal tissue. *Exp Eye Res*, 1998 Jan; 66(1): 97–103.
24. **Spoerl E., Wollensak G., Seiler T.:** Increased resistance of crosslinked cornea against enzymatic digestion. *Curr Eye Res*, 2004 Jul; 29(1): 35–40.
25. **Stewart JM., Lee OT., Wong FF., et al.:** Cross-linking with ultraviolet-a and riboflavin reduces corneal permeability. *Invest Ophthalmol Vis Sci*, 2011 Nov 29; 52(12): 9275–8.
26. **Strmeňová E., Vlková E., Michalcová L., et al.:** Corneal cross-linking v liečbe keratokónusu – výsledky a komplikácie v dvojročnom sledovaní. *Čes a Slov Oftal*, 71; 2015: 158–168.
27. **Tomita M., Mita M., Huseynova T.:** Accelerated versus conventional corneal collagen crosslinking. *J Cataract Refract Surg*, 2014 Jun; 40(6): 1013–20.
28. **Waszczykowska A., Jurowski P.:** Two-year accelerated corneal cross-linking outcome in patients with progressive keratoconus. *Biomed Res Int*, 2015; 2015: 325.
29. **Wollensak G., Aurich H., Pham DT., et al.:** Hydration behaviour of porcine cornea crosslinked with riboflavin and ultraviolet A. *J Cataract Refract Surg*, 2007 Mar; 33(3): 516–21.
30. **Wollensak G., Spoerl E., Seiler T.:** Stress-strain measurements of human and porcine corneas after riboflavin-ultraviolet-A-induced cross-linking. *J Cataract Refract Surg*, 2003 Sep; 29(9): 1780–5.
31. **Wollensak G., Wilsch M., Spoerl E., et al.:** Collagen fiber diameter in the rabbit cornea after collagen crosslinking by riboflavin/UVA. *Cornea*, 2004 Jul; 23(5): 503–7.