

POSSIBILITIES OF *IN VIVO* CORNEAL CONFOCAL MICROSCOPY OF CORNEAL NERVES IN DIABETES

SUMMARY

In vivo corneal confocal microscopy (CCM) represents a new, non-invasive, rapidly developing corneal examination technique that enables individual layers of the cornea to be displayed at the cellular level. The cornea is the translucent and at the same time the most innervated tissue of the human body. Diabetic neuropathy (DN) is a serious complication of diabetes mellitus (DM). A close correlation has been demonstrated between the development of diabetic neuropathy and the pathological changes of the corneal subbasal plexus. Currently, great attention is directed towards the possibility of using CCM to determine early DN. Interestingly, changes in nerve plexus in the cornea precede the clinical manifestations of DN. Our work aims to give a comprehensive overview of the current possibilities and trends in use of *in vivo* CCM in connection with DN evaluation. *In vivo* CCM becomes important in the search for patients at risk of developing DN, in early diagnosis of DN in pre-symptomatology, in quantifying severe DN, in monitoring and evaluating the therapeutic response to DM treatment. In addition to its diagnostic and preventive significance, it is a research tool important for understanding the pathophysiology of DM changes.

Key words: confocal microscopy, cornea, small fibre neuropathy, diabetes mellitus, diabetic neuropathy

Čes. a slov. Oftal., 73, 2017, No. 4, p. 161–167

INTRODUCTION

Interest is currently increasing in non-invasive methods, enabling the imaging and studying of tissues *in vivo* on a cellular level. In ophthalmology considerable attention is being devoted to possibilities of the use of *in vivo* corneal confocal microscopy (CCM). A study was previously published on the possibilities of this new method of examination by Pirnerová et al. in 2010 (61).

The number of patients with type 1 DM (DM 1) and type 2 DM (DM 2) has increased dramatically worldwide in recent years. Since the beginning of the 21st century there has been talk of an epidemic of DM (78). Diabetic neuropathy (DN) and retinopathy, together with diabetic nephropathy are the most severe microangiopathic complications of DM. The incidence of DN increases with the length of duration of diabetes, in which its prevalence is as much as 50% (16).

In ophthalmology, in patients with diabetes mellitus (DM) together with diabetic retinopathy, considerable attention is currently being focused on changes in the cornea and in other tissues of the ocular surface (37).

Abnormalities of the cornea in patients with DM are referred to using the term diabetic keratopathy, which also covers corneal neuropathy. This is the consequence of a breach of the integrity of the corneal nerve plexus (78, 37). At present we can display the corneal nerve fibres with the aid of *in vivo* CCM. This opens up a space for broad inter-disciplinary co-operation between ophthalmologists, diabetologists and neurologists. Studies to date indicate a very good correlation between a diminution of the nerve fibres of the subbasal nerve plexus of the cornea, evaluated with the aid of CCM, and diabetic neuropathy (DN) determined by currently used clinical and paraclinical examination procedures (34).

The common pathophysiological basis stated in pathophysiological, epidemiological and certain genetic studies indicates a correlation between the incidence of changes on the surface of the eye, diabetic retinopathy (especially more severe degrees) and DN (28). Our study presents a summary overview of the use of CCM for assessing the morphology of corneal nerves and their pathological changes in patients with DM.

Nerve supply of cornea

A range of studies have been devoted to the anatomy of innervation of the human cor-

Česká Burdová M.¹, Lainová Vrabcová T.¹,
Dotřelová D.¹, Mahelková G.^{1,2}

¹Department of Ophthalmology for Children and Adults, 2nd Faculty of Medicine, Charles University and Motol University Hospital

²Institute of Physiology, 2nd Faculty of Medicine, Charles University

Supported by the project (Ministry of Health of the Czech Republic) of conceptual development of research organisation 00064203 and project CZ.2.16/3.1.00/24022.

The authors of the study declare that no conflict of interest exists in the compilation, theme and subsequent publication of this professional communication, and that it is not supported by any pharmaceuticals company.



Marie Česká Burdová
Oční klinika dětí a dospělých 2. LF UK
a FN Motol
V Úvalu 84
150 06 Praha 5
e-mail: marie.ceska-burdova@fnmotol.cz

nea with the aid of a light and electron microscopy, and recently also with the aid of corneal confocal microscopy (3, 2, 41).

The cornea ranks among the tissues with the most abundant innervation in the human body, with approximately 7000 loose epithelial nerve endings per mm². The density of the nerve endings is 300–400 times greater than in the human skin (48). The nerve supply of the cornea is formed by loose terminal endings of sensitive nerve fibres of the nn. ciliares longi (n. ophthalmicus via n. nasociliaris) originating from the n. trigeminus. The nerve fibres branch out radially and pass through the region of the limbus into the cornea, forming stromal nerve fibres. Approximately after 1 mm they lose the perineurium and myelin sheath, at a depth of $293 \pm 106 \mu\text{m}$ from the surface of the cornea they are encased only by the Schwann cells. The stromal peripheral nerves incorporate both myelinated and no longer myelinated nerve bundles. In the centre of the stroma there are only non-myelinated nerve bundles containing axons surrounded by the amorphous extracellular matrix (47). Before passing through the Bowman's membrane, in the space between the Bowman's membrane and the basal epithelial layer, the fibres branch out and create the subbasal nerve plexus. In this the fibres rotate 90 degrees in the direction toward the surface of the cornea, pass through the Bowman's membrane and end as loose subepithelial nerve endings (22, 70). The fibres of the subbasal nerve plexus run in parallel to the surface of the cornea, and as a result they can be very well assessed in their course with the aid of a newly developing imaging method – in vivo CCM (81). The nerve fibres of the subbasal plexus are wound in a clockwise direction from the limbus to the centre of the cornea, and form a whorl structure inferonasally from the centre. This represents the location with the densest network of nerve fibres (55). It is assumed that the inferonasal shift is a consequence of the sliding force of the movement of the eyelid during blinking (15). The cornea is supplied also by autonomous sympathetic nerve fibres, which pass from the superior cervical ganglion (42). It is not clear as to whether the cornea also contains parasympathetic nerve fibres (47). The predominant part of the fibres is formed by heterogeneous sensory fibres from the 1st branch of the n. trigeminus. One of the main functions is to transmit thermal, mechanical and chemical impulses in the form of pain. The sensory nerves have their anatomical and functional organisation. From the perspective of anatomy, some of the nerves run in parallel with the surface of the eye, whereas others rotate perpendicularly to the surface of the cornea. They differ functionally in their chemical composition, electro-physiological properties and according to their response to excitation stimuli (9). According to their myelination and speed of conductivity impulse, the corneal nerves are classified into:

- a) thin myelinated fibres (type A-delta with fast conductivity with an average speed of 6 m/s, conduct sharp, well defined pain),
- b) non-myelinated fibres (type C with slow conductivity with an average speed lower than 2 m/s, conduct diffuse pain) (9). On the basis of impulses which activate the nerve endings, they are divided into:
 - a) mechano-nociceptors (20% of the total number of sensory nerves of cornea, type A-delta, mediate acute sharp pain depending on mechanical contact with cornea),

- b) polymodal nociceptors (70% of all sensory nerves of cornea, mostly type C, conduct sharp and lasting pain as a reaction to mechanical, thermal, exogenous chemical and endogenous inflammatory substances of cornea),
- c) cool receptors (10% of total number of sensory nerve fibres of cornea, combination of type A-delta and C, activated as a reaction to evaporation of lachrymal film, upon contact of surface of cornea with cold solution or cold air, or upon decrease of surface temperature of cornea beneath 33°C) (9).

The size of the reception area changes according to the functional classification of the nerves. Polymodal nociceptors and mechano-nociceptors have a large perception area, whereas the largest number of cool receptors are in the perilimbal region (9).

In vivo corneal confocal microscopy

With the aid of this method it is possible to evaluate changes in the structure of all layers of the cornea on a microscopic level, including the nerve fibres of the subbasal nerve plexus of the cornea (20, 31, 33).

Current methods of determining the peripheral neuropathy include taking an anamnesis and clinical examination of peripheral sensitivity, electrophysiology, invasive biopsy of the nerve fibres, if applicable including genetic examination (28, 59, 76, 81). As against this in vivo CCM provides fast, non-invasive optical cross-sections of the cornea and thereby enables a quantitative analysis of the nerve fibres of the cornea (25, 76). Human corneal nerve fibres are difficult to study ex vivo. They degenerate only 14 hours after death (9). Corneal stromal nerves are more robust and survive longer after death in comparison with subbasal nerves, and as a result are more suitable for in vitro studies of the cornea (67).

With the aid of in vivo CCM, stromal nerves were examined less intensively than the nerve fibres of the subbasal plexus. The results of studies which focused on a quantification of the stromal nerves (50) were ambiguous due to the adverse sloping course for scanning, and due to their sparse incidence (26). The subbasal nerve plexus can be very well identified and evaluated with the aid of in vivo CCM due to its course in parallel with the surface of the cornea, which is recorded precisely in the frontal plane (50). Several types of corneal confocal microscopes have been used for the study of changes of the nerve fibres of the subbasal plexus of the cornea over the course of the last two decades. The used types of instruments have different technical parameters and use various types of scanning beams. As a consequence of the technical possibilities of the used instruments, the resulting values of the observed parameters of nerve fibres differ. Upon a comparison of individual measurements it is therefore necessary to take into account the type of microscope. Only values from one type of microscope are mutually comparable.

Evaluation of scans

An entire obtained scan is evaluated (76), or with regard to the reducing quality of images in the peripheral sections it is possible to evaluate only the central part of the image, which is captured in good quality (8).

For a comparison of the results of studies, it is essential to have a precise definition of terms in assessment of the parameters of the scanned subbasal plexus of the cornea. The most precisely assessable, precisely definable and comparable are considered to be the number and length of the fibres of the subbasal nerve plexus (25). Further assessed parameters are the number of secondary branches (branchings) of nerve fibres or the number of points of crossing. The most difficult to define is tortuosity of the fibres. A precise definition of the evaluated parameters is developed progressively. At present the majority of studies defined the density of the subbasal nerve fibres as the total number of main nerves per unit of surface (CNFD, number/mm²) (1, 18, 30, 44, 39, 77). However, some older studies stated the number of nerves per image (45) or also the total length of nerves per image (mm/image) (19, 21) under this term, which may be confusing upon a comparison of results. Sometimes the number of all identified nerve fibres, main nerve trunks and branches (t-CNFD, number/mm² or number/image) is stated. Similarly, density of nerve branches (branchings) was defined as the total number of nerve branches per unit of surface (CBFD, number/mm²) (76). The total length of nerve fibres is defined as the length of all identified nerve fibres per unit of surface (CNFL, mm/mm², or mm/image) (76). The lack of uniformity in the methodology is even more pronounced upon the determination of tortuosity. In older studies, tortuosity was evaluated subjectively on a scale of 1-4 (13, 44). Some other studies introduced automated or semi-automated evaluation of tortuosity with the assistance of individually produced software, but the results are ambiguous (23, 53, 54). Another possibility was evaluation of tortuosity according to the method which was used upon assessment of the tortuosity of fine arteries in cardiology (CNFT, dimensionless number, proportion of absolute length of identified nerve fibre to length of join of extreme points of the evaluated fibre) (8, 24). Upon damage to the fibres of the subbasal nerve plexus, there is a reduction of the value CNFD, t-CNFD, CBFD and CNFL, whereas by contrast the tortuosity of the CNFT of the fibres increases. Messmer et al. point to the fact that upon a concurrent diminution of nerve fibres (decrease of CNFD and CNFL), an increase in tortuosity need not be demonstrated (44). A new parameter which can be identified by in vivo CCM following multiple enlarging of the image is the "beady" character of the nerve fibre (32).

There is a predominant lack of uniformity with regard to the minimum number of images necessary for a representative quantitative analysis (8, 69, 80).

Diabetic neuropathy

Diabetes mellitus is a pathology with increasing global significance. The pathology affects a number of organ systems. Microangiopathic complications occur under a picture of diabetic nephropathy, retinopathy and neuropathy. The aforementioned complications, not infrequently resulting in kidney failure, blindness or amputation of a limb, lead to a reduction in quality of life and an increasing burden on healthcare and the social security system worldwide.

The endeavour to detect these complications in a timely manner and prevent their further progression is leading to

a constant search for new, appropriate screening methods, which would be capable of detecting these complications in their earliest stage. As a result, considerable attention is being focused on the possible relationship between the detriment of corneal nerve fibres and a more precise classification of DN. Among the most frequent forms of DN is sensorimotor neuropathy (17).

In 1977 a correlation was described between neurotrophic ulcers of the cornea and diabetes mellitus (29). Subsequently a reduction of the density of corneal nerves was demonstrated ex vivo in experimentally induced diabetes in rats (82).

In the year 2000 Rosenberg et al. described a correlation between changes in the subbasal nerve plexus of the cornea and reduced sensitivity of the cornea with use of non-contact aesthesiometry in patients with DN (65). Since that time, further studies have demonstrated the possibility of quantifying changes of the subbasal nerve plexus of the cornea more precisely (35, 39, 44, 45, 65, 70, 75, 77). Regular methods used for determining DN have limited sensitivity for its detection in the early stage (4, 46, 64). Potentially objective, more sensitive and precise bioptic methods are not usable in common practice due to their invasiveness.

Studies have demonstrated that patients with DM 1 or DM 2 manifest a pronounced reduction in the number of subbasal nerves of the cornea in comparison with healthy subjects (56, 76, 81). An abundant corneal nerve plexus in a healthy individual is shown in fig. 1. A pronounced diminution of the nerve plexus in a patient with DM 1 is shown in fig. 2. The CNFD value of the cornea correlates with the clinically and electro-physiologically assessed degree of DN (59, 64, 77). The reduction in the number of subbasal nerves is linked with symptoms of peripheral neuropathy and a reduction of the number of intraepidermal nerves (64, 77). In vivo CCM demonstrated and quantified early damage to small nerve fibres (27, 39, 77) with good sensitivity and specificity (77). Mild neuropathy had already been detected (18). The length of the corneal nerve fibres in particular has high sensitivity (91%) and specificity (93%) for identification of diabetic sensorimotor polyneuropathy (1, 25). In the studies it was verified that changes of the subbasal nerve plexus of the cornea precede other clinical or electro-physiological manifestations of DN (27, 36, 46, 63). It is interesting that a reduction in the number of nerve fibres of the subbasal nerve plexus also precedes clinical symptoms of diabetic retinopathy and microalbuminuria (8, 59). Up to 50% of patients with DM, who had no clinical symptoms of DN, already had abnormal changes of the subbasal nerve plexus. Reduced values of CNFL were demonstrated not only in individuals with an increased value of glycated haemoglobin, but also with glucose tolerance disorder. The early onset of degeneration of corneal nerve fibres in the case of glucose tolerance disorder and new identification of DM 2 (4, 5, 83) support the hypothesis that the pathophysiology of diabetic neuropathy begins very soon after the onset of the pathology (4, 5, 7, 52, 59, 64). In two longitudinal studies it was confirmed that a decrease in the length of corneal nerve fibres (CNFL) precedes the onset of clinical manifestations of DN in subjects with DM 1. Diabetic polyneuropathy (or




Fig. 1 Nerve fibres of the subbasal nerve plexus in a healthy subject

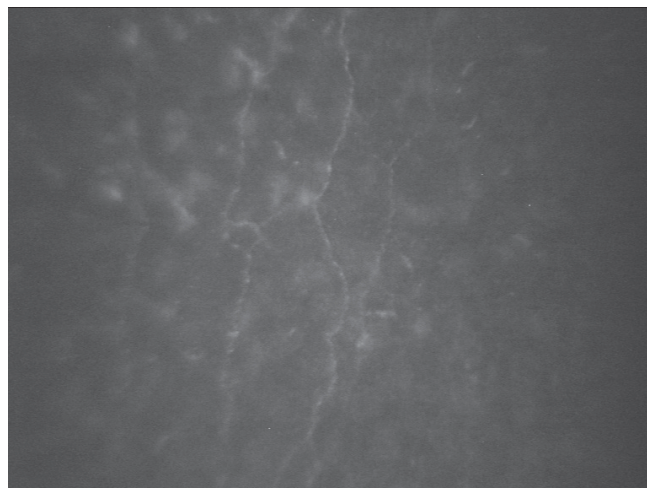


Fig. 2 Nerve fibres of the subbasal nerve plexus in a patient with type 1 diabetes mellitus

sensorimotor neuropathy) was manifested in these subjects within 3.5-4 years (36, 63). A longitudinal study conducted by Dehghani et al. was focused on risk factors in subjects with changes of the subbasal nerve plexus without the presence of DN. After four years of observation, the study demonstrated a detriment of fibres of the subbasal nerve plexus in dependency on clinical and metabolic factors such as age, level of glycated haemoglobin and disorder of the lipid metabolism (14). Change of the nerve plexus were also described in children with type 1 DM (66).

Hyperglycaemia induced development of a beady character of the nerve fibres of the cornea was newly assessed. It is assumed that it is caused by accumulated mitochondria, glycogen particles and vesicles. The growth of a coral character of the corneal nerve fibre was demonstrated in a group without DN and increased with the increasing degree of DN. There was a positive correlation with a decrease in values of CNFD and CNFL (32).

Tavakoli et al. (71) demonstrated a reduction in the number, length and branching of nerve fibres with the aid of CCM also in a group with demonstrated diabetic autonomous neuropathy (DAN) in comparison with DM without DAN and a control group of healthy subjects. The changes correlated with the degree of DAN with high sensitivity and specificity. In vivo CCM could therefore also become a non-invasive marker of DAN. However, it is still necessary to verify these results (38, 46).

With the aid of in vivo CCM, regeneration of corneal nerve fibres was also demonstrated in patients with DM 1 following transplantation of the pancreas, combined transplantation of kidneys and pancreas (43, 49, 74), following conversion to continual subcutaneous infusion of insulin (6) and after improvement of the basic risk factors leading to DN (primarily the level of glycated haemoglobin, cholesterol and blood pressure) (73).

As mentioned previously, the degeneration of fibres of the subbasal nerve plexus of the cornea precedes also other vascular microangiopathic complications of DM, diabetic retinopathy or nephropathy (4, 5, 7, 8, 59, 64, 83). To date no study devoted to the use of in vivo CCM for forecasting the subsequent development of diabetic retinopathy and

nephropathy has been published.

Current drawbacks and limitations of in vivo CCM

Upon observation of corneal nerve fibres, images from the central region of the cornea are commonly used. The highest number of nerve fibres in the cornea are in fact inferonasally from the centre of the cornea. However, the reduction of the total length of nerve fibres in the area of the inferonasal whorl was comparable with the reduction of CNFL in the central region of the cornea (60) in patients with peripheral DN. Despite the fact that the image was more specific for peripheral diabetic neuropathy in the region of the whorl (62, 79), imaging of the central section of the cornea did not bring about a reduction of the usability of in vivo CCM as a diagnostic test (60).

Some authors point to possible limitations of the assessment of the relatively short nerves of the avascular cornea for using observation of damage to long somatic nerves (40). However, it has been demonstrated that changes to the subbasal nerve plexus of the cornea correlate very well with a decrease in the number of intraepidermal nerve fibres assessed from bioptic samples (64) and through measurement of functional changes of nerve fibres in DN (68).

Furthermore, in animal models with DN a reduction of blood through flow in the posterior ciliary artery has been demonstrated, together with a simultaneous decrease in the number of fibres determined with the aid of in vivo CCM. A subsequent improvement of blood through flow following administration of a vasoepitidase inhibitor leading to vasodilation led to a renewal of the corneal nerve plexus (11, 12).

The evaluation of changes to the corneal nerve fibres may further be complicated by the demonstrated physiological decrease in the number and length of nerve fibres with age, and the influence of sex can also not be excluded. For this reason there is an endeavour to create a normative database which would take these changes of values into account (35, 72). Uncertainty persists with regard to racial differences. A further drawback is the evaluation of images itself, which requires experience, as well as time consuming ma-

nual assessment of the image. As a result, at present a large amount of attention is being focused on the development of automatic image analysis for quick quantification of corneal changes (56, 57), which would demonstrate a high correlation with manual assessment, in particular the number and length of nerve fibres (10, 51, 58). Standardisation of image analysis of *in vivo* CCM using centralised reading centres could be of fundamental significance in future (56).

In vivo CCM appears to be an ideal non-invasive clinical technique for assessing changes in the cellular pathology of the cornea. From the perspective of diabetology, interest is

focused primarily on the subbasal nerve plexus in connection with the quantification of changes of small nerve fibres. With the development of automated image analysis and verification of normative databases, it is probable that there will be a rapid increase in the clinical usability of *in vivo* CCM in the assessment of not only DN.

The aim shall be to seek out patients with a risk of developing DN, identify minimal DN, quantify severe DN and observe the course or assess the therapeutic response to treatment. *In vivo* CCM may thus in future represent a significant tool not only in research, but also in prevention and diagnosis.

LITERATURE

1. Ahmed, A., Bril, V., Orszag, A., et al: Detection of diabetic sensorimotor polyneuropathy by corneal confocal microscopy in type 1 diabetes: a concurrent validity study. *Diabetes Care*, 35(4); 2012: 821–828.
2. Al-Aqaba, M.A., Alomar, T., Miri, A. et al.: Ex vivo confocal microscopy of human corneal nerves. *Br J Ophthalmol*, 94; 2010: 1251–7.
3. Al-Aqaba, M.A., Fares, U., Suleman, H. et al.: Architecture and distribution of human corneal nerves. *Br J Ophthalmol*, 94; 2009: 784–9.
4. Asghar, O., Petropoulos, I.N., Alam, U. et al.: Corneal confocal microscopy detects neuropathy in subjects with impaired glucose tolerance. *Diabetes Care*, 37; 2014: 2643–2646.
5. Azmi, S., Ferdousi, M., Petropoulos, I.N. et al: Corneal Confocal Microscopy Identifies Small-Fiber Neuropathy in Subjects with Impaired Glucose Tolerance Who Develop Type 2 Diabetes. *Diabetes Care*, 38; 2015: 1502–1508.
6. Azmi, S., Ferdousi, M., Petropoulos, I.N. et al: Corneal confocal microscopy shows an improvement in small-fiber neuropathy in subjects with type 1 diabetes on continuous subcutaneous insulin infusion compared with multiple daily injection. *Diabetes Care*, 38; 2015: e3–e4.
7. Bitirgen, G., Ozkagnici, A., Malik, R.A. et al.: Corneal nerve fibre damage precedes diabetic retinopathy in patients with Type 2 diabetes mellitus. *Diabetic Medicine*, 31(4); 2014: 431–438.
8. Burdová M.Č., Vrabcová, T.L., Dotřelová, D. et al: Diabetická retinopatie a změny nervových vláken hodnocené konfokální mikroskopií rohovky. *Česk Slov Neurol N*, 80/113(1); 2017: 59–65.
9. Cruzat, A., Qazi, Y., Hamrah, P.: *In vivo* confocal microscopy of corneal nerves in health and disease. *The Ocular Surface*, 15(1); 2017: 15–47.
10. Dabbah, M.A., Graham, J., Petropoulos, I.N. et al: Automatic analysis of diabetic peripheral neuropathy using multi-scale quantitative morphology of nerve fibres in corneal confocal microscopy imaging. *Med Image Anal*, 15(5); 2011: 738–747.
11. Davidson, E.P., Coppey, L.J., Holmes, A. et al: Changes in corneal innervation and sensitivity and acetylcholine-mediated vascular relaxation of the posterior ciliary artery in a type 2 diabetic rat. *Invest Ophthalmol Vis Sci*, 53(3); 2012: 1182–1187.
12. Davidson, E.P., Coppey, L.J., Yorek, M.A.: Early loss of innervation of cornea epithelium in streptozotocin-induced type 1 diabetic rats: improvement with ilepatril treatment. *Invest Ophthalmol Vis Sci*, 53(13); 2012: 8067–8074.
13. De Cilla, S., Ranno, S., Carini, E. et al.: Corneal subbasal nerves changes in patients with diabetic retinopathy: an *in vivo* confocal study. *Invest Ophthalmol Vis Sci*, 50; 2009: 5155–5158.
14. Dehghani, C., Pritchard, N., Edwards, K. et al.: Risk Factors Associated With Corneal Nerve Alteration in Type 1 Diabetes in the Absence of Neuropathy: A Longitudinal *In vivo* Corneal Confocal Microscopy Study. *Cornea*, 35; 2016: 847–852.
15. Doane, M.G.: Interactions of eyelids and tears in corneal wetting and the dynamics of the normal human eyeblink. *Am J Ophthalmol*, 89; 1980: 507–16.
16. Dyck, P.J., Kratz, K.M., Karnes, J.L. et al.: The prevalence by staged severity of various types of diabetic neuropathy, retinopathy, and nephropathy in a population-based cohort: the Rochester Diabetic Neuropathy Study. *Neurology*, 43; 1993: 817–824.
17. Dyck, P.J., Overland, C.J., Low, P.A. et al.: Signs and symptoms versus nerve conduction studies to diagnose diabetic sensorimotor polyneuropathy: CI vs. NPhys trial. *Muscle and Nerve*, 42(2); 2010: 157–164.
18. Edwards, K., Pritchard, N., Vagenas, D. et al: Utility of corneal confocal microscopy for assessing mild diabetic neuropathy: baseline findings of the LANDMark study. *Clin Exp Optom*, 95(3); 2012: 348–354.
19. Erie, J.C., McLaren, J.W., Hodge, D.O. et al: The effect of age on the corneal subbasal nerve plexus. *Cornea*, 24(6); 2005: 705–709.
20. Erie, J.C., McLaren, J.W., Patel, S.V.: Confocal microscopy in ophthalmology. *Am J Ophthalmol*, 148; 2009: 639–646.
21. Grupcheva, C.N., Wong, T., Riley, A.F., McGhee, C.N. et al: Assessing the sub-basal nerve plexus of the living healthy human cornea by *in vivo* confocal microscopy. *Clin Experiment Ophthalmol*, 30(3); 2002: 187–190.
22. Guthoff, R.F., Wienss, H., Hahnel, C. et al.: Epithelial innervation of human cornea: a three-dimensional study using confocal laser scanning fluorescence microscopy. *Cornea*, 24; 2005: 608–613.
23. Guthoff, R.F., Zhivov, A., Stachs, O.: *In vivo* confocal microscopy, an inner vision of the cornea – a major review. *Clin Experiment Ophthalmol*, 37; 2009: 100–117.
24. Heneghan, C., Flynn, J., O’Keefe, M. et al.: Characterization of changes in blood vessel width and tortuosity in retinopathy of prematurity using image analysis. *Med Image Anal*, 6; 2002: 407–429.
25. Hertz, P., Bril, V., Orszag, A. et al.: Reproducibility of *in vivo* corneal confocal microscopy as a novel screening test for early diabetic sensorimotor polyneuropathy. *Diabetic Medicine*, 28(10); 2011: 1253–1260.
26. Hoşal, B.M., Ornek, N., Zilelioğlu, G. et al: Morphology of corneal nerves and corneal sensation in dry eye: a preliminary study. *Eye (Lond)*, 19(12); 2005: 1276–1279.
27. Hossain, P., Sachdev, A., Malik, R.A. et al: Early detection of diabetic peripheral

- ral neuropathy with corneal confocal microscopy. *Lancet*, 366(9494); 2005: 1340–1343.
28. **Hosseini, S.M., Boright, A.P., Sun, L. et al.:** The association of previously reported polymorphisms for microvascular complications in a meta-analysis of diabetic retinopathy. *Hum Genet*, 134; 2015: 247–257.
 29. **Hyndiuk, R.A., Kazarian, E.L., Schultz, R.O. et al.:** Neurotrophic corneal ulcers in diabetes mellitus. *Arch Ophthalmol*, 95(12); 1977: 2193–2196.
 30. **Chang, P.Y., Carrel, H., Huang, J.S. et al.:** Decreased density of corneal basal epithelium and subbasal corneal nerve bundle changes in patients with diabetic retinopathy. *Am J Ophthalmol*, 142(3); 2006: 488–490.
 31. **Chiou, A.G.Y., Kaufman, S.C., Kaufman, H.E., et al.:** Clinical corneal confocal microscopy. *J. Survophthal*, 51; 2006: 482–500.
 32. **Ishibashi, F., Kojima, R., Taniguchi, M. et al.:** The Expanded Bead Size of Corneal C-Nerve Fibers Visualized by Corneal Confocal Microscopy Is Associated with Slow Conduction Velocity of the Peripheral Nerves in Patients with Type 2 Diabetes Mellitus. *Journal of Diabetes Research*, 2016; 2016: 3653459.
 33. **Jalbert, I., Stapleton, F., Papas, E. et al.:** *In vivo* confocal microscopy of the human cornea. *Br J Ophthalmol*, 87; 2003: 225–236.
 34. **Jiang, M.S., Yuan, Y., Gu, Z.X. et al.:** Corneal confocal microscopy for assessment of diabetic peripheral neuropathy: a meta-analysis. *Br J Ophthalmol*, 100; 2015: 9–14.
 35. **Kovalová, I., Horáková, M., Vlčková, E. et al.:** Hodnocení rohovkové inervace pomocí konfokální mikroskopie. *Česk Slov Neurol N*, 80/113(1); 2017: 49–57.
 36. **Lovblom, L.E., Halpern, E.M., Wu, T. et al.:** *In vivo* corneal confocal microscopy and prediction of future incident neuropathy in type 1 diabetes: a preliminary longitudinal analysis. *Can J Diabetes*, 39; 2015: 390–397.
 37. **Lutty, G.A.:** Effects of diabetes on the eye. *Invest Ophthalmol Vis Sci*, 54; 2013: 81–87.
 38. **Zochodne, D.W.:** Diabetes mellitus and the peripheral nervous system: manifestations and mechanisms. *Muscle Nerve*, 36; 2007: 144–166.
 39. **Maddaloni, E., Sabatino, F., Del Toro, R. et al.:** *In vivo* corneal confocal microscopy as a novel non-invasive tool to investigate cardiac autonomic neuropathy in Type 1 diabetes. *Diabet Med*, 32(2); 2015: 262–6.
 40. **Malik, R.A., Kallinikos, P., Abbott, C.A. et al.:** Corneal confocal microscopy: a non-invasive surrogate of nerve fibre damage and repair in diabetic patients. *Diabetologia*, 46(5); 2003: 683–688.
 41. **Malik, R.A., Newrick, P.G., Sharma, A.K. et al.:** Microangiopathy in human diabetic neuropathy: relationship between capillary abnormalities and the severity of neuropathy. *Diabetologia*, 32(2); 1989: 92–102.
 42. **Marfurt, C.F., Cox, J., Deek, S. et al.:** Anatomy of the human corneal innervation. *Exp Eye Res*, 90; 2010: 478–92.
 43. **Marfurt, C.F., Kingsley, R.E., Echtenkamp, S.E.:** Sensory and sympathetic innervation of the mammalian cornea. A retrograde tracing study. *Invest Ophthalmol Vis Sci*, 30; 1989: 461–72.
 44. **Mehra, S., Tavakoli, M., Kallinikos, P.A. et al.:** Corneal confocal microscopy detects early nerve regeneration after pancreas transplantation in patients with type 1 diabetes. *Diabetes Care*, 30; 2007: 2608–2612.
 45. **Messmer, E.M., Schmid-Tannwald, C., Zapp, D. et al.:** *In vivo* confocal microscopy of corneal small fiber damage in diabetes mellitus. *Graefes Arch Clin Exp Ophthalmol*, 248; 2010: 1307–1312.
 46. **Midena, E., Brugin, E., Ghirlando, A. et al.:** Corneal diabetic neuropathy: a confocal microscopy study. *J Refract Surg*, 22(9 Suppl); 2006: 1047–1052.
 47. **Misra, S.L., Craig, J.P., Patel, D.V. et al.:** *In vivo* Confocal Microscopy of Corneal Nerves: An Ocular Biomarker for Peripheral and Cardiac Autonomic Neuropathy in Type 1 Diabetes Mellitus. *Invest Ophthalmol Vis Sci*, 56; 2015: 5060–5065.
 48. **Muller, L.J., Marfurt, C.F., Kruse, F. et al.:** Corneal nerves: structure, contents and function. *Exp Eye Res*, 76; 2003: 521–42.
 49. **Muller L.J., Vrensen, G.F., Pels, L. et al.:** Architecture of human corneal nerves. *Invest Ophthalmol Vis Sci*, 8; 1997: 985–994.
 50. **Navarro, X., Sutherland, D.E.R., Kennedy, W.R.:** Long-term effects of pancreatic transplantation on diabetic neuropathy. *Annals of Neurology*, 42(5); 1997: 727–736.
 51. **Oliveira-Soto, L., Efron, N.:** Morphology of corneal nerves using confocal microscopy. *Cornea*, 20; 2001: 374–384.
 52. **Ostrovski, I., Lovblom, L.E., Farooqi, M.A. et al.:** Reproducibility of *In vivo* Corneal Confocal Microscopy Using an Automated Analysis Program for Detection of Diabetic Sensorimotor Polyneuropathy. *PLoS One*, 10; 2015: e0142309.
 53. **Papanas, N., Vinik, A.I., Ziegler, D. et al.:** Neuropathy in prediabetes: does the clock start ticking early? *Nat Rev Endocrinol*, 7; 2011: 682–690.
 54. **Papanas, N., Ziegler, D.:** Corneal confocal microscopy: Recent progress in the evaluation of diabetic neuropathy. *J Diabetes Investig*, 6; 2015: 381–389.
 55. **Patel, D.V., McGhee, C.N.:** *In vivo* confocal microscopy of human corneal nerves in health, in ocular and systemic disease, and following corneal surgery: a review. *Br J Ophthalmol*, 93; 2009: 853–860.
 56. **Patel, D.V., McGhee, C.N.:** *In vivo* laser scanning confocal microscopy confirms that the human corneal sub-basal nerve plexus is a highly dynamic structure. *Invest Ophthalmol Vis Sci*, 49; 2008: 3409–12.
 57. **Patel, D.V., McGhee, C.N.:** Quantitative analysis of *in vivo* confocal microscopy images: a review. *Surv Ophthalmol*, 58; 2013: 466–75.
 58. **Petroll, W.M., Weaver, M., Vaidya, S. et al.:** Quantitative 3-dimensional corneal imaging *in vivo* using a modified HRT-RCM confocal microscope. *Cornea*, 32(4); 2013: e36–e43.
 59. **Petropoulos, I.N., Alam, U., Fadavi, H. et al.:** Rapid automated diagnosis of diabetic peripheral neuropathy with *in vivo* corneal confocal microscopy. *Invest Ophthalmol Vis Sci*, 55; 2014: 2071–2078.
 60. **Petropoulos, I.N., Green, P., Chan, A.W. et al.:** Corneal confocal microscopy detects neuropathy in patients with type 1 diabetes without retinopathy or microalbuminuria. *PLoS One*, 10; 2015: e0123517.
 61. **Petropoulos, I.N., Ferdousi, M., Marshall, A. et al.:** The inferior whorl for detecting diabetic peripheral neuropathy using corneal confocal microscopy. *Invest Ophthalmol Vis Sci*, 56; 2015: 2498–504.
 62. **Pirnerová, L., Horáčková, M., Vlčková, E. et al.:** Využití konfokální mikroskopie rohovky v klinické praxi. *Čes a Slov Oftal*, 66 (6); 2010: 239–247.
 63. **Pritchard, N., Dehghani, C., Edwards, K. et al.:** Utility of assessing nerve morphology in central cornea versus whorl area for diagnosing diabetic peripheral neuropathy. *Cornea*, 34; 2015: 756–61.
 64. **Pritchard, N., Edwards, K., Russell, A.W. et al.:** Corneal confocal microscopy predicts 4-year incident peripheral neuropathy in type 1 diabetes. *Diabetes Care*, 38; 2015: 671–675.
 65. **Quattrini, C., Tavakoli, M., Jeziorska, M. et al.:** Surrogate markers of small fiber damage in human diabetic neuropathy. *Diabetes*, 56(8); 2007: 2148–2154.
 66. **Rosenberg, M.E., Tervo, T.M., Immo-**

- nen, I.J. et al: Corneal structure and sensitivity in type 1 diabetes mellitus. *Invest Ophthalmol Vis Sci*, 41(10); 2000: 2915–2921.
66. Sellers, E.A., Clark, I., Tavakoli, M. et al: The acceptability and feasibility of corneal confocal microscopy to detect early diabetic neuropathy in children: a pilot study. *Diabet Med*, 30(5); 2013: 630–631.
 67. SimoMannion, L., Tromans, C., O'Donnell, C. et al: An evaluation of corneal nerve morphology and function in moderate keratoconus. *Cont Lens Anterior Eye*, 2005; 28(4); 2005: 185–192.
 68. Sivaskandarajah, G.A., Halpern, E.M., Lovblom, L.E. et al: Structure-function relationship between corneal nerves and conventional small-fiber tests in type 1 diabetes. *Diabetes Care*, 36(9); 2013: 2748–55.
 69. Smith, A.G., Kim, G., Porzio, M. et al.: Corneal confocal microscopy is efficient, well-tolerated, and reproducible. *J Peripher Nerv Syst*, 18; 2013: 54–58.
 70. Stachs, O., Zhivov, A., Kraak, R. et al.: *In vivo* three-dimensional confocal laser scanning microscopy of the epithelial nerve structure in the human cornea. *Graefes Arch Clin Exp Ophthalmol*, 245; 2007: 569–575.
 71. Tavakoli, M., Begum, P., McLaughlin, J. et al: Corneal confocal microscopy for the diagnosis of diabetic autonomic neuropathy. *Muscle Nerve*, 52(3); 2015: 363–70.
 72. Tavakoli, M., Ferdousi, M., Petropoulos, I.N. et al.: Normative values for corneal nerve morphology assessed using corneal confocal microscopy: a multinational normative data set. *Diabetes Care*, 38; 2015: 838–843.
 73. Tavakoli, M., Kallinikos, P., Iqbal, A, et al: Corneal confocal microscopy detects improvement in corneal nerve morphology with an improvement in risk factors for diabetic neuropathy. *Diabet Med*, 28; 2011: 1261–1267.
 74. Tavakoli, M., Mitu-Pretorian, M., Petropoulos, I.N. et al.: Corneal confocal microscopy detects early nerve regeneration in diabetic neuropathy after simultaneous pancreas and kidney transplantation. *Diabetes*, 62; 2013: 254–260.
 75. Tavakoli, M., Petropoulos, I.N., Malik, R.A. et al: Assessing corneal nerve structure and function in diabetic neuropathy. *Clin Exp Optom*, 95(3): 2012: 338–347.
 76. Tavakoli, M., Petropoulos, I.N., Malik, R.A.: Corneal Confocal Microscopy to Assess Diabetic Neuropathy: An Eye on the Foot. *Journal of Diabetes Science and Technology*, 7(5); 2013: 1179–1189.
 77. Tavakoli, M., Quattrini, C., Abbott, C. et al: Corneal confocal microscopy: a novel noninvasive test to diagnose and stratify the severity of human diabetic neuropathy. *Diabetes Care*, 33(8); 2010: 1792–1797.
 78. Threatt, J., Williamson, J.F., Huynh, K. et al.: Ocular disease, knowledge and technology applications in patients with diabetes. *Am J Med Sci*, 345; 2013: 266–270.
 79. Utsunomiya, T., Nagaoka, T., Hanada, K. et al.: Imaging of the Corneal Subbasal Whorl-like Nerve Plexus: More Accurate Depiction of the Extent of Corneal Nerve Damage in Patients with Diabetes. *Invest Ophthalmol Vis Sci*, 56; 2015: 5417–5423.
 80. Vagenas, D., Pritchard, N., Edwards, K. et al: Optimal image sample size for corneal nerve morphometry. *Optom Vis Sci*, 89(5); 2012: 812–817.
 81. Wang, B.E.F., Misra, S.L., Patel, D.V. et al.: *In vivo* Confocal Microscopy of the Human Cornea in the Assessment of Peripheral Neuropathy and Systemic Diseases. *BioMed Research International*, 2015; 2015: 951081.
 82. Yamada, J., Dana, M.R., Sotozono, C. et al.: Kinoshita S. Local suppression of IL-1 by receptor antagonist in the rat model of corneal alkali injury. *Exp Eye Res*, 76(2); 2003: 161–167.
 83. Ziegler, D., Papanas, N., Zhivov, A. et al.: Early detection of nerve fiber loss by corneal confocal microscopy and skin biopsy in recently diagnosed type 2 diabetes. *Diabetes*, 63; 2014: 2454–2463.