

# BROWN'S SYNDROME: THE INDIVIDUAL FORMS AND THEIR TREATMENT (INCLUDING EXPANDER OF OWN CONSTRUCTION)

## SUMMARY

**Aim:** Familiar with the treatment of various forms of Brown's syndrome and its success. To document preparation of the expander own design.

**Material and methods:** In the years 1996–2016 was operated 33 patients with congenital Brown's syndrome by using an extension of its tendon expander at the Eye Clinic of the University Hospital Vinohrady in Prague. Author proves photographs preparing expander own design and modified surgical technique. It was also operated on 10 patients for accompanying Y-exotropia. Eleven patients with acute form of Brown's syndrome in the pulley of upper oblique muscle applied Betamethasoni.

**Results:** The using expander own design – non-resorbable Ethibond 5–0 cauted silicone cannula – held at congenital form of Brown's syndrome, without a weighty complication or its exclusion in the period. The result of the performance was determined age of patients at the time of implantation of the expander. Preschoolers postoperative condition was fully compliant, this expander standardized vertical motility. The vertical alignment motility is reduced with advancing age, especially in adulthood. Optimal surgical procedures at Y-exotropia were antepozice with recession of the inferior oblique muscle possibly supplemented by retro-position ipsilateral external rectus. The application efficiency of Betamethasoni for acute form of Brown's syndrome in the pulley of upper oblique muscle was successful in only two weeks after the initial symptoms vertical diplopia.

**Conclusion:** Expander own design which represented non-resorbable Ethibond cauted silicone cannula was very effective in dealing with congenital form of Brown's syndrome.

The application of glucocorticoids in the pulley of upper oblique muscle should always be a quantity result.

**Key words:** Brown's syndrome, Betamethasoni, expander, Ethibond, silicone cannula, Y – exotropia

*Čes. a slov. Oftal., 73, 2017, No. 4, p. 146–154*

## INTRODUCTION

This distinctive cyclovertical motility defect was first described in 1950 by professor H.W. Brown as a syndrome of the tendon casing of the superior oblique muscle. This was followed by a long search for an optimal surgical solution. The issue of Brown's syndrome became an integral component of basic monographs and textbooks in the Czech-Slovak region, within the scope of basic didactic information. An analysis of this syndrome was included in two chapters on strabismus in the 6th volume of "Trends of Contemporary Ophthalmology". At meetings of ophthalmologists engaged in the problem of strabismus and paediatric ophthalmology in the period of 2006 to 2016 a total of seven studies were presented on this theme, and were published in a supplement of *Folia Strabologica et Neuroophthalmologica* (ISSN 1213-1032). To date the only publication on Brown's syndrome published in the basic journal of the Czech and Slovak Ophthalmology Society was an evaluation of initial experiences with operations by professor Gerinec and his collective in 1997 (13). Twenty years later, we decided to return to this theme once again in a detailed study containing individual forms of the pathology, an etiological analysis and therapeutic procedures.

## Clinical picture of individual forms of Brown's syndrome

Brown's syndrome is in most cases a congenital and unilateral, in exceptional cases an acquired defect of vertical motility of the eye, distinguished by restricted or lacking elevation of the eye in adduction (31). This syndrome is above all a sporadically occurring pathology, but autosomally recessive or also dominant heredity has been described (18).

A) Congenital form is explained by the following mechanisms and divided into two groups (37, 60):

a) True Brown's syndrome: truncation of the tendon generates an approach of the stronger muscle part toward the pulley, thus preventing the free extension of the tendon through, and subsequently motility is limited, also the thickening of the tendon has a similar mechanism of blocking in the pulley. The condition is termed non-elastic muscle-tendon complex.

b) Pseudo-Brown's syndrome: congenital abnormal insertion or anomalous placement of the pulley of the superior oblique muscle through its placement truncates the tendon, also congenital inferior insertion of the external rectus muscle through its shifting has a similar effect. Above all, theoretically there is a possibility of innervation abnormality, thus conjunctive supply of both oblique muscles.

Brown's syndrome is characterised by the following (12, 23, 24, 31, 37, 50, 52, 58):

Krásný J.

Department of Ophthalmology, Královské Vinohrady University Hospital, Prague  
Chief prof. MUDr. P. Kuchynka, CSc.

*This publication is dedicated to Professor MUDr. Anton Gerinec, CSc. on the occasion of his seventieth birthday (printed subsequently)*

*The authors of the study declare that no conflict of interest exists in the compilation, theme and subsequent publication of this professional communication, and that it is not supported by any pharmaceuticals company.*



MUDr. Jan Krásný  
Oční klinika FN KV  
Šrobárova 50  
100 34 Praha 10  
e-mail: jan.krasny@fnkv.cz

- a) restriction of vertical motility of the eyeball in adduction
- b) absence of secondary hyperfunctions and contractures
- c) spread of ocular aperture upon adduction
- d) positive traction test of passive duction (except for innervation abnormality)
- e) acute form is accompanied by vertical diplopia, which may be compensated by torticollis
- f) syndrome of "clicking" of the superior oblique muscle, which is manifested by sudden depression of the eye upon its elevation adduction movement, which represents a counter movement of the eyeball.

Indication for surgery of Brown's syndrome is governed by its extent, which is divided into three degrees: the 1st degree represents only limited elevation in adduction, the 2nd degree has depression in adduction in the clinical picture, and the 3rd degree in addition to extensive depression is accompanied by hypotropia in primary position, inclination of the head and eventual esotropia (12), which represents a brief and clear indication breadth. Whereas the 1st degree is not suitable for surgery and the 3rd degree is an absolute indication, the 2nd degree is a relative choice between the two. The necessity of a surgical procedure in the case of the cosmetically unacceptable syndrome of "clicking" of the eye has been noted before the application of an expander (55). Evaluation of the defect of elevation in adduction is divided into four degrees (58): the 1st degree represents elevation in adduction within the scope of 36-50 degrees, the 2nd degree expresses an elevation of 21-35 degrees, the 3rd degree is determined by an elevation of 1-20 degrees and finally the 4th degree is defined as zero elevation, since the afflicted eye in vertical position does not cross the middle line horizontally. It is also referred to as "pseudoparesis" of the inferior oblique muscle (9). This diagnosis appears in the literature (15, 34) also as an indication for an expander to be applied to the superior oblique muscle.

B) Acquired acute form, which is linked to vertical diplopia

and in most cases palpation pain in the upper nasal quadrant of the orbit. It has been described in the following cases: following traumas of the orbit, iatrogenically following surgery in this area or for inflammations of the orbit and adjacent ORL areas, upon vascular affliction of the CNS or in connection with systemic pathologies of the conjunctive tissue (29, 52, 58).

Its clinical picture (fig. 1) is characterised by the position of the head inclined to the other side with lifting of the chin, which is conditional upon the location of the affected eye in abduction and depression for reducing the manifestation of vertical diplopia. Motility defect is classic, in adduction the afflicted eyeball is lower in all height positions and "clicking" syndrome is present. This motility defect has a pathognomonic image on the Hess canvas. The pointed drawing of the enlarged square of the schema in the direction of the function of the superior oblique muscle, with a slight shift inward in the primary picture is accompanied by a secondary rhombus in the other eye, with the largest surface of the schema in the direction of function of the inferior oblique muscle.

Diagnosis of acute Brown's syndrome is difficult due to the etiologically varied palette of causes:

- a) Following trauma of the orbit encroaching upon the area of the pulley (16, 27, 31) or skull (40).
- b) Iatrogenically following surgery in the given orbital region, which represents: e.g. implantation of glaucoma implants (6), external operation for amotio with filling or cerclage strip in the area of the incriminated muscle (37), as well as strabismus (excessive plication of superior oblique muscle) (53) or following endonasal operations (36).
- c) Upon inflammations of the orbit in the region of the superior oblique muscle: myositis alone (30, 41) or in combination with inflammation of the pulley (trochleitis) (47) or tenosynovitis (17), all fitting within the image of inflammatory pseudotumour of the orbit.
- d) Upon inflammatory manifestations of the ORL region: sinusitis (17, 28, 31), mucocele (26).

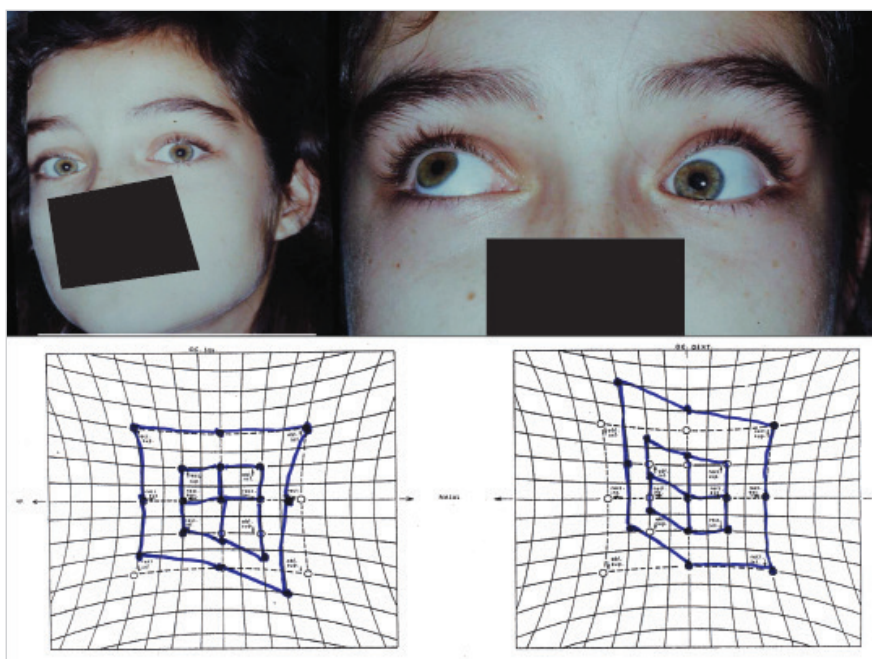


Fig. 1 Acute Brown's syndrome in left eye: Torticollis in right eye with lifting of chin, elevation defect with pronounced depression in adduction in left eye and classic picture on Hess canvas

e) Upon vascular affliction of the CNS within the framework of ocular pareses and pseudopareses (54), as well as other disorders of the CNS: e.g. cranial dysinnervation syndrome (10), as well as the impact of diabetes mellitus on the CNS (54).

f) In children and adults upon systemic pathology of the conjunctival tissue: juvenile idiopathic arthritis (33), psoriasis (46), Sjögren's syndrome and rheumatoid arthritis in adults (58), lupus erythomatosus (37), Wegener's granulomatosis (38).

g) May also be in connection with tumours of the orbit or with masking conditions e.g. osteochondroma (43) or cysticercosis (32).

Brown's syndrome may be accompanied by a particular motility disorder in horizontal position: Y-exotropia (60). In addition to classic defect of elevation in adduction together with the "clicking" syndrome, a slight defect of elevation in abduction is sometimes also associated, and in addition the eye relaxes into exotropia, only in individual elevation gazes. A change may be manifested also in the unaffected eye, since the eye is then secondarily higher, but also externally (fig. 2). Exotropia is not manifested upon direct gaze or in downward gazes, and for this reason is designated as "Y-exotropia". This discrepancy is frequently cosmetically more conspicuous, in the eye without Brown's syndrome, than the actual vertical defect in adduction of the afflicted eye, if it crosses the horizontal line upon elevation.

## MATERIAL AND METHOD

A) We addressed the problem of congenital Brown's syndrome surgically at the Department of Ophthalmology of the Královské Vinohrady University Hospital during the period of 1996 to 2016. The surgical procedures were divided into extension of the tendon of the superior oblique muscle by the insertion of a silicone expander of our own construction, and solution of accompanying Y-exotropia.

Our cohort of patients for a surgical procedure with an expander consisted of 33 patients (of whom 17 children of pre-school age, 10 probands of school age and 6 afflicted in adult age), in which the youngest in the cohort was aged 2 years and the oldest 35 years, the median 10 years. The indication for the use of an expander was hypotropia in primary position within the scope of up to 18 pdpt, on average 8 pdpt in 23 patients, in whom torticollis was also present in 12 cases (slight inclination of head to the other side). In these patients there was an absolute predominance of the 4th degree of restriction of elevation (absolute), in adduction, as against the 3rd degree of elevation defect. A further indication was de-

pression in adduction with 3rd degree restriction of elevation, without symptoms of a defect of vertical hypotropia in primary position. Primarily the opinion of the parents or adult patients decided on how significant a role was played by imbalanced vertical position of the eye from a cosmetic perspective. We always notified the patients and parents that the condition would not deteriorate after surgery, but that we could not always guarantee an outstanding effect in adjusting the position.

The cohort for the surgical solution of "Y-exotropia" comprised a ten-member group of children of school age and adults aged between 12 and 45 years, median 28 years. In six patients it was a supplementary and not a consecutive procedure, as the 2nd phase of a surgical procedure for hypertropia with exotropia in the other eye. A primary surgical procedure (4 patients) for this form of Brown's syndrome was indicated where the elevation defect in adduction was 2nd to 3rd degree of affliction, and exotropia was always present.

### Preparation of expander (fig. 3)

I prepared the expander in the operating theatre under sterile conditions, shortly before each operation. The body of the expander consisted of a hollow silicone cannula with a diameter of 0.7 mm used for operation on the lachrymal ducts with a length of minimum 8 mm. The endeavour was always to produce the longest possible implement. In the maximum case I succeeded in preparing an expander with a length of 11 mm. In the first phase the needle of an Ethibond 5-0 suture thread is inserted into the lumen of the cannula, and its end is forced into the depth with point forceps, the cannula must be rotated and bent in accordance with the curvature of the needle so that the point of the needle spontaneously penetrates as far as possible through the wall of the cannula. The end of the needle is extracted with the aid of a suture holder. In the place of extraction of this needle, the cannula is cut without damaging the thread. In the given phase of preparation, the cannula is interwoven with, for the moment, a single thread. A second thread is drawn analogously in the opposite direction through the lumen of the cannula. Two threads protrude at each end of the cannula, one with the needle and the other without the needle. The individual threads at both ends of this several-millimetre-long cannula form a knot, so that the threads cannot move freely within the lumen. At the same time the knots are concealed within the lumen of the cannula in order to close it. This achieves the transition of the silicone part of the expander into the threads.

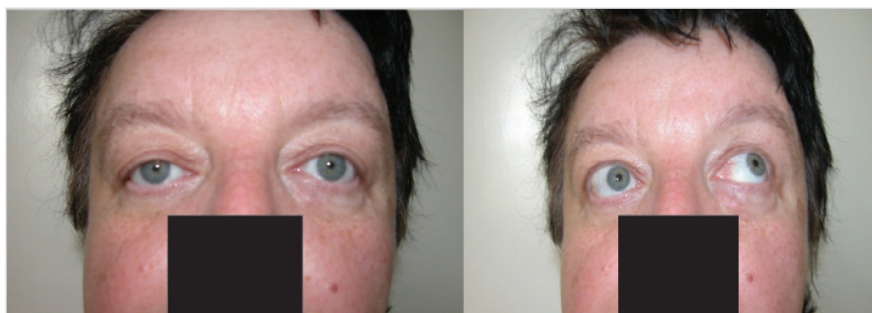

Fig. 2 Y-exotropia: minimal left-sided divergence and sursumvergence in primary position of the eyeball upon fixation of the right eye, upon elevation of both eyeballs elevation defect of right eye in adduction - 3rd degree, confirms diagnosis of Brown's syndrome in right eye

**Actual surgical technique (fig. 4)**

During the actual operation, first of all the tendon of the superior oblique muscle is located and prepared on a muscle hook. The individual ends of the expander are sewn into the tendon along the hook, forming an arch above the tendon. Myostatin is not used in its fitting, thus preventing contusion of the tendon. Subsequently the tendon between both anchorages of the adhering expander is carefully and gradually cut. When the tendon is stretched, the expander is gradually released until it completely opens out, which is demonstrated perioperatively in the extension of the tendon. Through their adherence, the individual ends of the tenotomised tendon of the superior oblique muscle smoothly pass into the ends of the body of the expander, which is sufficiently flexible. It adheres well to the sclera and topographical physiological extension of the tendon is achieved.

B) We identified acute Brown's syndrome in 9 adult patients aged 24 to 58 years (median 42 years) during the period of 1998 to 2014. None of these cases had been preceded by a trauma of the orbit or skull or a local infectious disease. A neurological examination in only three of these, who were all older than 50 years, demonstrated a possible correlation with a stroke. In the other patients the neurological examination was negative, and we did not detect the etiology of the origin of acute Brown's syndrome. No pathological otorhinolaryngological finding was demonstrated in the adjacent cavities, and the patients were not diabetics. The condition had been preceded only by a virus infec-

tion with fever, which was not treated with antibiotics. The condition was accompanied by mild torticollis and diplopia within the extent of primary position, with maximum upon a version of the eyes on the other side than the afflicted eye. In these patients we applied an injection of 1 ml Betamethasone natria phosphas et dipropionas (Diprophos, Scherign-Plough) to the area of the trochlea without anaesthesia. Patients with neurological symptomatology were concurrently treated and observed by a neurologist. We also examined unilateral vertical diplopia with elevation defect of the eyeball upon simultaneous adduction in two girls: aged 8 years (fig. 6) following general viral infection without clear neurological or otorhinolaryngological symptoms, and aged 13 years (fig. 1) upon pansinusitis.

**RESULTS**

Upon the application of 33 expanders of our own construction, we did not record any postoperative complications, any postoperative inflammation or its expulsion. In the postoperative period only a non-inflammatory swelling appeared to various extent in the inner part of the upper eyelid, in exceptional cases affecting the entire upper eyelid. In only two cases the result was cosmetically inconspicuous semiptosis upon normal function of the levator of the eyelid (fig. 5c, d). The most optimal, thus fully compliant results were recorded in 15 pre-school children and four school-age probands (58%), in whom elevation in adduction improved at least to

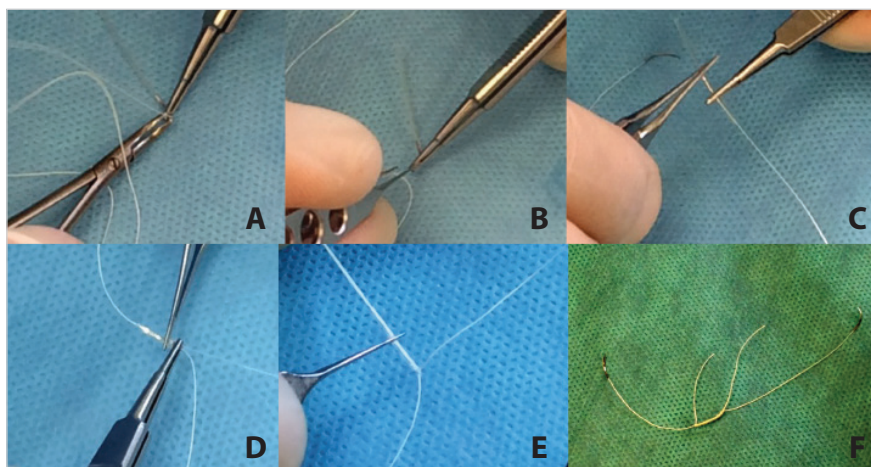


Fig. 3 Preparation of expander (photo Dr. (MUDr.) O. Vláčil): a – initial insertion of needle into lumen of cannula, b – forcing of needle into lumen of cannula, c – initial withdrawal of needle, d – second insertion of needle, e – knotting into lumen of cannula, f – final form of expander

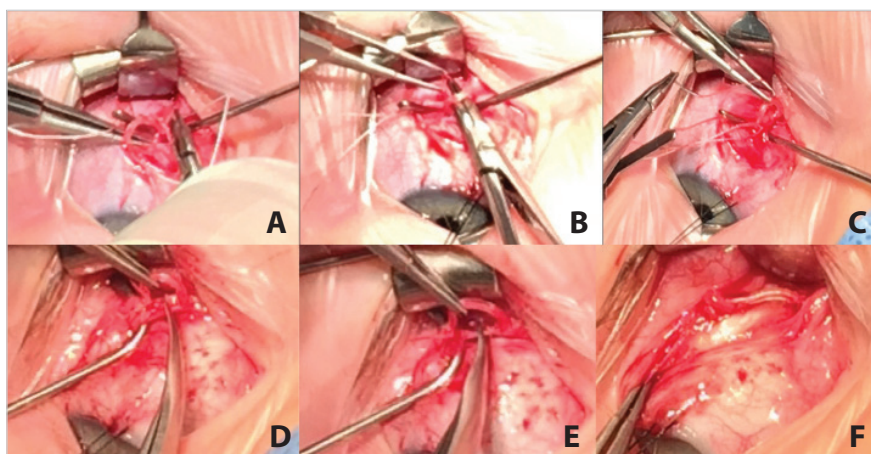


Fig. 4 Actual surgical technique (photo Dr. (MUDr.) L. Lalinská): a – insertion of first suture into tendon of m.o.s., b – tightening of first suture, c – insertion of second suture, d – creation of arch of expander on tendon before its release, e – cutting of tendon opens out expander, f – full spontaneous opening

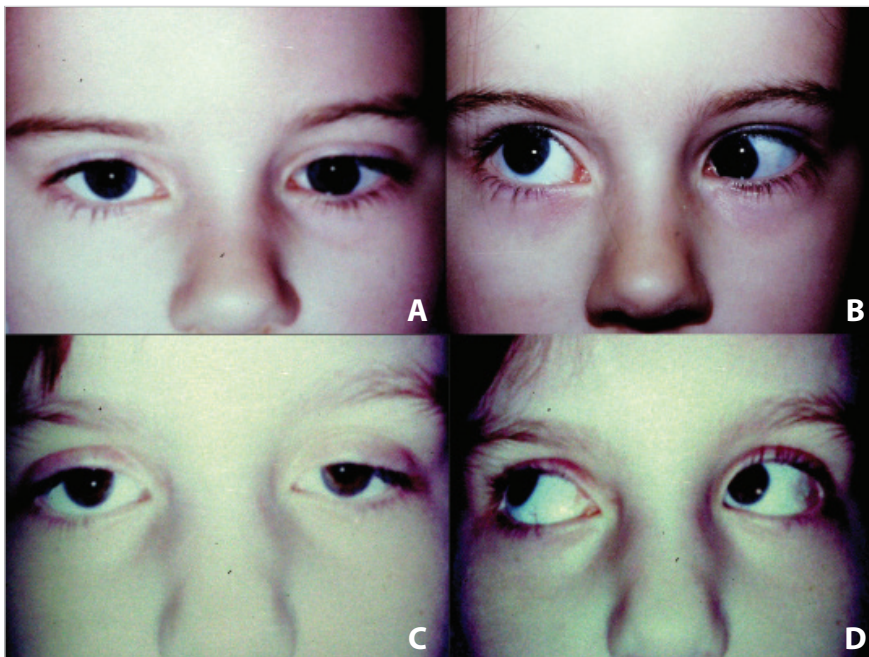


Fig. 5 Treatment with expander: A – primary hypotropia in left eye at age of three years, B - “clicking” syndrome in adduction in left eye before surgery, C – aligned position of eyes at age of five years with consecutive semiptosis in left eye, D – practically aligned elevation in adduction in left eye

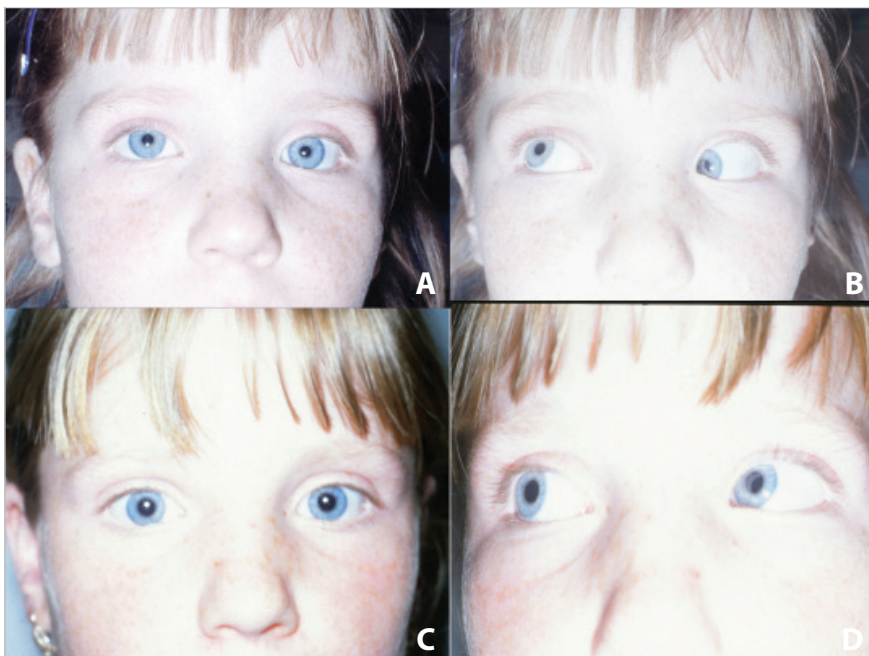


Fig. 6 Treatment with betamethasone. A – acute Brown's syndrome in left eye in fixing eye, secondary hypertropia in right eye, B - “clicking” syndrome of superior oblique muscle in left eye, C – parallel position of eyes after application of pharmaceutical, D – subsequent alignment of motility in adduction in left eye

the 2nd degree and alignment of the vertical deviation also with receding of eventual torticollis. This result was stabilised at the latest within five months after surgery with resulting stereopsis. In the group of 6 school-age and 2 pre-school children, together with 2 adult patients (30%) it is possible to consider the result satisfactory. In these patients, 4th degree elevation defect disappeared, improved to 3rd degree or mostly 2nd degree elevation defect, but stereopsis was not restored unless it was in connection with compensatory torticollis. This receded in the majority of the patients and the vertical deviation was also aligned or decreased maximally to 4 pdpt in primary position. Stabilisation of the results was more short-term, within three months following implantation

of the expander. From the overall point of view it is possible to evaluate the postoperative result as unsatisfactory in 4 adult patients (12%), but the condition was never worse than before surgery. The indication for the procedure was above all the cosmetic reason of function of 3rd degree elevation defect, improvement was maximally to the 2nd degree. Although mild preoperative vertical deviation of up to 6 pdpt was reduced, it did not disappear completely. The regression of alignment of the above-stated defects ceased approximately one month after surgery. The patients themselves considered this change also to be satisfactory.

In conditions of acute Brown's syndrome, motility defect spontaneously corrected itself following anti-inflammatory

treatment of the basic disorder (pansinusitis) in a thirteen-year old girl. On a younger patient with a negative finding on MR in the region of the orbit and CNS we applied once 1 ml of Diprophos (Shering-Plough, France) to the area of the trochlea under general anaesthesia 10 days after the occurrence of diplopia, since a current test for passive duction was positive. This intraorbital corticosteroid therapy brought a permanent and absolutely positive result of correction within a few days (fig. 6). In adult patients the effect of application of Bemethasone to the area of the afflicted pulley was incomplete, with only a slight improvement. Diplopia in primary position mostly regressed, but persisted to varying extents upon alternate side sursumvergence. An optimal effect was achieved only in cases in which the application took place at the latest by the end of the second week following the beginning of the problems.

## DISCUSSION

Since the time of detection of the clinical unit of tendon casing syndrome of the superior oblique muscle by professor Brown in 1950 (4), a search has been under way for an optimal surgical solution. Complete tenotomy alone was only transitionally successful (8), but from a long-term perspective was not demonstrated to be very effective (9), furthermore postoperative pareses of the superior oblique muscle were described (57). Tenectomy was also frequently accompanied by consecutive paralysis of the superior oblique muscle, which out of 12 operated eyes did not appear in only 4, and a new pathological position had to be adjusted primarily by a weakening procedure on the inferior oblique muscle on the same side (52). Further procedures were tenotomy with the aid of a "Z" plastic, which has been used long term upon the weakening of the medial rectus muscle, as well as extension of the tendon by its scission (8). It is precisely this technique upon scission of a length of 10 mm that has returned among surgical techniques of the superior oblique muscle (29). A revolutionary change in the surgical solution of Brown's syndrome was brought about by an expander, enabling anatomical extension of the tendon of the superior oblique muscle, which was introduced by professor K.W. Wright in 1991 (56). This application was first described in four patients with the aid of a silicone amotio cerclage strip (medical grade), in which elevation in adduction improved after surgery, without consecutive paresis of the superior oblique muscle (56). The following year, surgical techniques of tenotomy on 13 patients were compared with the insertion of an expander on 12 patients. In both groups of observed patients, practically the same improvement of vertical deviation was confirmed by 10 pdpt, in 92.3% and 90.9% respectively. A significant difference between both techniques was the absence of postoperative paresis of the superior oblique muscle in all operations with the aid of an expander, whereas after tenotomy this complication appeared in 31% of cases (57). An extensive study with an overview of the literature on this theme from the period of 1982-1997 presents 85 patients with Brown's syndrome, of whom 38 congenital, in 15 cases of which the operation was performed with the aid of an expander without secondary pathology of the superior oblique muscle and without its expulsion (58). Five cases of consecutive paresis of the superior

oblique muscle in this period were connected with the remaining tenotomies, which were adjusted following retropositioning of the inferior oblique muscle on the same side. This surgical technique spread internationally due to the frequency of consecutive pareses of the superior oblique muscle following tenotomies and tenectomies. In the citation database (chosen PUBMED) up to the end of 2016 it is possible to find a dozen papers by other authors from diverse regions, e.g. South Korea (5), Saudi Arabia (2) or Turkey (20). Information was published in these publications also about expulsion of an expander, in one patient out of 9 operated on (5), and 2 patients out of 22 treated eyes, where inflammatory reactions were also described in 6 cases requiring treatment by topical corticoids and oral non-steroid antiphlogistics (20). Consecutive paresis of the superior oblique muscle was also recorded, in 2 (9.5%) out of 22 patients treated with an expander (20) or only once (1.4%) after 71 insertions of an expander (35). Sterile orbital cellulite was also observed in 3 patients out of a total number of 71 operated on, in which corticosteroids always represented successful therapy (35). A connection with scarring following an inflammatory reaction in the upper nasal quadrant of the orbit was also stated by the largest study, monitoring the results of an expander in four operated patients (3%) (59) out of a total number of 140 procedures, performed by 39 members of the AAPOS (American Association of Pediatric Ophthalmology and Strabismus). Expulsion of expanders itself was also minimal, since it was recorded only five times, which represents 3.5% (59). The only of the published publications on this theme in the citation database from our region is an article by authors from Bratislava, who processed an observation of 6 children up to the age of 6 years operated on for Brown's syndrome and an analysis of a nine year old girl with primary hypotropia 10 pdpt. A highly positive effect was achieved in this girl after the insertion of a silicone expander (cerclage strip no. 240) 4 x 8 mm (13). In a further study ten years later the authors included eight new patients (11). They also included solution of the cosmetic impact on the state of position for indication of torticollis and vertical deviation. After another two years a study from Brno and our first study were published (25, 51). In the period from 2008 to 2016 the Brno authors presented four studies (1, 48, 49, 51) in total, always on the same number of 23 patients with Brown's syndrome, solved by means of an expander. The patients had hypotropia in primary position greater than 20 pdpt in accordance with observation abroad (2), in four cases as much as 35 pdpt. We did not observe such high hypotropia before surgery, neither is it stated by other authors (2, 13, 58). A pronounced improvement was manifested after surgery in all cases of our cohort, and after one week hypotropia was reduced to 6 to 18 pdpt, which was reduced further during the course of further observation and was never greater than 8 pdpt, in accordance with observation abroad (2). We also recorded this experience with progressive reduction of vertical deviation in primary position, as well as Slovak authors (11). Within the context of the surgical solution of paralytic strabismus during the period of 1996 to 2014 (21), operations on Brown's syndrome represented 10%. This stated number was supplemented up to the end of 2016 by four further children of pre-school age (22). We did not encounter expulsion of an

implant of our own construction in our set of 33 observations over a period from 20 years to a few months, and the Bratislava authors do not state expulsion of a cerclage strip as an expander with an observation period from 7 months to 11 years (11). In long-term observation during the period of 1995-2015 the Brno authors also did not observe expulsion of an implant (1), in which the shortest observation was 12 years. They also did not confirm perioperative complications with a silicone expander, and in a number of cases the postoperative position culminated in hyperphoria (51). None of the authors in our region has yet stated consecutive paresis of the superior oblique muscle following the application of an expander (1, 11, 13, 22, 24, 50). The isolated observations of consecutive semiptosis we recorded were probably caused by a swelling of the area of the levator of the upper eyelid and the superior rectus muscle within the framework of the difficult search and preparation of the superior oblique muscle.

We performed our own three-level evaluation as against the classic scoring of 1-10 (58). The reason was simplification: to a condition of fully compliant, satisfactory and unsatisfactory, which was analogous with the evaluation of the Brno authors (1, 48, 49, 51) and is a reflection of the three-level proposal for indication of the Slovak authors (12).

Following the successful insertion of the expander constructed by professor Wright (58, 59), further materials were discovered for extending the tendon of the superior oblique muscle, partially from synthetic materials but also from human tissues. Non-absorbable polyester was the most frequently applied, in which the results of its use were positively evaluated: 10 mm loop (14) or a 5-8 mm strip fixed as an adjustable suture (61). Our own construction related to two materials simultaneously: the core material was non-absorbable Ethibond, which fixed both ends of the disconnected tendon of the superior oblique muscle in the relevant distance, the covering material was a flexible silicone cannula. Various types of fascias of the patient were used upon the extension of the tendon: Achilles tendon (4, 5), fascia lata (44) and palmar tendon (3).

In the diagnosis of Brown's syndrome it is important to conduct a passive duction test, which can be performed in small children only under general anaesthesia, and is therefore a component of the surgical procedure. The test is incapable of differentiating truncation of the tendon from its blocking in the area of the pulley. In the case of genuine paresis of the inferior oblique muscle, a passive duction test would be negative (theoretical consideration). Release of the loop of the fixed expander of our construction during the gradual disconnection of the tendon, since we do not use myostate, then attests to a loose pulley and extension of the tendon. The use of MR is considered for clarification of the individual ratios of this area, but so far there is no consensus of opinion. In the case of congenital Brown's syndrome a 20% smaller cross-section of the superior oblique muscle than in the unaffected eye is described. This therefore concerns hypoplasia of the muscle, which may be the reason for contraction (42). This situation is described in isolated cases also by other authors in the issue of a tendon with possible fibrosis, but they document predominantly hypertrophy of the pulley-tendon complex (7).

Determination of the cause of acute Brown's syndrome is

difficult due to the diverse possibilities of local and general etiology. In our patients it was also difficult to demonstrate a correlation. The correlation between acquired form of Brown's syndrome in adult patients and stroke was based on a time continuity of the issue and a negative finding in the MR of the orbits, since no other pathology, including diabetes, was confirmed. There was an entirely clear correlation between diplopia and pansinusitis in a thirteen year old girl, since following antibiotic treatment of the inflammation, motility of the eyeball was completely restored. Bilateral paresis of the superior oblique muscle was described in the case of pansinusitis (28). We conducted MR on the youngest patient in the cohort in order to exclude an oncological cause of the condition. There was a negative MR of the brain and orbits together with a positive passive duction test, in which a block of elevation could attest to inflammation in the area of the pulley. This was confirmed by the prompt response to an injection of Betamethasone into this region. Therapy by corticosteroids in the form of application of injection into the area of the pulley has been known for 40 years (17). At present, systemic administration tends to be preferred (30, 41). The grounds for this is that application in small children would have to be administered under general anaesthesia (30). Our patient was already under general anaesthesia for the diagnostic passive duction test, which enabled the safe administration of Betamethasone. In adults we believe that the overall burden on the organism is less than upon systemic administration of a corticosteroid unless the patient is simultaneously being treated e.g. for a systemic pathology of the conjunctival tissue. The effect of local application can be better assessed. The majority of patients consisted of an eight-member group included in our study in 2008 (25), since that time we have added only two adults and the youngest patient. At present we take a reserved approach toward the application of corticosteroid to the region of the pulley of the superior oblique muscle, since according to our experiences application must be performed at the latest within two weeks from the beginning of the symptoms, which is difficult to ensure. Furthermore, spontaneous regression of acute Brown's syndrome is known, according to the literary data from 11% to 75% (19). Regression has also been recorded in its congenital form without surgical intervention (39).

## CONCLUSION

The use of an expander of our own construction (non-absorbable Ethibond 5-0 covered with a silicone cannula) on the congenital form of Brown's syndrome took place without serious complications or its expulsion within the observation period. The success rate of the procedure was determined by the age of the patients at the time of implantation. In pre-school children, vertical motility improved at least to the 2nd degree of elevation defect. With advancing age, the possibility of aligning vertical motility decreased, mainly in adulthood. The effectiveness of the application of Betamethasone into the region of the pulley of the superior oblique muscle in acute form of Brown's syndrome was successful only up to 2 weeks from the initial manifestations of vertical diplopia.

## LITERATURA

1. **Autrata, R., Pramuková, K., Krejčíková, I., Masariková, A.:** Brownův syndrom – dlouhodobé výsledky chirurgické léčby. *Folia Strabolo Neuroophthalmol*, 17, 2016 (Suppl. I.): 20–22.
2. **Awad, A.H., Digout, L.G., Al-Turkmani, S., et al.:** Large-segment Superior Oblique Tendon Expander in the Management of Severe Congenital Brown Syndrome. *J AAPOS*, 7, 2003: 274–278.
3. **Batal, A.H., Batal, O.:** Palmaris Longus Tendon as an Autogenous Expander for Brown's Syndrome: a Novel Technique. *J AAPOS*, 14, 2010: 137–141.
4. **Brown, H.W.:** Superior Oblique Tendon Sheath Syndrome. *Strabismus Ophthalmic Symposium*, St. Louis, C.V. Mosby, 1950, p. 219.
5. **Cho, Y.A., Kim, S., Graef, M.H.:** Surgical Outcomes in Correction of Brown Syndrome. *Korean J. Ophthalmol.*, 20, 2006: 33–40.
6. **Coats, D.K., Paysse, E.A., Orengo-Nania, S.:** Acquired Pseudo-Brown's Syndrome Immediately Following Ahmed Valve Glaucoma Implant. *Ophthalm Surg Laser*, 30, 1999: 396–397.
7. **Cousin, M., Girard, N., Denis, D.:** MRI in Congenital Brown's Syndrome: Report of 16 Cases. *Fr J Ophthalmol*, 36, 2013: 202–209.
8. **Craford, J.S.:** Surgical Treatment of True Brown's Syndrome. *Am J Ophthalmol*, 81, 1976: 289–295.
9. **Divišová, G. a kol.:** *Strabismus*. 2. vydání. Avicenum, Praha, 1990, s.135 a 288.
10. **Ellis, F.J., Jeffery, A.R., Seidman, D.J., et al.:** Possible Association of Congenital Brown Syndrome with Congenital Cranial Dysinnervation Disorders. *J AAPOS*, 16, 2012: 558–564.
11. **Fišerová, O., Gromová, M., Gerinec, A.:** Brownov syndróm. *Folia strabologica et neuroophthalmologica*, 7, 2006, (Suppl. I.): 36–38.
12. **Gerinec, A.:** *Detská oftalmológia*, Osveťa, Martin, 2005, s. 183–184.
13. **Gerinec, A., Slivková, D.:** Chirurgia kongenitálneho Brownovo syndrómu. *Čs. Oftal.*, 53, 1997: 76–79.
14. **Gräf, M., Kloss, S., Kaufmann, H.:** Results of Surgery for Congenital Brown's Syndrome. *Klin Monbl Augenheilkd*, 222, 2005: 30–37.
15. **Greenberg, M.F., Pollard, Z.F.:** Treatment of Inferior Oblique Paresis with Superior Oblique Silicone Tendon Expander. *J AAPOS*, 9, 2005: 341–345.
16. **Hwang, J.U. Lim, H.T.:** Acquired Simulated Brown Syndrome Following Surgical Repair of Medial Orbital Wall Fracture. *Korean J Ophthalmol*, 19, 2005: 80–83.
17. **Hermann, J.S.:** Acquired Brown's Syndrome of Inflammatory Origin. Response to Locally Injected Steroid. *Arch Ophthalmol*, 96, 1978: 1228–1232.
18. **Iannaccone, A., McIntosh, N., Ciccarelli, M.L. et al.:** Familial Unilateral Brown syndrome. *Ophthalmic Genetics*, 23, 2002: 175–184.
19. **Kent, J.S., Makar, I.:** Hypertropia Following Spontaneous Resolution of Brown's Syndrome. *Case Rep Ophthalmol*, 3, 2012: 230–235.
20. **Keskinbora, K.H.:** Long-term Outcome of a Silicone Expander for Brown's Syndrome. *J Pediatr Ophthalmol Strab*, 44, 2007: 163–169.
21. **Krásný, J.:** *Strabismus sursoabductorius (v kontextu osmnáctiletého rozboru strabismu)*. *Čes a slov Oftal*, 71, 2015: 267–277.
22. **Krásný, J.:** Brownův syndrom – expander a Y-exotropia. *Folia Strabolo Neuroophthalmol*, 17, 2016, (Suppl. I.): 48–51.
23. **Krásný, J., Autrata, R.:** *Pedooftalmologie a strabismus*. In Kuchynka, P. a kol.: *Oční lékařství*, Praha, Grada, 2007, s. 724
24. **Krásný, J., Brunnerová, R.:** *Strabismus – konzervativní postupy a chirurgické metodiky*. In Rozsival, P. (ed.) *Trendy soudobé oftalmologie*, sv. 6., Grada, Praha, 2010, s. 56–98.
25. **Krásný, J., Brunnerová, R.:** Brownův syndrom – akutní a získaná forma. *Folia Strabolo Neuroophthalmol*, 9, 2008, Suppl. I., s. 37–39.
26. **Lacy, P.D., Rhatigan, M, Colreavy, M.P., et al.:** Acquired Brown's Syndrome Caused by Frontoethmoidal Mucocoele. *Austr N.Z. J Surg*, 70, 2002: 688–689.
27. **Lauer, S.A., Sauer, H., Pak, S.M.:** Brown's Syndrome Diagnosed Following Repair of an Orbital Roof Fracture. A Case Report. *J. Craniomaxillofac. Trauma*, 4, 1998: 20–22.
28. **Lyons, C.J., Lee, J.P.:** Bilateral Consecutive Superior Oblique Palsy Following Frontoethmoidal Sinusitis. *J Pediatr Ophthalmol Strabismus*, 27, 1990: 233–236.
29. **Moghadam, A.A., Sharifi, M., Heydari, S.:** The Result of Brown Syndrome Surgery with Superior Oblique Split Tendon Lengthening. *Strabismus*, 22, 2014: 7–12.
30. **Muralidhar, R., Gautum, K., Christopher, D., et al.:** Isolated Superior Oblique Myositis Causing Acquired Brown's Syndrome. *Indian J Ophthalmol*, 63, 2015: 340–341.
31. **Otradovec, J.:** *Klinická neurooftalmologie*. Praha, Grada, 2003, s. 314–315.
32. **Pandey, P.K., Chaudhuri, Z., Bhatia, A.:** Extraocular Muscle Cysticercosis Presenting as Brown Syndrome. *Am J Ophthalmol*, 131, 2001: 526–527.
33. **Pham, C., Utz, V., Marcotty, A., et al.:** Superior Oblique Tendon (Brown's) Syndrome as the Presenting Finding in Childhood Onset HLA-B27 Related Enthesitis and Juvenile Idiopathic Oligoarticular Arthritis. *Reumatismo*, 66, 2014: 240–244.
34. **Pollard, Z.F., Greenberg, M.:** Achieving Success with Silicone Expander for Overacting Superior Obliques. *Trans Am Ophthalmol Soc*, 97: 1999: 333–342.
35. **Pollard, Z.F., Greenberg, M.:** Results and Complications in 66 Cases Using a Silicone Tendon Expander on Overacting Superior Oblique with A-pattern Anisotropias. *Binocular Vis Strabismus*, 15, 2000: 113–120.
36. **Rosenbaum, A.L., Astle, W.F.:** Superior Oblique and Inferior Rectus Muscle Injury Following Frontal and Intranasal Sinus Surgery. *J Pediatr Ophthalmol Strabismus*, 22, 1985: 194–202.
37. **Roy, F.H.:** *Practical Management of Eye Problems*, Lea Febiger, Philadelphia, 1975, p. 162–163.
38. **Salam, A., Meligonis, G., Malhotra, R.:** Superior Oblique Myositis as an Early Feature of Orbital Wegener's Granulomatosis. *Orbit*, 27, 2008: 203–206.
39. **Scott, R., Lambert, M.D.:** Late Spontaneous Resolution of Congenital Brown syndrome. *J AAPOS*, 14, 2010: 373–375.
40. **Schultz, E.:** Spontaneous Consecutive Brown Syndrome Following Superior Oblique Palsy. *Strabismus*, 1, 1993: 11–16.
41. **Stidham, D.B. Sondhi, N., Plager, D., Helveston, E.:** Presumed Isolated Inflammation of the Superior Oblique Muscle in Idiopathic Orbital Myositis. *Ophthalmology*, 105, 1998: 2216–2219.
42. **Suh, S.Y., Le, A., Demer, J.L.:** Size of the Oblique Extraocular Muscles and Superior Oblique Muscle Contractibility in Brown Syndrome. *Invest. Ophthalmol Vis Sci*, 56, 2015: 6114–6140.
43. **Talebnejad, M.R., Lankaranian, D., Warran, K., et al.:** Osteochondroma of the Trochlea as a Acquired Brown Syndrome: a Case Report. *J AAPOS*, 11, 2007: 305–306.
44. **Talebnejad, MR., Eghtedari, Owji, N., Alavi, A.:** Superior Oblique Tendon Elongation with Fascia Lata. *J AAPOS*, 12, 2008: 507–509.

45. **Talebnejad, M.R., Mosallaei, M., Azarpira, N., et al.:** Superior Oblique Tendon Expansion with Achilles Tendon Allograft for Treating Brown Syndrome. *J AAPOS*, 15, 2011: 234–237.
46. **Thorne, J.E., Valpe, N.J., Liu, G.T.:** Magnetic Resonance Imaging of Acquired Brown Syndrome in a Patient with Psoriasis. *Am J Ophthalmol*, 127, 1999: 233–235.
47. **Tychen, L, Tse, D.T., Ossoinig, K., Anderson, R.L.:** Trochleitis with Superior Oblique Myositis. *Ophthalmology*, 91, 1984: 1075–1079.
48. **Varadyová, B., Autrata, R., Pellarová, H. et al.:** Brownův syndrom – výsledky chirurgické léčby. *Folia Strabolo Neuroophthalmol*, 13, 2012, (Suppl I.): 56–58.
49. **Varadyová, B., Autrata, R., Pellarová, H. et al.:** Brownův syndrom – dlouhodobé výsledky chirurgické léčby. *Folia Strabolo Neuroophthalmol*, 14, 2013, (Suppl I.): 71–73.
50. **Vodičková, K., Autrata, R.:** Chirurgická léčba komplikovaných případů strabismu. In Rozsival, P. (ed.) *Trendy soudobé oftalmologie*, sv. 6., Grada, Praha, 2010, s. 101–123.
51. **Vodičková, K., Autrata, R., Řehůřek, J.:** Brownův syndrom – dlouhodobé výsledky chirurgické léčby. *Folia Strabolo Neuroophthalmol*, 9, 2008 (Suppl I.): 56–58.
52. **von Noorden, G.K.:** Superior Oblique Tenectomy in Brown's Syndrome. *Ophthalmology*, 89, 1982: 303–309.
53. **von Noorden, G.K., Helveston, E.M.:** Strabismus–Rozhodovací postupy. *Folia Strabolo Neuroophthalmol*, 5, 2002, (Suppl. II.), 212 s.
54. **Walsh, T.J.:** *Neuro-Ophthalmology (Clinical Signs and Symptoms)* 3. ed., Lea and Febinger, Philadelphia, 1992, p. 145–146.
55. **Wilson, M.E., Eustis, H.S., Parks, M.M.:** Brown's Syndrome. *Surv Ophthalmol*, 34, 1989: 153–172.
56. **Wright, K.W.:** Superior Oblique Silicone Expander for Brown's Syndrome and Superior Oblique Overaction. *J Pediatr Ophthalmol Strabismus*, 28, 1991: 101–107.
57. **Wright, K.W., Min, B.M., Park, C.:** Comparison of Superior Oblique Tendon Expander to Superior Oblique Tenotomy for the Management of Superior Oblique Overaction and Brown Syndrome. *Pediatr Ophthalmol Strabismus*, 29, 1992: 92–97.
58. **Wright, K.W.:** Brown's Syndrome: Diagnosis and Management. *Trans. Am Ophthalmol Soc*, 97, 1999: 1023–1109.
59. **Wright, K.W.:** Results of the Superior Oblique Tendon Elongation Procedures for Severe Brown's Syndrome. *Trans Am Ophthalmol, Soc.* 98, 2000: 48–50.
60. **Wright, K.W.:** *Alphabet Patterns and Oblique Muscle Dysfunction*. In Wright, W. & Spiegel, P. M.: *Pediatric Ophthalmology and Strabismus*, New York, Springer, 2003, p. 202–248.
61. **Yazdian, Z., Kamali-Alamdari, M., Ali Yazdian, M., Rajabi, M.T.:** Superior Oblique Tendon Spacer with Application of Nonabsorbable Adjustable Suture for Treatment of Brown Syndrome. *J AAPOS*, 12, 2008: 405–408.