

TATTOO-ASSOCIATED UVEITIS

SUMMARY

TATTOO-ASSOCIATED UVEITIS

The clinical case of tattoo-associated uveitis was first described by Lubeck and Epstein in 1952. Uveitis is accompanied by induration and hyperemia of tattoo skin, which can precede, follow or manifest simultaneously with uveitis. The diagnosis is determined on clinical grounds after exclusion of other causes. Uveitis is usually bilateral, chronic and vision impairment is variable. Tattoo-associated uveitis should be remembered in differential diagnosis due to the growing interest in tattoo.

Key words: uveitis, tattoo, masquerade syndrome
Čes. a slov. Oftal., 73, 2017, No. 1, p. 30–33

INTRODUCTION

Tattooing refers to the application of exogenous pigments into the dermis, with a permanent effect. The history of tattooing is very long, as documented for example by the mummy of the primeval man Ötzi, who was found on an Alpine glacier, and had tattoos probably for therapeutic reasons in the region of the joints of the upper and lower limbs. Tattooing was popular in the region of South East Asia, where it was used for religious and ritual reasons. With the advent of mercantile maritime transport, tattooing spread worldwide. In the Old Testament of the Bible there is also a mention of tattooing: "You shall not make any cuttings in your flesh for the dead, nor tattoo any marks on you" Leviticus 19:28. In wartime tattooing has been used for identification of persons. In recent decades artistic tattoos have become very popular, relating to 10-20% of the population in Western countries [6].

In rare cases tattooing involves health risks, and the quality of the inks used is important [11]. Inks for tattooing and permanent make-up may contain grains of soot, which are distributed inside the body as nanoparticles, as well as polycyclic aromatic hydrocarbons and salts of heavy metals, which are carcinogenic [5, 7]. Nevertheless, no correlation between tattooing and skin tumours has been demonstrated, though observation of pigmented birthmarks is more difficult [2]. The most common complication of tattooing is hypersensitivity to pigment [4].

Tattoo-associated uveitis is a rare clinical unit. Uveitis is frequently bilateral and chronic, and may be accompanied by complications usual in the case of chronic uveitis, which deteriorate visual acuity. Uveitis is mostly accompanied by induration and hyperemia of the skin in the area of tattooing. The diagnosis is determined on the basis of a clinical finding after the exclusion of other etiology, in the anamnesis it is appropriate to inquire about skin tattooing.

METHODOLOGY

Case report of 2 patients with tattoo-associated uveitis.

RESULTS

Patient no. 1

A 30 year old man was treated for chronic anterior uveitis in both eyes, which had persisted for 3 years. A relapse

of the pathology always occurred after discontinuation of local anti-inflammatory treatment. The following examination was indicated with the aim of clarifying the etiology of the uveitis: HLA B27, RTG of lungs, ORL examination, serology of herpes viruses and toxoplasmosis. The results were within the norm, only an above-limit value of angiotensin converting enzyme 69 U/l (referential limit 18-55 U/l) was identified. The patient was not being treated for anything other than allergy to cow's milk. At an initial examination at our clinic, vision in both eyes was 1.0. We recorded a mild cellular reaction in the anterior chamber and in the anterior vitreous body. In the right eye (RE) there was a present incipient posterior subcapsular cataract (fig. 1a). On the retina, especially in the lower half, there were a number of small, sharply demarcated lesions (fig. 1b). We determined a diagnosis of panuveitis in both eyes, with activity especially in the anterior segment.

At the next examination, negative lues serology was confirmed. The pulmonary examination was without signs of sarcoidosis, the pneumologist nevertheless indicated HRCT of the lungs, in which enlarged axillary nodes were identified as a secondary finding. The performed biopsy of the nodes identified mon-encapsulating granulomas around the grains of pigment (fig. 1c). With regard to the extensive tattoos that the patient had on his arms and torso (fig. 1d), a diagnosis of tattoo-associated uveitis was determined.

¹Klímová A., ¹Heissigerová J., ¹Říhová E.,
²Holan P., ¹Brichová M., ¹Svozílková P.

¹Department of Ophthalmology, 1st
Faculty of Medicine, Charles University
and General University Hospital in Prague,
Czech Republic

²Department of Pathology, Písek Hospital,
Písek, Czech Republic

The study was presented in the form of a
lecture at the 24th annual congress of the
Czech Ophthalmology Society.

*The authors of the study declare that no
conflict of interest exists in the compilation,
theme and subsequent publication of this
professional communication, and that it
is not supported by any pharmaceuticals
company.*



MUDr. Aneta Klímová, Ph.D.
Oční klinika, 1. LF UK a VFN v Praze
U Nemocnice 2
128 00, Praha 2
e-mail: aneta.klimova@vfn.cz

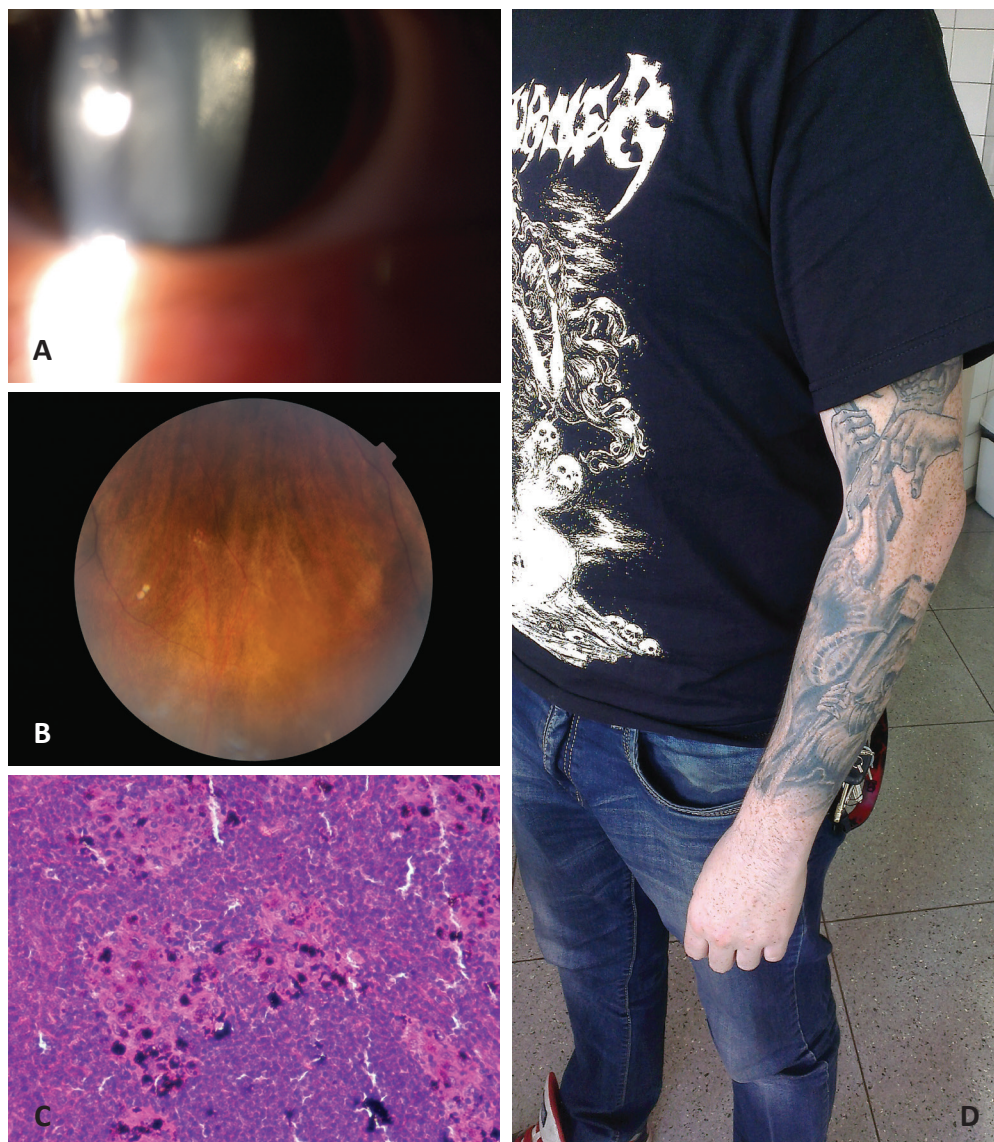


Fig. 1 - Patient no. 1

- 1a Posterior subcapsular cataract in right eye
- 1b Small white sharply demarcated lesions on retinal periphery on left eye, similar as in the case of sarcoidosis
- 1c Detail of axillary lymph node with preserved follicular architecture and dark pigment in the region of the sinuses, magnification 200x, hematoxylin-eosin stain (P. Holan)
- 1d Tattoo of left arm without induration or redness of skin

Chronic local therapy with corticoids in minimal strength and frequency was recommended for the patient, with regular checks of intraocular pressure. Despite the fact that the cause of the patient's ocular complaints was explained to him, he nevertheless planned to complete a tattoo on his back. This patient did not state induration of the skin in the place of the tattoo.

Patient no. 2

A 34 year old man was treated two months ago for a primary attack of anterior uveitis in the RE. After the discontinuation of local therapy there was a relapse of the pathology. At the same time, 2 months ago he observed a swelling of the skin in the place of a tattoo on his left arm (fig. 2a). The patient was in general good health and did not take any medication. At the initial examination at our centre, vision in the RE was 1.0 and in the left eye (LE) 0.8. The LE was amblyopic. At the examination we recorded a cellular reaction in the anterior chamber of the RE (fig. 2b), in the LE the inflammatory reaction was milder (fig. 2c). The vitreous body was bilaterally translucent, on the retina we identified

isolated small whitish rounded lesions of depigmentation, similar as in the case of sarcoidosis (fig. 2d). Testing for HLA B27 was negative, RTG of the lungs within the norm, infectious cause was not demonstrated. We commenced application of local anti-inflammatory treatment to the patient, which continued throughout the entire observation period (8 months) due to constant mild anterior uveitis. Despite repeated explanations, the patient would not accept any connection between his ocular complaints and tattoos.

DISCUSSION

Tattoo-associated uveitis was first described in 1952 by Lubeck and Epstein [8] in a 52 year old patient with a fever, productive cough, bilateral anterior uveitis and accompanying induration of the skin, limited to the area of tattooing. The patient had tattoos which were 20 years old, on both arms and on the torso. A biopsy of the indurated skin showed an image of chronic granulomatous inflammation with numerous epithelioid cells and large Langhans type cells. RTG of the lungs with a finding of hilar lymphadenopathy

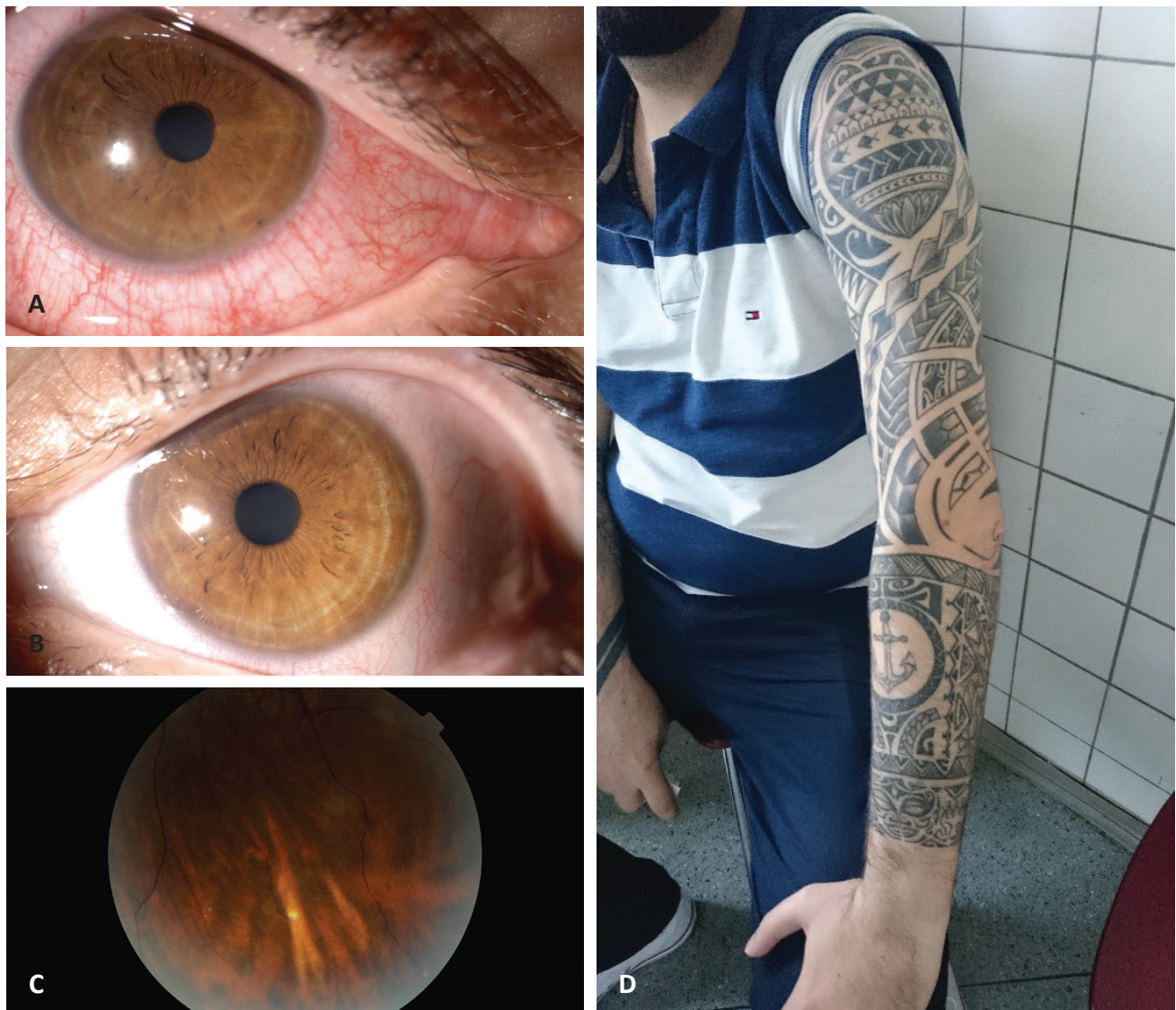

Fig. 2 – Patient no. 2

2a Tattoo of left arm without induration or redness of skin

2b Superficial and deep (ciliary) conjunctival injection following anterior uveitis in right eye

2c Milder anterior uveitis in left eye

2d Small white sharp demarcated lesion on retinal periphery on left eye, similar as in the case of sarcoidosis

led to a diagnosis of sarcoidosis. After the application of systemic corticotherapy the patient experienced a rapid improvement in his overall condition and a regression of uveitis. Our patients did not have symptoms of systemic pathology, and local long-term therapy by corticoids in drops was sufficient for them. Unlike the patient described by Lubeck and Epstein, our patients' age is lower.

Tattoo-associated uveitis is in most cases bilateral anterior uveitis, sometimes panuveitis. Anterior uveitis may be serous and/or fibrinous, there may be present vitritis, chorioidal lesions are described [12]. Uveitis may have some serious complications, in particular glaucoma, cystoid macular edema (CME), vasculitis or serous amotom. Due to complications of uveitis, an incipient cataract was present in one eye of one of our patients.

According to the individual case reports described in the literature, induration of skin in the place of tattoos most

frequently takes place simultaneously with uveitis. Reddening, swelling and pain in the place of tattoos may precede or follow the ocular finding. Skin complaints may be discrete, and if the tattoo is localised, for example on the back, the patient may not notice them. The surface area of the tattoo on the skin is generally larger. In the case of a biopsy of indurated skin, non-encapsulating granulomas have been described around the grains of pigment. The image of non-specific granulomatous inflammation in histology is similar to sarcoidosis, in the case of tattoos, however, it also concerns a reaction to foreign material. In some patients there was a presence of induration of axillary or submandibular nodes. As in the case of our patient, axillary nodes were enlarged, and their histology showed the presence of granulomas with pigment.

Ostheimer et al. [10] described 7 patients with tattoo-associated uveitis. All the patients were examined for lues,

and sarcoidosis was excluded, HLA B27 and serology of infections (*Mycobacterium tuberculosis*, *Toxoplasma gondii*, *Bartonella henselae* and *Borrelia burgdorferi*) were tested on some of the patients. One of the observed patients had panuveitis in both eyes, complicated by elevation of intraocular pressure and simultaneous swelling of the skin in the place of tattooing. Uveitis was in remission in the patient upon treatment with mycophenolate mofetil and prednisone. Intraocular pressure was compensated after surgery with drainage via antiglaucomatous implants in both eyes. The authors described chronic recurrent uveitis in all the observed patients. The ocular complaints were manifested at the earliest at 6 months, most frequently at around 1 year after the last tattooing. Induration of the skin appeared in all 7 patients, always in the place of tattooing. A skin biopsy was performed on two patients and demonstrated non-encapsulating granulomas in the surrounding area of the pigment, an identical histological image was shown by a biopsy of the enlarged axillary node. In 3 patients uveitis was complicated by the presence of CME, one patient had serous motility. After the commencement of treatment with prednisone a remission of ocular and skin complaints was observed in 5 of the 7 patients, the skin complaints subsided within 1 week [10]. Our observation period is short, in both patients there is dominant chronic anterior uveitis, maintained in remission by local corticoids. It is necessary to observe the patients over the long term also with regard to monitoring the side effects of therapy.

A diagnosis of tattoo-associated uveitis is determined on the basis of clinical symptoms. It is appropriate to perform an examination in order to exclude other etiologies of uveitis (samples of HLA B27, serology of borrelia and lues, CRP, FW, TBC Mantoux and QuantiFERON, RTG of lungs). It is possible to perform a biopsy of the affected skin with the tattoo.

In differential diagnostics it is important to exclude sarcoidosis, which may be manifested simultaneously with tattoo-associated uveitis [8, 9, 12]. Sarcoidosis is characterised by the appearance of non-encapsulating granulomas, but has no specific histopathological image. A finding of lymphadenopathy or deposit changes in the lungs, and raised serum levels of ACE support this diagnosis. Affliction of the eyes or ocular adnexa is present in 25-60 % of patients

with sarcoidosis and approximately 25-30 % have affliction of the skin. Anterior uveitis is the most common ocular manifestation of sarcoidosis [1, 3, 13]. In our patients we did not confirm a diagnosis of sarcoidosis, the pulmonary examination was negative.

Treatment of tattoo-associated uveitis is similar as in the case of other non-infectious forms of uveitis. In the first line, local corticoids with progressive application are suitable, due to the chronic nature of the pathology it is possible to apply weaker preparations over the long term in low doses. Systemic corticoids are essential if local therapy is not sufficiently effective. If the scope of affliction of the skin is not large, a variant of treatment is excision of the indurated skin, though despite this the result may not be satisfactory [10]. Of our patients transitional induration of the skin was present in one patient, excision of the skin was not indicated.

An interesting finding is that tattoo-associated uveitis has a higher incidence in men than in women, similarly as with sarcoidosis. A question remains as to whether this is a consequence of more frequent tattooing in the male population (Ostheimer [10] states 5 men versus 2 women).

CONCLUSION

Tattoo-associated uveitis is a rare clinical unit, though we may expect it to increase together with the popularity of artistic tattooing. In the clinical picture there is most frequently bilateral anterior uveitis of varying intensity, which is often accompanied with induration of the skin, limited to the place of the tattoos. The diagnosis is determined on the basis of the clinical finding after the exclusion of other etiology of uveitis. Granulomatous reaction to the pigment in the ink may be manifested in induration of the tattooed skin, as well as in enlargement of the lymph drainage nodes and also in the eye in the form of uveitis.

It is important to be aware of the risk of threat to vision as a consequence of artistic tattooing. Quality control of the used inks is appropriate from the perspective of preventing health complications in connection with tattooing.

We would like to thank Dr. Solano Gómez for her co-operation.

LITERATURE

1. Bonfioli A.A., Orefice F.: Sarcoidosis. *Semin Ophthalmol*, 20(3); 2005: 177–182.
2. Caccavale S., Moscarella E., De Fata Salvatore G. et al.: When a melanoma is uncovered by a tattoo. *Int J Dermatol*, 55(1); 2016: 79–80.
3. Iannuzzi M.C., Rybicki B.A., Teirstein A.S.: Sarcoidosis. *N Engl J Med*, 357(21); 2007: 2153–2165.
4. Islam P.S., Chang C., Selmi C. et al.: Medical Complications of Tattoos: A Comprehensive Review. *Clin Rev Allergy Immunol*, 50(2); 2016: 273–286.
5. Kluger N., Koljonen V.: Tattoos, inks, and cancer. *Lancet Oncol*, 13(4); 2012: e161–e168.
6. Kluger N.: Epidemiology of tattoos in industrialized countries. *Curr Probl Dermatol*, 48; 2015: 6–20.
7. Kluger N.: Cutaneous and systemic complications associated with tattooing. *Presse Med*, 45(6 Pt 1); 2016: 567–576.
8. Lubeck G., Epstein E.: Complications of tattooing. *Calif Med*, 76(2); 1952:83–85.
9. Miguel-Gómez L., Vañó-Galván S., Sidor-Ahmed B. et al.: Sarcoidal infiltrations of tattoos. *Cleve Clin J Med*, 81(12); 2014: 717–718.
10. Ostheimer T.A., Burkholder B.M., Leung T.G. et al.: Tattoo-associated uveitis. *Am J Ophthalmol*, 158(3); 2014: 637–643.
11. Pandya V.B., Hooper C.Y., Essex R.W. et al.: Tattoo-associated uveitis. *Am J Ophthalmol*, 158(6); 2014: 1355–1356.
12. Pandya V.B., Hooper C.Y., Merani R., McCluskey P. et al.: Tattoo-associated uveitis with choroidal granuloma: a rare presentation of systemic sarcoidosis. *Retin Cases Brief Rep*, 2016 [Epub ahead of print].
13. Svožílková P. a kol. (Eds): Diagnostika a léčba očních zánětů. Druhé vydání. Praha: Maxdorf Jessenius 2014, 2016. ISBN 970-807345-516-3.