

# PHARMACOLOGICAL TESTS FOR HORNER SYNDROME

## CASE REPORT

### SUMMARY

### PHARMACOLOGICAL TESTS FOR HORNER SYNDROME – CASE REPORT

The case report presents a patient, who was examined at our department due to anisocoria that was present for more than one year. Besides the anisocoria the patient had no other pathological symptoms. The pupil on the right eye was larger than on the left eye by more than 1mm. Photoreaction was present on both eyes with a dilatation deficit on the left eye. There was also a slight ptosis on the left. The anterior and posterior eye segment was normal, only the iris of the left eye was slightly decoloured. The ophthalmological finding was pointing to Horner syndrome on the left side. The cause of the syndrome was not found. The case report discusses current problems of pharmacological pupillary tests used in Horner syndrome. Alternatives to the standard cocaine test are proposed, with respect to substances currently available in the Czech Republic.

**Keywords:** anisocoria, Horner syndrome, cocaine test, phenylephrine

*Čes. a slov. Oftal., 72, 2016, No. 2, p. 39–43*

### INTRODUCTION

Horner syndrome encompasses symptoms of unilateral paralysis of the sympathetic nervous system. On the afflicted side the pupil is constricted due to the inactivity of the musculus dilatator pupillae, and there is present ptosis of the upper eyelid as a consequence of paresis of the Müller's muscle. By contrast the lower eyelid projects slightly because the innervated retractors of the lower eyelid are affected by the sympathetic nervous system. Enophthalmos is therefore only illusory, caused by a constriction of the ocular apertures on both sides, and from the classic triad of symptoms "ptosis, miosis, enophthalmos" today we describe only the first two (10, 11).

Horner syndrome occurs relatively rarely, and as a consequence it is important first of all to verify whether the symptoms are a genuine manifestation of this pathology. This is possible with the help of pharmacological pupillary tests, of which some are also capable of differentiating preganglionic or postganglionic affliction. Horner syndrome of the pupil can be reliably identified regardless of localisation of the lesion by means of a cocaine test: following instillation of 5% cocaine into both eyes, a healthy pupil dilates after 60 minutes, since the cocaine blocks the reabsorption of noradrenaline into the nerve endings and thus extends its effect on the muscle. In the case of Horner syndrome, however, the release of this neurotransmitter is reduced or entirely lacking, and as a result the cocaine block has no effect. The pupil does not dilate after the application of cocaine upon Horner syndrome.

Previously it was relatively easy to procure cocaine drops in order to demonstrate Horner syndrome, because cocaine

was used in ophthalmology as an anaesthetic. However, today it is difficult to obtain cocaine in practice, and its storage is subject to stringent regulations for handling intoxicating substances. Other substances such as hydroxyamphetamine, pholedrine or tyramine, which were used in the past for pharmacological tests, are not available in pharmacies. As a result other substances which are easily and quickly available have begun to be used in the diagnosis of Horner syndrome. These in particular include indirect sympathomimetic drugs acting as noradrenaline receptor agonists. Of these, apraclonidine produced as an anti-glaucomatous agent in the form of a HVLP preparation has become established abroad, but is not yet registered in the Czech Republic. Of the alternative raw materials in the Czech Republic it is possible to obtain only adrenaline or phenylephrine. Hydroxyamphetamine, pholedrine, tyramine and apraclonidine cannot be prescribed.

Phenylephrine is contained in the HVLP preparation Neo-Synephrine (10% phenylephrine solution), which the majority of ophthalmologists have in their surgery. 1% phenylephrine solution works on the principle of denervation of hypersensitivity of the musculus dilatator pupillae to its specific neurotransmitter or pharmacological agonists, which develops upon a postganglionic disorder of sympathetic innervation. After instillation of 1% phenylephrine solution, a Horner pupil should dilate, whilst a healthy pupil will not. In the following case study I would like to describe a case of the use of phenylephrine in the pharmacological demonstration of Horner syndrome and also the diagnostic perplexities that may accompany anisocoria caused by Horner syndrome.

Skorkovská K.

Department of ocular pathologies and optometry, Faculty of Medicine, Masaryk University, St. Anne's University Hospital, Brno, senior doctor MUDr. Lubomír Hanák

Presented at the 23rd congress of the Czech Ophthalmological Society in Hradec Králove in September 2015

*The authors of the study declare that no conflict of interest exists in the compilation, theme and subsequent publication of this professional communication, and that it is not supported by any pharmaceuticals company.*



MUDr. Karolína Skorkovská, Ph.D.  
Oddělení nemocí očních a optometrie  
Fakultní nemocnice u sv. Anny  
Pekařská 53, 656 91 Brno  
Email: karolina.skorkovska@fnusa.cz

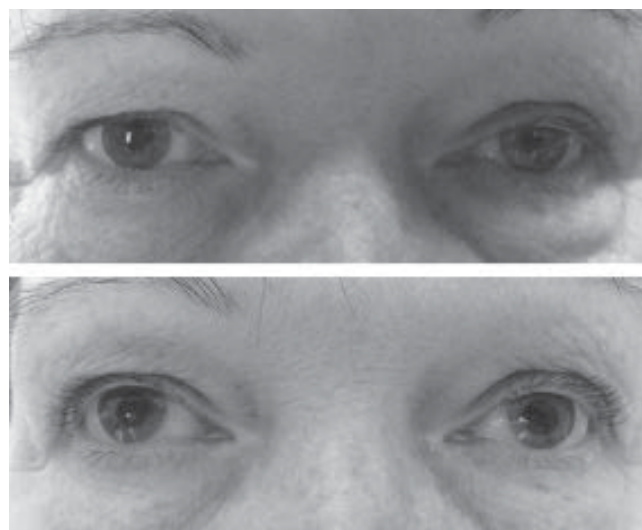
## CASE REPORT

In January 2015 a sixty year old female patient reported to our department for the purpose of examination of anisocoria, which was determined in the patient by chance one year previously upon a prescription for glasses with a sector ophthalmologist. The patient did not have any subjective complaints, generally she was being treated only for hypertension. The pupil in the right eye was wider than in the left eye. During the course of the last year the patient had undergone a range of examinations, which however did not lead to the determination of a diagnosis or of the cause of anisocoria. The wider pupil in the right eye had always been considered pathological.

After the determination of anisocoria, the patient was sent by her ophthalmologist first of all to a sector neurologist, where the objective finding determined distal sensorimotor polyneuropathy, and upon magnetic resonance (MR) of the head, non-specific supratentorial hyperintensities were described in the brain. Due to this finding the patient was sent to the centre for multiple sclerosis at our hospital, where this pathology was excluded, changes on MR were indicated rather as degenerative, and for an extension of the diagnosis of anisocoria the sampling of antibodies against borrelia and ultrasound of the main arteries was recommended. The finding on the carotid arteries was in order, but the finding of IgG antibodies against *Borrelia burgdorferi* was positive, and as a result the patient was sent to the infectious diseases clinic. There the level of antibodies against borrelia was indicated as "regular", but with regard to anisocoria lumbar puncture was recommended, which enabled a determination of the level of antibodies directly in the coeliolymph. However, the patient was afraid of lumbar puncture, and so was again sent by her ophthalmologist to us for a consultation.

Upon an examination at our centre the pupil in the right eye was wider, the difference in the diameter of the pupils of the right and left eyes was more than 1 mm. Direct photoreaction was present in both eyes, in the left eye there was an evident dilation deficit. The upper eyelid of the left eye was slightly drooping and to a targeted question the patient responded that on the basis of photographs she had also noticed the droop of the upper eyelid. Oculomotor function was within the norm, the patient did not state diplopia. Visual acuity in both eyes was 1.0 naturally, intraocular pressure within the norm and visual field intact. The finding on the anterior and posterior segment was without pathology in both eyes, only discrete heterochromia was evident, the iris in the left eye was paler.

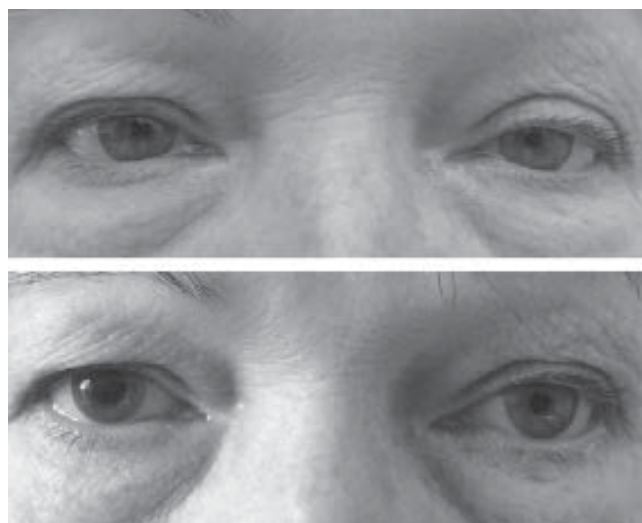
The ocular finding indicated Horner syndrome in the left eye. In an ideal case a cocaine test would be performed in order to demonstrate this syndrome. However, when I began to seek cocaine actively at our institutional pharmacy I determined that I would have to order cocaine specially, that drops cost CZK 1 500, and that the prescription of cocaine was considerably complicated. I therefore began to seek an alternative. Apraclonidine used in Western Europe is not registered in the Czech Republic, and the exceptional import of a single package of these drops would be unrealistic. I therefore decided to try 1% phenylephrine solution, which I had prepared in the pharmacy by the dilution of 10% phenylephrine (Neo-Synephrine-POS). I measured the diameter of the pupils of the right and left eyes under iden-



**Fig. 1** The diameter of the pupil of the right eye was 5 mm before the application of 1% phenylephrine, in the left eye 3 mm (above). One hour after application of 1% phenylephrine the diameter of the pupil of the right eye was unchanged, in the left eye the pupil dilated and the drooping of the upper eyelid in the left eye also improved (below). The result of the test indicated a postganglionic lesion of the sympathetic nervous system in the left eye

tical lighting conditions before application and one hour after the application of one drop of 1% phenylephrine solution to the conjunctival sac of both eyes. Before application the diameter of the pupil of the right eye was 5 mm, in the left eye 3 mm. One hour after the application of 1% phenylephrine the diameter of the pupil in the right eye was 5 mm, the left eye 5 mm, and in addition the droop of the upper eyelid of the left eye also improved (fig. 1). The result of the test indicated a postganglionic lesion of the sympathetic nervous system in the left eye.

In order to confirm the effect of 1% phenylephrine I also decided to perform a cocaine test for study reasons. Fo-



**Fig. 2** Before the application of cocaine the pupil in the right eye had a width of 3 mm, in the left eye 2 mm (above). One hour after application of cocaine the right pupil dilated to 5 mm, the diameter of the left pupil was unchanged (below). A cocaine test confirmed that this was a case of Horner syndrome

Following complex arrangements, I was exceptionally permitted to collect a special prescription for opiates, since we do not have any such prescriptions at our eye department. At the pharmacy I then ordered the preparation of 5% cocaine drops. We performed a cocaine test on the patient at an interval of one month from the previous test. Again I measured the width of the pupils of both eyes, applied one drop of 5% cocaine to the conjunctival sac of each eye and measured the diameter of the pupils again one hour later under the same lighting conditions. Before the application of cocaine the pupil in the right eye had a diameter of 3 mm, in the left eye 2 mm. One hour after application of cocaine the right pupil had dilated to 5 mm, the diameter of the left pupil was unchanged (fig. 2). The cocaine test unequivocally confirmed that this was a case of Horner syndrome.

Postganglionic form of Horner syndrome was therefore diagnosed in the patient. In order to supplement the diagnosis an X-ray of the lungs was performed, which did not demonstrate any pathological changes in the lungs or in the region of the upper thoracic cavity, and an examination of the thyroid gland, which was also within the norm. Because Horner syndrome had been present for more than one year, which was also indicated by mild heterochromia of the iris, and the previous examinations had not determined any pathology and the patient was without any other complaints or symptoms, I decided only to monitor the condition. At the same time there was no reason for the performance of the considered lumbar puncture at the infectious diseases clinic.

## DISCUSSION

The most conspicuous symptoms of Horner syndrome are miosis and ptosis with constriction of the ocular aperture. Photoreaction is well functional in the case of Horner syndrome, because the parasympathetic nervous system and therefore the function of the musculus sphincter pupillae is intact. However, there is a present dilation deficit, which can be registered upon an examination of pupil reactions in the dark

with the help of an infrared camera, or by observation of the pupil upon the use of a second, weaker light source, by which we illuminate the pupil from below. Anisocoria is fluctuating in the case of Horner syndrome, always larger in twilight or in emotional states, because the healthy pupil dilates more (11).

If the lesion is located before the bifurcation of the carotid artery, thus before the interval of sympathetic fibres for sweat secretion and temperature regulation in the face, manifestations of Horner syndrome may be accompanied by anhidrosis and reddening of half of the face on the afflicted side. In the case of congenital and perinatally acquired paralyzes of the sympathetic nervous system, heterochromia of the iris occurs. The afflicted iris retains the grey-blue colour of the newborn's iris, because the development of the pigmentation of the iris requires intact sympathetic innervation. In adults with long-term Horner syndrome there is also a loss of iris pigment after a period of years (11).

The path of the sympathetic nervous system leads from the hypothalamus to the second thoracic vertebrae, in the wall of the carotid artery back upwards via the sinus cavernosus, and further together with the nervus abducens and nervus ophthalmicus via the orbit to the musculus dilator pupillae and Müller's muscle of the upper eyelid. Within its course an interconnection takes place in two places – in the centrum ciliospinale and in the ganglion cervicale superius. The cause of Horner syndrome may be located in the region of the central neuron (from the hypothalamus to the centrum ciliospinale), preganglionic – first peripheral neuron of the sympathetic nervous system (between the centrum ciliospinale and the ganglion cervicale superius) or postganglionic – second peripheral neuron of the sympathetic nervous system (between the ganglion cervicale superius and the iris).

There are several possible causes of the syndrome, and these include absolutely benign afflictions and very serious processes such as dissection of the carotid artery or tumours. However, their determination is frequently difficult. Anamnesis or accompanying symptoms may help (table 1). Nevertheless, in up to one third of patient, it is not possible to

**Table 1** Causes of Horner syndrome and relevant accompanying symptoms and findings

Brain stem lesion	Nystagmus, dysmetria of saccades, disorder of sensations, hemiataxia
Syringomyelia	Disorder of perception of pain and temperature, muscle atrophy
Disc prolapse	Paresis, disorder of sensations
Thoracic outlet syndrome	Disorder of sensations, paralysis of lower limbs
Mediastinal tumour	Cough, congestion
Damage to plexus brachialis	Paresis, previous trauma
Neuroblastoma	Palpation finding
Goitre	Changes of thyroid gland hormones, palpation finding
Hodgkin's lymphoma	Palpation finding
Lateral neck cyst	Palpation finding
Dissection of carotid artery	Pain, transitory disorders of vision and paralysis
Carcinoma of paranasal cavities (PNC)	Symptoms of PNC pathology
Tumour sinus cavernosus	Paresis of n. VI, disorders of sensation in region of 1. branch of n. V
Cluster headache	Intense pain in half of head

determine the cause even despite adequate diagnosis using display methods. In such a case it is appropriate to examine how long Horner syndrome has been present in the patient, for example with the use of older photographs. In general, if Horner syndrome has persisted for longer than one year, a dangerous cause is highly improbable. If it has been present for a shorter time, it is appropriate to perform imaging of the entire course of the sympathetic pathway (11).

A general quality of the sympathetic and parasympathetic nervous system is denervation supersensitivity. According to this the organ which loses its normal innervation becomes more sensitive to the chemical transmitter released from the relevant nerve endings. Upon a reduction or lack of impulses from the sympathetic nervous system there is an "up-regulation" of the  $\alpha_1$  receptors of the musculus dilatator pupillae and therefore its greater sensitivity to noradrenaline or its agonists – sympathomimetic drugs (6).

It is precisely on the basis of denervation supersensitivity that in the postganglionic form of Horner system a dilation of the pupil takes place even after the application of a diluted phenylephrine solution to the conjunctival sac. In a healthy individual or patient with central or preganglionic form of Horner syndrome, the pupil does not dilate. In our patient the pupil in the left eye dilated by 2 mm, in the right eye it was unchanged, so this therefore concerns postganglionic affliction of sympathetic innervation in the left eye. At the same time ptosis of the upper eyelid improved, which we may also interpret as a consequence of the adrenergic effect of phenylephrine.

A comparison of 1% phenylephrine with 1% hydroxamphetamine in demonstrating a postganglionic lesion of the sympathetic nervous system in the case of Horner syndrome was conducted in a study by professor Danesh-Meyer. In 14 patients with Horner syndrome phenylephrine caused dilation of the pupil in the postganglionic form on average by 1.9 mm, in the case of a lesion of the central or preganglionic neurone the change in the width of the pupil was only 0.25 mm and 0.5 mm respectively. The width of a healthy pupil in all cases changed by an average of only 0.2 mm. Sensitivity of phenylephrine reached 81% in this study, specificity 100%. For comparison, sensitivity of 1% hydroxyamphetamine in this study was 93% and specificity 83%. 1% phenylephrine therefore represents a reliable substitute for previously used hydroxyamphetamine, which is not available in pharmacies (3).

In our conditions an alternative to phenylephrine may be another sympathomimetic preparation, namely adrenaline. This in a 1% solution does not affect the width of the pupil in a healthy eye, but thanks to denervation supersensitivity, similarly to phenylephrine it dilates a pupil with a postganglionic lesion of the cervical sympathetic nervous system. A limitation is only its somewhat inferior transmittance through the cornea. Adrenaline 1‰ is a mandatory component of all resuscitation packages and should therefore be available immediately. The price of one ampulla is only CZK 24.00.

The sympathomimetic drug apraclonidine 0.5%, which is available in Western Europe as the anti-glaucomatous agent lopidine® from the Alcon company, also works on the principle of denervation supersensitivity. Whereas in the case

of a healthy pupil there is no – or only minimal – dilation, a Horner pupil dilates markedly, and ptosis also improves. In addition to its easy availability, another advantage of a test with apraclonidine consists in the fact that the change in the width of the pupil can be read after only 15 minutes (1, 6). In countries where apraclonidine is registered, this preparation is the best and simplest alternative to cocaine in the pharmacological demonstration of Horner syndrome.

An objection to the use of apraclonidine, phenylephrine or another  $\alpha_1$ -sympathomimetic drug may be that the aforementioned supersensitivity of adrenergic receptors of the sympathetic nervous system develops slowly. Although it can be demonstrated after only a few days, it is not fully developed until after 1-2 weeks (8). Therefore the result of the pharmacological test in the early form of Horner syndrome may produce a false negative (4, 7). For example Falzon et al. described cases of two patients with postganglionic form of Horner syndrome, in whom it was not possible to demonstrate denervation supersensitivity using 1% phenylephrine after three days of duration of the complaints, but not until ten days after the development of the symptoms (5). On the other hand there are studies which by contrast demonstrate that denervation supersensitivity develops very rapidly, even within a few hours (1). A solution could be provided only by a study with a large number of patients, which however is difficult in the case of Horner syndrome. Nevertheless, if it concerns a young person with an anamnesis of trauma, headaches and suspicion of Horner syndrome, it is appropriate to perform magnetic resonance of the head and neck as quickly as possible, even without pharmacological tests of the pupillary reactions, in order to eliminate serious dissection of the carotid artery, which is the most frequent cause of strokes in patients younger than 50 years.

In contrast with adults, in children it continues to apply that upon suspicion of Horner syndrome a cocaine test is indicated (in children aged under 1 year with 2.5% cocaine), because  $\alpha_1$ -sympathomimetic drugs may cause a drop in blood pressure in children. A correct diagnosis of Horner syndrome is important for children especially with regard to the danger of neuroblastoma (12).

## CONCLUSION

Despite all the difficulties I managed to confirm a diagnosis of Horner syndrome in our patient, and was able to reassure her that the finding of any serious cause was improbable after such a long time. I would like to use this case report mainly in order to draw attention to the fact that the cocaine test presented in textbooks as the classic test for demonstrating Horner syndrome is no longer performed today by the majority of ophthalmologists in Europe. The difficult availability of cocaine, its high price and problems with proscription are entirely limiting for regular ophthalmologists. The endeavour is therefore to use a more easily available substance for the diagnosis of Horner syndrome, such as phenylephrine, adrenaline or apraclonidine.

And how should a Czech ophthalmologist proceed today in the diagnosis of Horner syndrome in adult patients? I would recommend a proper examination of the pupillary reactions and



in the case of suspicion of Horner syndrome to perform a test with 1% phenylephrine solution or 1% adrenaline. If Horner syndrome is confirmed, in the Czech Republic patients are most often sent from the ophthalmological centre to a neurologist, who should attempt to detect the possible cause of Horner syndrome on the basis of the anamnesis and accompanying symptoms, and according to this indicate further examinations, most com-

monly magnetic resonance. In the case of Horner syndrome persisting for less than one week it is acutely necessary to perform a neurological examination (11). If drops for confirming Horner syndrome are not available, it is not appropriate in the case of patients with acute, painful or traumatic development of symptoms to wait for the result of the pharmacological papillary test, thus delaying the performance of display methods (2).

## LITERATURE

1. **Cooper-Knock, J., Pepper, I., Hodgson, T. et al.:** Early diagnosis of Horner syndrome using topical apraclonidine. *J Neuro-Ophthalmol*, 31, 2011: 214–216.
2. **Davagnanam, I., Fraser, CL., Miskiel, K. et al.:** Adult Horner's syndrome: a combined clinical, pharmacological, and imaging algorithm. *Eye*, 27, 2013: 291–298.
3. **Danesh-Meyer, HV., Savino, P., Sergott, R.:** The correlation of phenylephrine 1% with hydroxyamphetamine 1% in Horner's syndrome. *Br J Ophthalmol*, 88, 2004, 4: 592–593.
4. **Dewan, MA., Harrison, AR., Lee, MS.:** False-negative apraclonidine testing in acute Horner syndrome. *Can J Ophthalmol*, 44, 2009: 109–110.
5. **Falzon, K., Jungkim, S., Charalampidou, S. et al.:** Denervation supersensitivity to 1% phenylephrine in Horner syndrome can be demonstrated 10 days after the onset of symptoms. *Br J Ophthalmol*, 93, 2009: 130.
6. **Freedman, KA., Brown, SM.:** Topical apraclonidine in the diagnosis of suspected Horner syndrome, *J Neuroophthalmol*, 25, 2005: 83–5.
7. **Kawasaki, A., Borruat, FX.:** False negative apraclonidine test in two patients with Horner syndrome. *Klin Monatsbl Augenheilkd*, 225, 2008: 520–522.
8. **Miller, N.:** The autonomic nervous system. In Miller, NR., Newman, NJ. (Eds), *Walsh and Hoyt's clinical neuro-ophthalmology*. Philadelphia, Lippincott Williams&Wilkins, 2004, s. 660.
9. **Mughal, M., Longmuir, R.:** Current pharmacologic testing for Horner syndrome. *Current Neurology and Neuroscience Reports*, 9, 2009: 384–389.
10. **Otradovec, J.:** Zornice. In Otradovec, J. (Ed), *Klinická neurooftalmologie*. Praha, Grada Publishing, 2003, s. 142–154.
11. **Wilhelm, H., Wilhelm, B.:** Diagnostik von Pupillenstörungen. In Schiefer, U., Wilhelm, H., Zrenner, E., Burk, A. (Eds), *Praktische Neuroophthalmologie*. Heidelberg, Kaden Verlag, 2003, s. 53–66.
12. **Wilhelm, H., Tonagel, F., Heine, C.:** Was tun bei Horner-Syndrom? *Z prakt Augenheilkd*, 35, 2014, 3: 119.